

Figure S1. Potential sources to detection mistakes of focal renal lesions.

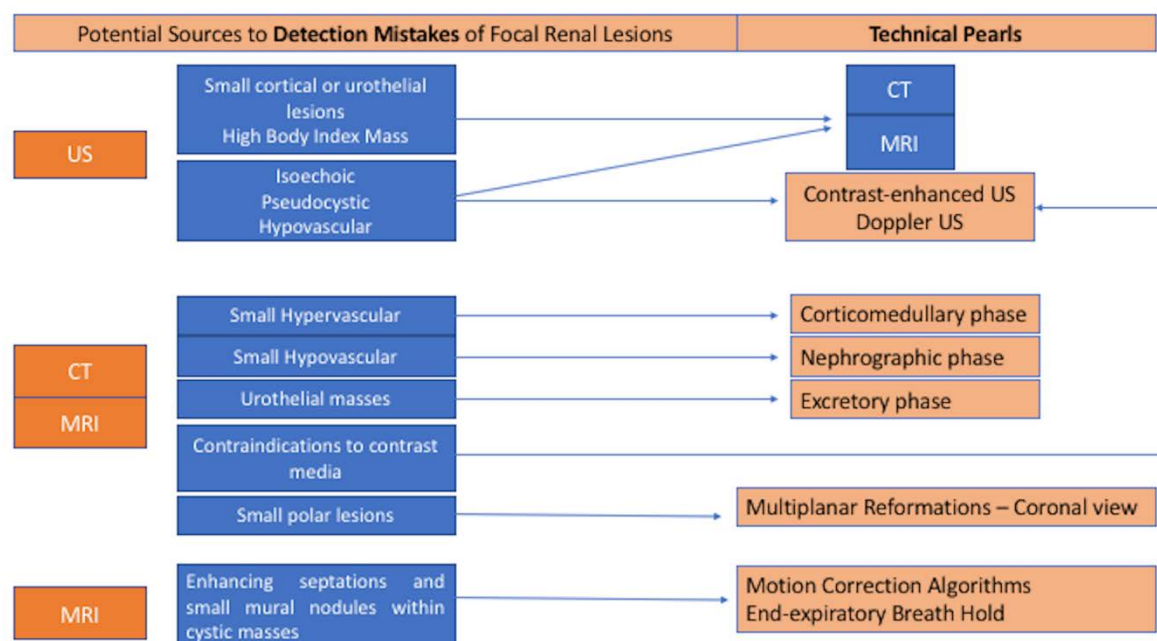


Figure S2. Potential sources to interpretation mistakes of focal renal lesions.

