

## Virtual-histology intravascular ultrasound: justifiable criticism or unfair slander?

“...few other coronary imaging modalities offer the same reliability in plaque characterization and depth of tissue penetration. Thus ... VH-IVUS will remain an important technique for describing coronary plaque morphology for some time to come.”

**Keywords:** atherosclerosis • intravascular ultrasound • virtual-histology

Cardiovascular diseases remain the leading cause of mortality throughout the world, with coronary atherosclerosis responsible for the majority of clinical events. Diagnostic imaging modalities that provide accurate characterization of atherosclerotic plaques to guide therapy and potentially alter clinical outcomes are therefore of considerable importance. One such imaging modality is virtual-histology intravascular ultrasound (VH-IVUS), an iteration of standard gray-scale IVUS technology that uses an automated algorithm to process the reflected ultrasound backscatter signal, allowing identification of plaque components such as fibrous tissue, fibrofatty tissue, necrotic lipid core and dense calcium [1]. VH-IVUS has been used successfully in a number of clinical studies to describe the pattern and behavior of coronary plaques. However, there remains ongoing debate over the accuracy of VH-IVUS plaque characterization, with many in the cardiovascular research community dismissive about its reported utility.

Concerns were first raised from two validation studies comparing the ability of VH-IVUS to identify necrotic core in porcine models of atherosclerosis: in the first study, coronary plaques were induced in five pigs through balloon angioplasty with subsequent injection of liposomes into the adventitial layer of the vessel wall [2]. VH-IVUS was found to correctly identify the presence of necrotic core in only 38% of plaques, with no correlation found between the percentage of each tissue component as displayed by VH-IVUS and histology. The same investigators then examined whether necrotic

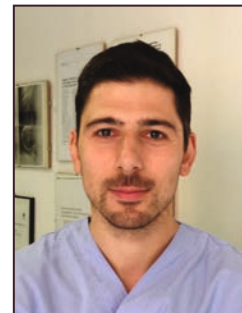
core size could be accurately visualized by VH-IVUS in ten minipigs that had accelerated atherosclerosis [3]. Plaques were again induced using an angioplasty balloon and VH-IVUS analysis performed at 18 weeks, with minipigs maintained on a proatherogenic diet. The correlation in necrotic core area between VH-IVUS and histology was poor ( $r = 0.33$ ;  $p = 0.18$ ) with many regions classified as necrotic core corresponding to areas of fibrotic tissue on histology. Although these studies are frequently used to question the accuracy of VH-IVUS, there are some important caveats that need to be understood. First, the automated algorithms used in VH-IVUS were developed exclusively in human *ex vivo* specimens and the reflected backscatter signal from porcine and human atherosclerotic tissue may differ. Validation studies performed in human specimens have demonstrated that the predictive accuracy of VH-IVUS is excellent (95.8% for necrotic core), which is in stark contrast to porcine data [1,4]. Second, the plaques generated and examined within porcine models were relatively immature (mean plaque burden  $41.3 \pm 8.0\%$  with no evidence of calcification) and, although extracellular lipid could be identified by histology, there was little in the way of an established necrotic core. Failure of VH-IVUS to identify these small extracellular lipid pools is likely of little clinical importance as plaques responsible for myocardial infarction typically contain a large, necrotic lipid-rich core [5]. Furthermore, the methodology used may have introduced longitudinal mismatches into the dataset, inducing potential for error [6]. Thus, while these stud-



**Adam J Brown\***

Division of Cardiovascular Medicine, University of Cambridge, Level 6, ACCI Building, Addenbrooke's Hospital, Cambridge, CB2 0QQ, UK, and, Department of Interventional Cardiology, Papworth Hospital NHS Foundation Trust, Cambridge CB23 3RE, UK

\*Author for correspondence:  
Tel.: +44 1223 331504  
Fax: +44 1223 331505  
ajdbrown@me.com



**Charis Costopoulos**

University of Cambridge



**Nick EJ West**

University of Cambridge

Future  
Medicine  part of 

ies may be conceptually interesting, they tell us little about the ability of VH-IVUS to characterize atherosclerotic plaque composition in humans.

The second issue relating to VH-IVUS relates to the manner in which heavily calcified lesions are portrayed. It is well described that large regions of calcified plaque are a barrier to IVUS assessment, with deeper plaque regions being virtually impossible to visualize due to acoustic shadowing. Thus, plaque composition 'behind' calcification is difficult to determine with certainty using VH-IVUS. Empirical observations have also suggested that VH-IVUS may display necrotic core artifact adjacent to large regions of dense calcium, with potential for errors in plaque characterization. However, published data that quantify the extent of these limitations in humans are few. The interaction between calcium and necrotic core was examined in one *in vivo* study, assessing the effect on necrotic core area when pseudocalcium was added to the plaque [7]. In this study, investigators used stent struts to simulate calcium inclusions and found that the addition of 'calcium-like' elements into the radiofrequency algorithm resulted in an increase in necrotic core area, although fibrous and fibrofatty tissue areas remained unchanged. The authors then identified pixels of necrotic core adjacent to dense calcium and found that these increased sixfold, while there was no change in pixels of nonadjacent necrotic core. Interestingly, their data found that the increase was almost linear ( $R^2 = 0.64$ ), suggesting it may be possible to correct for this issue through mathematical transformation. One simple method of adjustment that has been tested is calculation of the ratio of necrotic core to calcification (NC/DC ratio). This derived measure has been linked to established markers of cardiovascular risk, including low-density lipoprotein levels and smoking [8]. Further studies assessing the relationship between calcium and necrotic core are warranted and may yield valuable insights into the nuances of VH-IVUS interpretation.

The final criticism often directed toward VH-IVUS is that it is unable to clearly define 'vulnerable plaque,' the purpose for which it is often used [9–11]: its poor spatial resolution limits ability to accurately identify thin-cap fibroatheroma (TCFA), the precursor lesion for the majority of myocardial infarctions. Autopsy studies have shown that such 'vulnerable' plaques have thin fibrous caps ( $<65 \mu\text{m}$ ) [5], detection of which is

well below the axial resolution of VH-IVUS ( $\sim 150\text{--}200 \mu\text{m}$ ). Additionally, VH-IVUS is unable to identify plaque components that may act to induce plaque destabilization, including cholesterol crystals and neovascularization [12]. In an attempt to address these valid concerns, recent reports have detailed a new 45 MHz VH-IVUS algorithm that has predictive accuracies more than 86% for tissue characterization, with improved spatial resolution [13]. Although clinical data are yet to be obtained, this technology has better potential to visualize fibrous cap status and may enhance our ability to identify TCFA. Another possible method of improving the identification of rupture prone lesion may be through estimation of mechanical stress based on VH-IVUS data. This novel technique has been shown to improve the positive predictive value of VH-IVUS to identify plaques responsible for myocardial infarction, with stress values increased in VH-defined TCFA (VH-TCFA) and for plaques with large necrotic cores [14]. Regardless of these concerns regarding spatial resolution, there is no doubt that VH-IVUS can identify high-risk plaque subtypes. Prospective studies using VH-IVUS have consistently shown associations between baseline plaque characteristics (e.g., VH-TCFA) and future adverse cardiovascular events [9–11], confirming the biological importance of VH-defined plaque composition.

Understanding the strengths and weaknesses of VH-IVUS is crucial when interpreting the images generated and for translating the results of clinical studies. Despite concerns regarding its clinical utility, few other coronary imaging modalities offer the same reliability in plaque characterization and depth of tissue penetration. Thus, there remains little doubt that VH-IVUS will remain an important technique for describing coronary plaque morphology for some time to come.

#### Financial & competing interests disclosure

The authors have no relevant affiliations or financial involvement with any organization or entity with a financial interest in or financial conflict with the subject matter or materials discussed in the manuscript. This includes employment, consultancies, honoraria, stock ownership or options, expert testimony, grants or patents received or pending, or royalties.

No writing assistance was utilized in the production of this manuscript.

## References

- 1 Nair A, Margolis MP, Kuban BD, Vince DG. Automated coronary plaque characterisation with intravascular ultrasound backscatter: *ex vivo* validation. *EuroIntervention* 3(1), 113–120 (2007).
- 2 Granada JF, Wallace-Bradley D, Win HK *et al.* *In vivo* plaque characterization using intravascular ultrasound-virtual histology in a porcine model of complex coronary lesions. *Arterioscler. Thromb. Vasc. Biol.* 27(2), 387–393 (2007).
- 3 Thim T, Hagensen MK, Wallace-Bradley D *et al.* Unreliable assessment of necrotic core by virtual histology intravascular ultrasound in porcine coronary artery disease. *Circ. Cardiovasc. Imaging* 3(4), 384–391 (2010).
- 4 Obaid DR, Calvert PA, Gopalan D *et al.* Atherosclerotic plaque composition and classification identified by coronary computed tomography: assessment of computed tomography-generated plaque maps compared with virtual histology intravascular ultrasound and histology. *Circ. Cardiovasc. Imaging* 6(5), 655–664 (2013).
- 5 Virmani R, Kolodgie FD, Burke AP, Farb A, Schwartz SM. Lessons from sudden coronary death: a comprehensive morphological classification scheme for atherosclerotic lesions. *Arterioscler. Thromb. Vasc. Biol.* 20(5), 1262–1275 (2000).
- 6 Stone GW, Mintz GS. Letter by Stone and Mintz Regarding Article, “Unreliable assessment of necrotic core by virtual histology intravascular ultrasound in porcine coronary artery disease”. *Circ. Cardiovasc. Imaging* 3(5), e4 (2010).
- 7 Sales FJ, Falcao BA, Falcao JL *et al.* Evaluation of plaque composition by intravascular ultrasound “virtual histology”: the impact of dense calcium on the measurement of necrotic tissue. *EuroIntervention* 6(3), 394–399 (2010).
- 8 Missel E, Mintz GS, Carlier SG *et al.* *In vivo* virtual histology intravascular ultrasound correlates of risk factors for sudden coronary death in men: results from the prospective, multi-centre virtual histology intravascular ultrasound registry. *Eur. Heart J.* 29(17), 2141–2147 (2008).
- 9 Calvert PA, Obaid DR, O’sullivan M *et al.* Association between IVUS findings and adverse outcomes in patients with coronary artery disease: the VIVA (VH-IVUS in Vulnerable Atherosclerosis) Study. *JACC Cardiovasc. Imaging* 4(8), 894–901 (2011).
- 10 Stone GW, Maehara A, Lansky AJ *et al.* A prospective natural-history study of coronary atherosclerosis. *N. Engl. J. Med.* 364(3), 226–235 (2011).
- 11 Cheng JM, Garcia-Garcia HM, De Boer SPM *et al.* *In vivo* detection of high-risk coronary plaques by radiofrequency intravascular ultrasound and cardiovascular outcome: results of the ATHEROREMO-IVUS study. *Eur. Heart J.* 35(10), 639–647 (2014).
- 12 Brown AJ, Costopoulos C, West NE, Bennett MR. Contemporary invasive imaging modalities that identify and risk-stratify coronary plaques at risk of rupture. *Expert Rev. Cardiovasc. Ther.* 13(1), 9–13 (2015).
- 13 Campos CM, Fedewa RJ, Garcia-Garcia HM *et al.* *Ex vivo* validation of 45 MHz intravascular ultrasound backscatter tissue characterization. *Eur. Heart J. Cardiovasc. Imaging* 1, pii: jev039 (2015) (Epub ahead of print).
- 14 Teng Z, Brown AJ, Calvert PA *et al.* Coronary plaque structural stress is associated with plaque composition and subtype and higher in acute coronary syndrome: the BEACON I (Biomechanical Evaluation of Atheromatous Coronary Arteries) study. *Circ. Cardiovasc. Imaging* 7(3), 461–470 (2014).

