

# Treatment of atherosclerotic renal artery stenosis

Renal artery stenosis (RAS) is an important cause of secondary hypertension. Atherosclerosis remains the leading cause of RAS. RAS leads to reduced renal perfusion pressure and subsequent elevation of neurohormones that accelerate hypertension, congestive heart failure and ischemic nephropathy. Patients with RAS have a low incidence of progressive renal artery occlusion and deterioration of renal function requiring renal replacement therapy. However, patients with RAS have high mortality compared with other patients. This is caused by comorbidities of cerebrovascular disease and coronary artery disease, resulting in stroke and myocardial infarction. The mainstay of treatment for RAS involves maximal medical treatment of atherosclerosis. Renal artery revascularization in patients with significant RAS is recommended for those individuals with uncontrolled hypertension receiving multiple antihypertensives, and those with flash pulmonary edema, unexplained angina and progressive renal function deterioration. The results of renal artery stenosis revascularization continue to be debatable. The most promising results of renal artery revascularization are noted in hypertension control. Prospective randomized clinical trials, such as the Cardiovascular Outcomes of Renal Artery Atherosclerotic Lesions (CORAL) trial, will hopefully settle the debate of medical treatment versus renal artery stenting for patients with RAS.

**KEYWORDS:** congestive heart failure ■ ischemic nephropathy ■ renal artery stenosis ■ renovascular hypertension ■ stents

Aravinda Nanjundappa<sup>†</sup>,  
Robert S Dieter,  
Samuel Deem &  
Theodore Tan

<sup>†</sup>Author for correspondence:  
Associate Professor of  
Medicine & Surgery,  
West Virginia University,  
Charleston, WV 25304, USA  
dappamd@yahoo.com

Renal artery stenosis (RAS) is a cause of hypertension and is noted in 1–6% of hypertensive patients [1]. Atherosclerotic disease is the leading cause of RAS and incidental RAS during coronary angiography is seen in 36% of patients with coronary artery disease [2]. The comorbidities of atherosclerosis, such as hypertension, coronary artery disease, peripheral arterial disease and stroke are well documented in patients with RAS [3]. Fibromuscular dysplasia and vasculitis are the leading nonatherosclerotic causes of RAS [4]. Nonatherosclerotic diseases may account for 60% of RAS cases in India and the Far East [5]. Hansen *et al.* carried out a population-based study of RAS prevalence in patients older than 65 years. RAS was present in 6.8% of this cohort and demonstrated an association with age, elevated lipid levels and systolic blood pressure, and no difference in terms of ethnicity [6].

## Natural history

Despite the controversies, RAS is associated with increased cardiovascular morbidity and mortality. One study shows unsuspected RAS to be 24% in patients aged 45–75 years with renal insufficiency (serum creatinine  $\geq 2.00$  mg%) [7]. In patients over 50 years of

age with end-stage renal artery disease, RAS was found in 50% of patients [8]. The progression of RAS ranges from 17–63% and occlusion was seen in 8–16% of patients at 5 years [9]. Angiographic follow up of patients with RAS with coronary artery disease in 14,152 patients demonstrated significant progression in 11.1% [10]. RAS in 29 kidneys monitored for 33 months by Caps *et al.* show frequent progression, but occlusion occurred in only 3% [11]. The factors predicting progression were greater than 60% RAS, elevated systolic blood pressure and diabetes mellitus [11]. The wait and see approach for patients with RAS may lead to dialysis as demonstrated by Scoble in 1995 [12] and Fehr in 2003 [13].

In 3987 patients undergoing abdominal angiography in a study by Conlon *et al.*, the 4-year survival was 89% in those without RAS, but only 57% in individuals with RAS. There was a graded effect of RAS on survival, with those having stenosis greater than 75% having lower survival than those with greater than 50% RAS [14]. There is no clear correlation between glomerular filtration rate and the extent of RAS [15]. However, a high mortality is noted in this specific subset of atherosclerotic RAS (ARAS) and renal insufficiency.

future  
medicine <sup>part of</sup> fsg

### Pathophysiology of RAS in relation to hypertension & ischemic nephropathy

The risk factors of atherosclerosis in the vascular bed, such as tobacco use, hypertension, lipid abnormalities, hyperhomocysteinemia, cigarette smoking and diabetes mellitus, leads to endothelial injury [16]. The infiltration of lipid-laden macrophages at the site of endothelial injury further leads to plaque development and RAS.

Chade *et al.* from the Mayo clinic (USA) had demonstrated that hypercholesterolemia plays a distinct detrimental role on renal function and structure *in vivo* and *in vitro* in individuals with RAS [16]. Oxidative stress along with inflammatory and growth changes were seen at the tubular and glomerular level.

Goldblatt demonstrated in 1934 that renovascular hypertension is secondary to the activation of the renin–angiotensin–aldosterone pathway [17]. Renal artery occlusion leads to ischemia, which triggers the release of renin. Renin facilitates the conversion of angiotensin I to angiotensin II, which leads to vasoconstriction and the release of aldosterone. The volume changes and the renin–angiotensin system blockade depend on the presence of a functioning kidney (TABLE 1, FIGURE 1).

There are three successive stages in renovascular hypertension and renal ischemia which are described here [101]:

- RAS leads to increase in serum renin levels and blood pressure remains elevated for the first few weeks. If the contralateral kidney is functioning, intravascular volume remains unchanged and renin levels continue to be high. The stenotic kidney retains salt in response to elevated production of renin. The relatively normal kidney continues to excrete sodium and water and maintains normal volume levels;
- If the stenotic renal artery occludes, the solitary ischemic kidney retains salt and water, together with angiotensin II, via the vasoconstrictor effect, and maintains the renal perfusion pressure. The stimulus to maintain renin levels is lost and angiotensin does not play a role in sustaining hypertension. The continued volume expansion leads to elevation of hypertension and maintains the renal perfusion pressure;
- Theoretically, if RAS is diagnosed during these first two stages, restoring the flow by renal artery revascularization (RAR) can return the renal perfusion to baseline. Thus, elevated blood pressure should return to normal levels. In the final or third phase of renovascular hypertension, elevated blood pressure persists despite restoration of flow to the renal artery. This is secondary to irreversible vascular and renal parenchyma damage. This

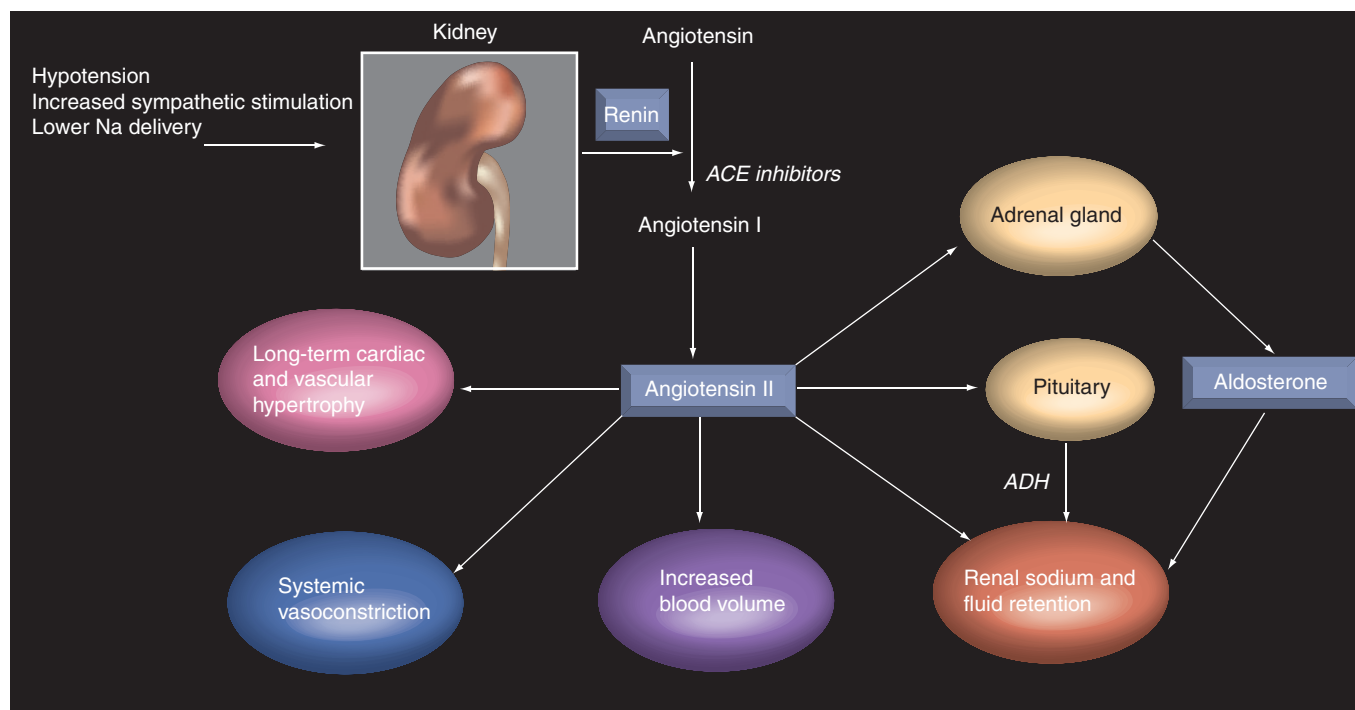


Figure 1. The renin–angiotensin–aldosterone pathway.

**Table 1. Renal artery stenosis pathophysiology for solitary and bilateral functioning kidney.**

	Bilateral stenosis	Unilateral stenosis
Intravascular volume	↑	↔
Renin aldosterone angiotensin system	Levels return to baseline	↑
Blood pressure	↑	↑
Renin–angiotensin system blockade	↔	↓

*Adapted from Cardiovascular Outcomes of Renal Artery Atherosclerotic Lesions (CORAL) teaching slides courtesy of Dr Tim Murphy.*

concept of irreversible damage was demonstrated by histology in both stenotic and non-stenotic kidneys [16]. The nonstenotic kidney is damaged by hypertensive nephrosclerosis, recurrent ischemia, oxidative stress, cytokines such as TNF and interstitial fibrosis.

Thus, the benefit of RAR is questioned, especially if renovascular hypertension is in the third stage. At present there is no simple predictor to diagnose the exact stage of renovascular hypertension to determine definite success following RAR.

### Diagnosis of RAS

The various tests to diagnose RAS in conjunction with history and physical examination are doppler ultrasound, captopril scan, magnetic resonance angiogram, CT scan and conventional angiography. The initial test should be Doppler ultrasound, which is a safe, cost-effective and noninvasive test compared with magnetic resonance angiogram [18]. When various modalities are compared, conventional renal artery angiography with digital subtraction angiography is considered to be the gold standard.

The imaging modalities for RAS in patients with suspected renovascular hypertension compared in a prospective comparison among Doppler ultrasound, CT angiography, magnetic resonance angiogram and digital subtraction angiography are depicted in TABLE 2. It is important to note that the sensitivity and specificity for conventional digital subtraction angiography are 100% each, respectively.

### Treatment of RAS

Atherosclerotic renal artery stenosis should be first treated with risk factor reduction similar to atherosclerotic lesions in other vascular beds [19,20]. The goal is to treat the patient as a vascular disease patient and prevent the comorbidities of myocardial infarction, stroke and peripheral arterial disease. RAS patients need thorough evaluation of co-existing cardiovascular diseases mentioned above. An extensive vascular evaluation should include review of systems to evaluate history of stroke, claudication and angina. Physical examinations should be focused on auscultation for carotid bruit, examination for abdominal aorta for aneurysm and peripheral pulses. The additional noninvasive tests based on history and physical examination should be carotid duplex examination, ankle brachial index and duplex ultrasound of the aorta [21].

### RAS with hypertension &/or ischemic nephropathy

Patients with ARAS, in addition to aggressive risk factor modification, can be treated similarly to those with essential hypertension. Continuation of antihypertensive agents is prudent even after RAR for atherosclerotic RAS, specifically for those with ischemic nephropathy. These patients will rarely have 'hypertension cure' post-RAR. The subgroup of ischemic nephropathy among atherosclerotic RAS carries a dismal prognosis. A subgroup of 83 patients among 683 dialysis patients had concomitant ARAS and the survival at 10 years was 5% [22]. The use of

**Table 2. Comparison of specificity, sensitivity, positive and negative predictive value for color Doppler ultrasound, CTA and MRA for renal artery stenosis.**

Modality	Sensitivity (%)	Specificity (%)	Positive predictive value (%)	Negative predictive value (%)
Color Doppler ultrasound	75	89.6	60	94.6
CTA	94	93	71	99
Gadolinium-enhanced MRA	90	94.1	75	98

*CTA: Computerized tomography angiography; MRA: Magnetic resonance angiogram. Data from [40].*

angiotensin-converting enzyme (ACE) inhibitors in patients with bilateral RAS or RAS in a solitary kidney can lead to a reversible decline in renal function, especially after unexpected dehydration in older patients with congestive heart failure [23,24]. The renin–angiotensin system is the main controller of intravascular volume. In patients with essential hypertension, the renal vascular tone is elevated and ACE inhibitors can augment the renal blood flow. This results in salt and water excretion and reduction of blood pressure. In patients with RAS, the angiotensin-mediated mechanism can improve afferent arteriolar dilatation and increase postglomerular resistance. Suppression of such angiotensin in bilateral RAS or RAS with solitary kidney leads to reduction of glomerular filtration and can induce renal failure [25].

In the HOPE trial, ACE-inhibitors used in essential hypertension have shown cardiovascular benefits beyond blood pressure control [26]. The HOPE trial demonstrated that ramipril at 5 years significantly reduced the rates of death, myocardial infarction and stroke in high-risk patients. Long-term follow up at more than 5 years for patients with RAS treated with ACE inhibitors demonstrated lower mortality rates and improved survival [27].

### Renal artery revascularization

Renal artery revascularization should be carried out for limited indications as described in **Box 1**. The role for renal revascularization should always be considered in conjunction with optimal medical treatment.

### ■ Surgical revascularization

Several surgical procedures have been adopted for the revascularization of RAS. The various techniques available are shown in **Box 2**.

Despite the safety of surgical revascularization, the outcomes of the renal artery after surgery show only marginal benefit [28]. Recovery of renal function was demonstrated 3 years after surgical revascularization in 25–30% of 308 patients with impaired renal function and RAS. Loss of renal function was seen in

19–25% and the remainder had no change in renal function. High-volume academic centers have demonstrated the safety of surgery for RAS. The mortality rate was 5.6% in a series of 323 patients who underwent surgical revascularization for RAS over a period of 15 years [29]. However, a recent analysis of nationwide outcome of renal artery bypass graft surgery demonstrated an astonishing mortality rate of 10% [30].

### ■ Percutaneous RAR

Initial experience with renal artery angioplasty was described by Gruntzig *et al.* in 1977 [31]. The last three decades have witnessed thousands of percutaneous renal artery revascularizations (PTRAs) performed worldwide. There are only a handful of prospective randomized trials on PTRAs versus medical treatment, and the results are mostly contradictory. A study of primary renal artery stenting by Lederman *et al.* found that a majority of patients with hypertension or renal insufficiency benefit from revascularization and stenting [32]. Webster *et al.* randomized 55 patients with RAS and hypertension. Modest improvement of hypertension was noted in the RAS group compared with medical treatment [33]. Plouin *et al.* randomized 49 patients to medical treatment (n = 26) versus renal artery percutaneous angioplasty (n = 23) and found minimal improvements in blood pressure at 6 months [34]. Van Jaarsveld *et al.* randomized 106 patients with atherosclerotic RAS with hypertension to percutaneous renal artery angioplasty/stent or medical therapy [35]. The study concluded that angioplasty has minimal advantage over medical treatment. As the controversy of the role of percutaneous angioplasty/stenting for RAS continued to evolve, so did the innovative treatment options for percutaneous vascular interventions. The GREAT trial evaluated the role of bare metal stents versus drug-eluting stents in the renal arteries. Despite a blood pressure improvement in both arms, there was no difference in the angiographic outcomes in terms of restenosis, target vessel revascularization, worsening of renal function and major adverse events [36].

#### Box 1. Indications for renal artery revascularizations are renal artery stenosis with the following four conditions.

- Uncontrolled hypertension despite low salt diet, exercise and three antihypertensives.
- Recurrent pulmonary edema.
- Progressive renal insufficiency in a patient with serum creatinine.
- Angina out of proportion to the degree of coronary artery disease.

Adapted from [41].

**Box 2. Types of surgical revascularization for renal artery stenosis.**

- Aorta renal bypass with saphenous vein or internal iliac artery or prosthetic grafts.
- Spleen–renal or hepatic–renal bypass.
- Renal artery endarterectomy.

Adapted from [42].

Cooper *et al.* elegantly demonstrated the benefit of glycoprotein IIb/IIIa inhibitor with distal protection in patients who undergo renal artery stenting [37]. However, there was a decline in the glomerular filtration rate with stenting alone, stent with abciximab and stent with distal protection.

The latest argument against renal artery stenting comes from the Angioplasty and Stent for Renal Artery Lesions (ASTRAL) study presented at the American College of Cardiology Annual Sessions in April 2008. ASTRAL randomized 403 patients each to medical treatment versus PTRAs over 7 years [38]. Cardiovascular mortality was seen in 7.4% of the PTRAs group and 8.2% of the medically treated group ( $p =$  not significant). Hospital admissions for congestive heart failure occurred in 12% of the PTRAs group and 14% of the medically treated group ( $p =$  not significant). There was no statistically significant difference in renal function, blood pressure, time to first renal event or overall vascular event. Thus, the role of revascularization in patients with atherosclerotic RAS continues to be questionable.

The NIH-funded Cardiovascular Outcomes of Renal Artery Lesions (CORAL) trial is ongoing. A total of 1080 patients with atherosclerotic RAS are being enrolled at 100 sites in the USA and worldwide. The inclusion criteria are

greater than 60% angiographically determined RAS with hypertension requiring two or more antihypertensive medications or glomerular filtration rate less than 60. The patients will be prospectively randomized to optimal medical treatment versus optimal medical treatment plus renal artery stenting. The optimal medical treatment will include use of ACE inhibitors and aspirin in all patients and the guideline-driven treatment of blood pressure, low-density lipoproteins and HbA1c. All patients will be advised regarding smoking cessation and exercise. The primary outcomes at 5 years will be cardiac or renal death, stroke and myocardial infarction, hospital admission for heart failure, progressive renal failure and hemodialysis.

We believe that the CORAL trial will provide more answers to the dilemmas and controversies of renal artery stenting [39].

**Financial & competing interests disclosure**

*The authors have no relevant affiliations or financial involvement with any organization or entity with a financial interest in or financial conflict with the subject matter or materials discussed in the manuscript. This includes employment, consultancies, honoraria, stock ownership or options, expert testimony, grants or patents received or pending, or royalties.*

*No writing assistance was utilized in the production of this manuscript.*

**Executive summary**

- Renal artery stenosis (RAS) is an important cause of secondary hypertension.
- Patients with renal artery stenosis carry a high morbidity and mortality at 5 years.
- Stroke and myocardial infarction continues to be the main comorbidities leading to increased mortality in patients with RAS.
- The clinical manifestations of RAS include uncontrolled hypertension, congestive heart failure, progressive renal dysfunction and angina.
- RAS can be diagnosed easily with duplex ultrasound, CT scan or MRI, and the gold standard continues to be renal artery arteriography.
- The pivotal treatment option for patients with RAS is maximizing medical treatment.
- The role of renal artery revascularization with stenting is controversial owing to limited benefits and potential adverse effects such as plaque embolization and contrast-induced nephropathy.
- Cardiovascular Outcomes of Renal Artery Atherosclerotic Lesions (CORAL) is an ongoing clinical trial to determine the role of maximal medical therapy versus stents for RAS.

**Bibliography**

- 1 Simon N, Franklin SS, Bleifer KH, Maxwell MH: Clinical characteristics of renovascular hypertension. *JAMA* 29, 220(9), 1209–1218 (1972).
- 2 Stancanelli B, Maugeri E, Nicosia A *et al.*: Coronary heart disease extension as a predictor of atherosclerotic renal artery stenosis. *J. Nephrol.* 21(3), 421–425 (2008).
- 3 Kalra PA, Guo H, Kausz AT *et al.*: Atherosclerotic renovascular disease in United States patients aged 67 years or older: risk factors, revascularization, and prognosis. *Kidney Int.* 68(1), 293–301 (2005).
- 4 Plouin PF, Perdu J, La Batide-Alanore A, Boutouyrie P, Gimenez-Roqueplo AP, Jeunemaitre X: Fibromuscular dysplasia. *Orphanet. J. Rare Dis.* 2, 28 (2007).
- 5 Cheung CM, Hegarty J, Kalra PA: Dilemmas in the management of renal artery stenosis. *Br. Med. Bull.* 73–74, 35–55 (2005).
- 6 Hansen KJ, Edwards MS, Craven TE *et al.*: Prevalence of renovascular disease in the elderly: a population-based study. *J. Vasc. Surg.* 36(3), 443–451 (2002).



- 7 O'Neil EA, Hansen KJ, Canzanello VJ, Pennell TC, Dean RH: Prevalence of ischemic nephropathy in patients with renal insufficiency. *Am. Surg.* 58(8), 485–490 (1992).
- 8 Scoble JE, Maher ER, Hamilton G, Dick R, Sweny P, Moorhead JF: Atherosclerotic renovascular disease causing renal impairment – a case for treatment. *Clin. Nephrol.* 31(3), 119–122 (1989).
- 9 Meaney TF, Dustan HP, McCormack LJ: Natural history of renal arterial disease. *Radiology* 91(5) 881–887 (1968).
- 10 Crowley JJ, Santos RM, Peter RH *et al.*: Progression of renal artery stenosis in patients undergoing cardiac catheterization. *Am. Heart J.* 136(5), 913–918 (1998).
- 11 Caps MT, Perissinotto C, Zierler RE *et al.*: Prospective study of atherosclerotic disease progression in the renal artery. *Circulation* 98(25), 2866–2872 (1968).
- 12 Scoble JE: Is the 'wait-and-see' approach justified in atherosclerotic renal artery stenosis? *Nephrol. Dial. Transplant.* 10(5), 588–589 (1995).
- 13 Fehr T, Rickli H, Müller J, Wüthrich RP, Ammann P: Kidney at risk: 11-year course of renal artery stenosis. *Nephrol Dial Transplant.* 18(2), 443–444 (2003).
- 14 Conlon PJ, Little MA, Pieper K, Mark DB: Severity of renal vascular disease predicts mortality in patients undergoing coronary angiography. *Kidney Int.* 60, 1490–1497 (2001).
- 15 Suresh M, Laboi P, Mamtara H *et al.*: Relationship of renal dysfunction to proximal arterial disease severity in atherosclerotic renovascular disease. *Nephrol. Dial. Trans.* 15, 631 (2000).
- 16 Chade AR, Rodriguez-Porcel M, Grande JP *et al.*: Distinct renal injury in early atherosclerosis and renovascular disease. *Circulation* 106(9), 1165–1171 (2002).
- 17 Goldblatt H, Lynch J, Hanzal RF, Summerville WW: Studies on experimental hypertension. The production of persistent elevation of systolic blood pressure by means of renal ischemia. *J. Exp. Med.* 59, 347–348 (1934).
- 18 Voiculescu A, Hofer M, Hetzel GR *et al.*: Noninvasive investigation for renal artery stenosis: contrast-enhanced magnetic resonance angiography and color Doppler sonography as compared with digital subtraction angiography. *Clin. Exp. Hypertens.* 23(7), 521–531 (2001).
- 19 Hirsch AT, Cirqui MH, Treat-Jacobson D *et al.*: Peripheral arterial disease detection, awareness, and treatment in primary care. *JAMA* 286, 1371 (2001).
- 20 Safian RD, Textor SC: Renal artery stenosis. *N. Engl. J. Med.* 344, 431 (2001).
- 21 Zheng ZJ, Sharrett AR, Chambless LE *et al.*: Associations of ankle brachial index, stroke and preclinical carotid and popliteal atherosclerosis: the atherosclerosis risk in communities (ARIC) study. *Atherosclerosis* 131, 115 (1997).
- 22 Mailloux LU, Napolitano B, Bellucci AG, Vernace M, Wilkes BM, Mossey R: Renal vascular disease causing end-stage renal disease, incidence, clinical correlates, and outcomes: a 20-year clinical experience. *Am. J. Kidney Dis.* 24(4), 622–629 (2001).
- 23 Wynckel A, Ebilkili B, Melin JP, Randoux C, Lavaud S, Chanard J: Long-term follow-up of acute renal failure caused by angiotensin converting enzyme inhibitors. *Am. J. Hypertens.* 11, 1080–1086 (1998).
- 24 Burnier M, Waeber B, Nussberger J, Brunner HR: Effect of angiotensin converting enzyme inhibition in renovascular hypertension. *J. Hypertens.* 7(7), S27–S31 (1989).
- 25 Hollenberg NK: Renal hemodynamics in essential and renovascular hypertension. Influence of captopril. *Am. J. Med.* 76(5B), 22–28 (1984).
- 26 Yusuf S, Sleight P, Pogue J, Bosch J, Davies R, Dagenais G: Effects of an angiotensin-converting-enzyme inhibitor, ramipril, on cardiovascular events in high-risk patients. The heart outcomes prevention evaluation study investigators. *N. Engl. J. Med.* 342(3), 145–153 (2000).
- 27 Losito A, Errico R, Santirosi P, Lupattelli T, Scalera GB, Lupattelli L: Long-term follow-up of atherosclerotic renovascular disease. Beneficial effect of ACE inhibition. *Nephrol. Dial. Transplant.* 20(8), 1604–1609 (2005).
- 28 Textor SC: Ischemic nephropathy: where are we now? *J. Am. Soc. Nephrol.* 15(8), 1974–1982 (2004).
- 29 Cambria RP, Brewster DC, L'Italien GJ *et al.*: The durability of different reconstructive techniques for atherosclerotic renal artery disease. *J. Vasc. Surg.* 20(1), 76–85 (1994).
- 30 Modrall JG, Rosero EB, Smith ST *et al.*: Operative mortality for renal artery bypass in the United States: results from the National Inpatient Sample. *J. Vasc. Surg.* 48(2), 317–322 (2008).
- 31 Grüntzig A, Kuhlmann U, Vetter W, Lütolf U, Meier B, Siegenthaler W: Treatment of renovascular hypertension with percutaneous transluminal dilatation of a renal-artery stenosis. *Lancet* 1(8068), 801–802 (1978).
- 32 Lederman RJ, Mendelsohn FO, Santos R, Phillips HR, Stack RS, Crowley JJ: Primary renal artery stenting: characteristics and outcomes after 363 procedures. *Am. Heart J.* 142(2), 314–323 (2001).
- 33 Webster J, Marshall F, Abdalla M *et al.*: Randomised comparison of percutaneous angioplasty vs continued medical therapy for hypertensive patients with atheromatous renal artery stenosis. Scottish and Newcastle Renal Artery Stenosis Collaborative Group. *J. Hum. Hypertens.* 12(5), 329–335 (1998).
- 34 Plouin PF, Raynaud A, Azizi M, Chatellier G: Transluminal vascular stents for ostial atherosclerotic renal artery stenosis. *Lancet* 346(8982), 1109 (1995).
- 35 Van Jaarsveld BC, Krijnen P, Pieterman H *et al.*: The effect of balloon angioplasty on hypertension in atherosclerotic renal-artery stenosis. Dutch Renal Artery Stenosis Intervention Cooperative Study Group. *N. Engl. J. Med.* 342(14), 1007–1014 (2000).
- 36 Zähringer M, Sapoval M, Pattynama PM *et al.*: Sirolimus-eluting versus bare-metal low-profile stent for renal artery treatment (GREAT Trial): angiographic follow-up after 6 months and clinical outcome up to 2 years. *J. Endovasc. Ther.* 14(4), 460–468 (2007).
- 37 Cooper CJ, Haller ST, Colyer W *et al.*: Embolic protection and platelet inhibition during renal artery stenting. *Circulation* 117(21), 2752–2760 (2008).
- 38 Mistry S, Ives N, Harding J *et al.*: Angioplasty and Stent for Renal Artery Lesions (ASTRAL trial): rationale, methods and results so far. *J. Hum. Hypertens.* 21 (7), 507–508 (2008).
- 39 Cooper CJ, Murphy TP, Matsumoto A *et al.*: Stent revascularization for the prevention of cardiovascular and renal events among patients with renal artery stenosis and systolic hypertension: rationale and design of the CORAL trial. *Am. Heart J.* 152, 59–66 (2006).
- 40 Rountas C, Vlychou M, Vassiou K *et al.*: Imaging modalities for renal artery stenosis in suspected renovascular hypertension: prospective intraindividual comparison of color Doppler US, CT angiography, GD-enhanced MR angiography, and digital subtraction angiography. *Ren. Fail.* 29(3), 295–302 (2001).
- 41 Kidney DD, Deutsch LS: The indications and results of percutaneous transluminal angioplasty and stenting in renal artery stenosis. *Semin. Vasc. Surg.* 9(3), 188–197 (1996).
- 42 Darling III RC, Kreienberg PB, Chang BB *et al.*: Outcomes of renal artery reconstruction: analysis of 687 procedures. *Ann. Surg.* 230(4), 524 (1999).

## Website

- 101 Khan AN, MacDonald S, Sohaib M, Saeed S: Renal artery stenosis/renovascular hypertension. *e-medicine* (2008). <http://emedicine.medscape.com/article/380308-overview>