

Trapezectomy and ligament reconstruction tendon interposition- 15 year follow up- do DASH scores correlate with patient satisfaction

Aim: To determine the long term patient disability scores, patient satisfaction and their correlation after trapeziectomy with partial Flexor Carpi Radialis (FCR) tendon transfer and interposition.

Method: A cross-sectional analytic study of 182 patients was undertaken from 1993 to 2008 of all trapeziectomies performed by one surgeon. A participation acceptance letter, consent, a DASH Score and patient satisfaction scale letter were sent to all patients. Medical records were thoroughly reviewed, and data collection was gathered, analyzed and reported.

Results: We had a sixty seven percent reply rate, with patients scoring an average DASH of 21.5. Average satisfaction score was 8.78. Patients scoring a DASH score of >40 were also reporting other upper limb pathologies.

Conclusion: Satisfaction and disability trends improved with time. High DASH scores did not always correlate with patient satisfaction score. The DASH does not measure patient satisfaction, which is an important, but difficult measure of the clinical outcome.

Ali Moaaz*, Igor Pollicinski & Chris Roberts

Orthopaedic Registrar, The Canberra Hospital, Australia

*Author for correspondence: dr.alimoaaz@gmail.com

Introduction

The first carpometacarpal joint (CMCJ) is a highly functioning joint, which is used in any daily routine repeatedly, not surprisingly, degenerative osteoarthritis affects a high number of patients after the age of 75 [1]. The disability from stiffness and pain that follows makes this joint a common site for surgical intervention. Non-operative management with NSAIDS, splinting and sometimes corticosteroid injections is usually the first line management. Surgery usually follows after failed non-operative management, with numerous surgical variations and techniques developed [2]. These include arthrodesis [3], trapezial excision alone [4,5], trapezial excision with Ligament Reconstruction and Tendon Interposition (LRTI) using [FCR [6], Abductor Pollicis Longus [7,8]], silicone arthroplasty [9,10], acellular dermal allograft [11], Darcon interposition [12] and total joint implant arthroplasty [13]. Understanding the anatomy and pathophysiology of CMCJ is a key to the surgical management of the diseased joint.

Anatomy

The CMCJ, a saddle joint, is a semi constrained and incongruent joint, where the sad-

dle is the trapezium and the first metacarpal the rider. Surrounded and held with five ligaments and nine muscles to obtain further stability, it can achieve complex movement from four basic planes of motion, flexion and extension, adduction and abduction [14]. Such movements include opposition, palmar and radial abduction, palmar and radial adduction, and circumduction. A static restraint to the joint, is provided by the anterior oblique ligament (also called palmar or beak ligament), which attaches from the palmar tubercle of the trapezium and inserts on metacarpal base, at the ulnar articular margin [15]. Its complexity is increased by four articulations which included trapeziometacarpal, trapezio-trapezoid, scaphotrapezoid and trapezium-index metacarpal each a potential site for disease and pain. The pathophysiology of base of thumb osteoarthritis is multifactorial; however the main postulated cause is the weakening of the palmar beak ligament, causing an increased translation of the metacarpal on the trapezium. This in turn changes the shear stresses in the joint, leading to accelerated cartilage wear [16,17].

Methods

Patients who underwent a trapeziectomy with LRTI were identified from a medical data

base of a single high volume surgeon. Surgery is performed under GA and application of tourniquet. Affected limb is prepped with antiseptic solution and draped. A zigzag incision is made over the anatomical snuff box, identifying and protecting the dorsal branch of radial nerve throughout the procedure. Trapezium is excised in a piecemeal fashion protecting FCR tendon (Figure 1). Radial half of FCR is used for reconstruction and remaining tendon bunched up into anchovy using 3/0 vicryl (Figures 2 and 3). Stability is assessed on table. Tourniquet is then released and haemostasis assessed and secured. Local anesthetic is then infiltrated and skin edges loosely closed with 4/0 Prolene. A bulky padded dressing with thumb spica is applied. Patient is reviewed in outpatients two weeks later, wound assessed and scaphoid cast applied for another 4 weeks. At six weeks mark, cast is removed and custom made removable splint applied.

182 patients were found to have had the surgery between 1993 and 2008. A study package was prepared that contained a participation acceptance letter with a consent, a DASH Score and scale of satisfaction letter. Medical records were systematically reviewed, and data collection was performed. The DASH score included a work DASH and a sport DASH. The scale of satisfaction was a simple and comprehensible grading system to reflect on patient satisfaction, irrespective of the clinical outcomes. It constituted of a 1 to 10 grade visual graph, which need to be marked by the patient, one being completely dissatisfied, whilst 10 was complete satisfaction.

The data was analyzed and standard statistical protocol was applied to the results, which were presented at a state meeting.

Results

We identified 182 potential patients from the above mentioned time frame. Sixty patients did not reply to our package, and were contacted personally. Of the sixty patients, two have died, eleven changed address and were not contactable, forty seven refused to participate in the study. 122 patients replied with 124 operations (two bilateral). In our population, we had 74% females, with an age average of 66 years (Male 67; Female 66) and a range 49 to 86 years. Right side was the predominant side of operation, 55%. Our average time frame since the surgery was 52.5 months, with a range 7 to 144 months. Average DASH score was 21.5, with a range 0-78. Average Work DASH score was 16.1, with a range 0-100. Average Sport DASH score was

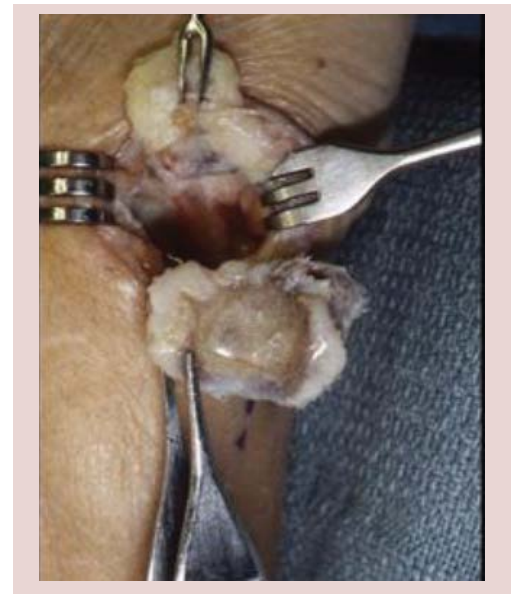

Figure 1: Appearance of excised Trapezium.

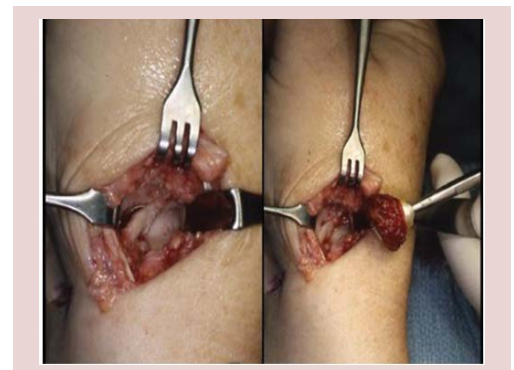

Figure 2 and 3: Excision Arthroplasty with Rolled Tendon Graft.

18.1, with a range 0-87.5. The patient satisfaction scale showed an average satisfaction score of 8.78 out of 10, with a range 1 to 10.

Discussion

Patient satisfaction plays a major role in surgeons practice. As surgeons we want to achieve the best possible results for our patients, and explore the need for an objective scoring system, like the DASH, that can guide us, in the right direction, to modify our techniques and management (Figure 4). Unfortunately, this can be difficult as our scoring systems do not take into account the subjective report of our patient. Our study demonstrates that even though some high DASH scores were scored by patients, it did not necessarily mean they were dissatisfied with the outcome, meaning that higher DASH scores did not affect some patients' satisfaction score. Our DASH scores are comparable to the literature,

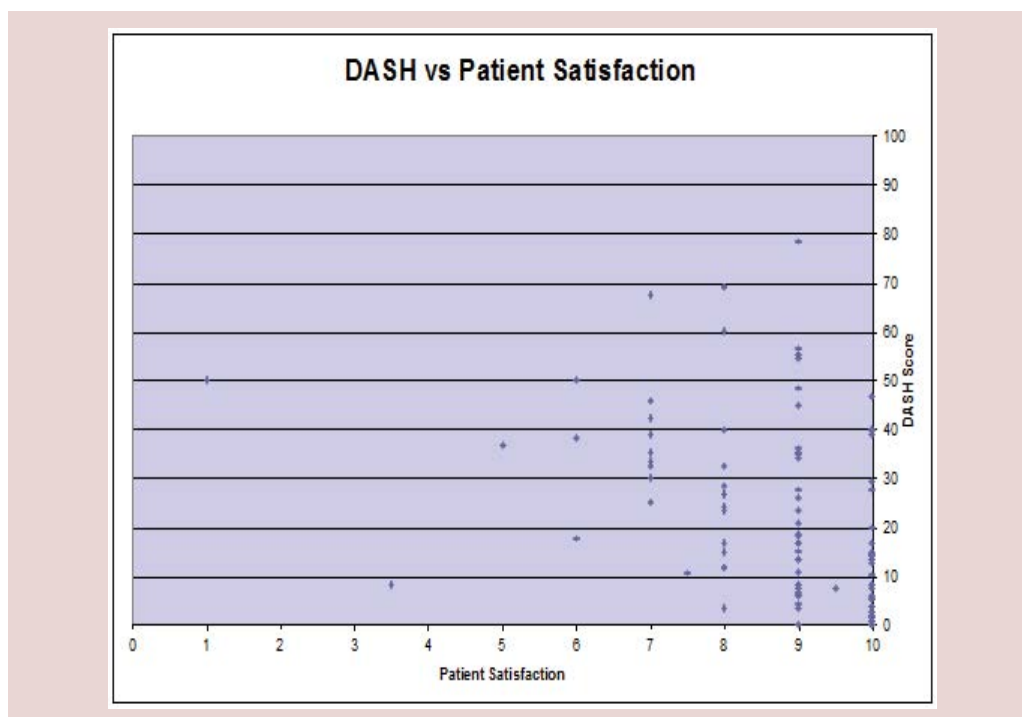


Figure 4: Higher DASH scores do not always correlate with patient satisfaction.

which validates that trapeziectomy with ligament reconstruction and tendon interposition is an excellent surgical option for patients with CMCJ osteoarthritis [18,19].

Our study results are quite similar to other studies in the literature evaluating the effectiveness and promising long term outcomes of Trapeziectomy & LRTI for treatment of 1st CMCJ OA. Quite a few studies have compared different procedures for the treatment of 1st CMCJ arthritis, some reporting LRTI demonstrating better long term outcomes and lesser complications.

Vanderburghe et al. [20] in his study compared outcomes of Trapeziectomy & LRTI with thumb basal joint prosthesis. Though he observed no significant differences when comparing impairment, pain, patient satisfaction and disability, yet he preferred Trapeziectomy & LRTI over prosthesis because of unproven benefit and associated cost of prosthesis.

In another Level 1 study by Spekreijse et al. [21], showed improved function, strength and satisfaction obtained at 1 year post Trapeziectomy & LRTI with or without bone tunnel for stage IV Trapeziometacarpel OA and was maintained at 5 year follow up.

Camus et al. [22] looked at 47 cases of Trapeziectomy & LRTI with a five year follow up evaluating using a functional score, including

pain, professional and domestic activities and leisure involving the hand. Objective data were also assessed. They found that Trapeziectomy with LRTI yields good and stable long term results.

With time we noticed a higher satisfaction score and an improved DASH (Figures 5 and 6). Our patients had a 95% chance of having a satisfaction score of >7. Out of eighteen patients with high DASH scores >40, twelve reported other upper limb pathologies and one had spine issues.

In our study, patient with a poor satisfaction score and a DASH score of 50 in both Work and Sport was a jeweller. DASH score and satisfaction scale did not correlate to each other.

Conclusion

As mentioned above, satisfaction and disability trends improved with time. Higher DASH scores did not always correlate with patient satisfaction (Figure 1). Various studies have tried to evaluate long term outcomes for patients undergoing Trapeziectomy and LRTI using various techniques. On the whole they concluded that patients who underwent LRTI were more likely to consider surgery again if need be even with higher DASH scores [23]. Prospective RCT's with additional hand function measurement scores [24] can be employed in addition to DASH to further evaluate the effectiveness of the procedure and the longevity of results.

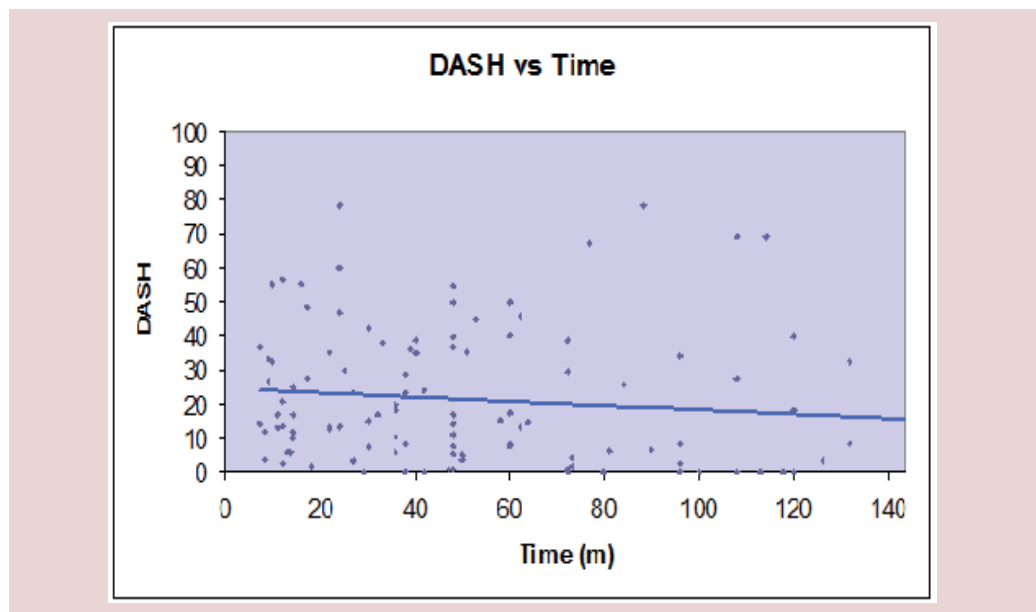


Figure 5: Disability trends improved with time.

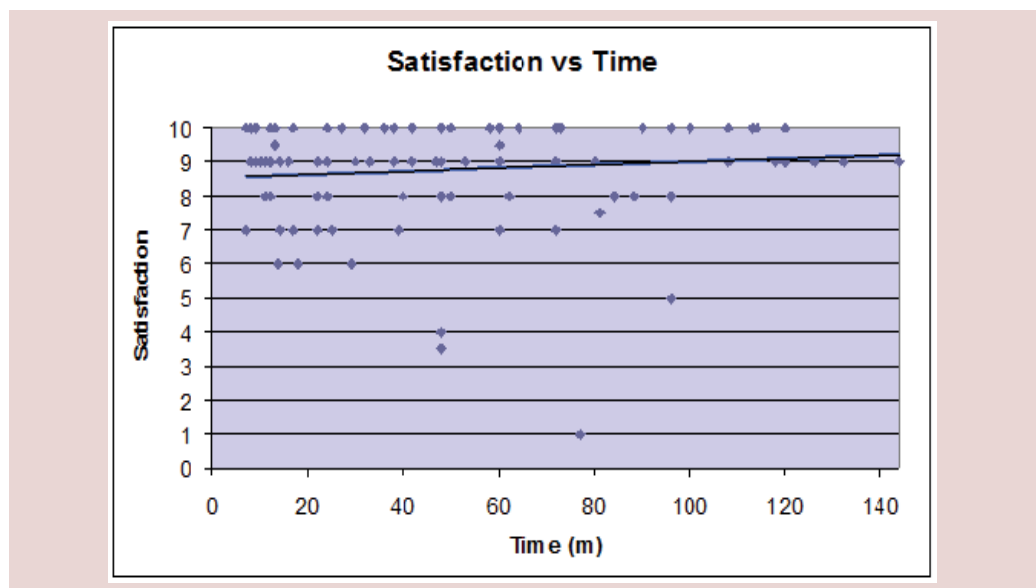


Figure 6: Patient satisfaction post procedure improved with time.

References

1. Armstrong AL, Hunter JB, Davis TR. The prevalence of degenerative arthritis of the base of the thumb in post-menopausal women. *J. Hand. Surg. Br.* 19, 340-341 (1994).
2. Vermeulen GM, Brink SM, Sluiter J *et al.* Ligament reconstruction arthroplasty for primary thumb carpometacarpal osteoarthritis (Weilby Technique) prospective cohort study. *J. Hand Surg.* 34, 1393-1404 (2009).
3. Muller GM. Arthrodesis of the trapezio-metacarpal joint for osteoarthritis. *J. Bone. Joint. Surg. Br.* 31B, 540-542 (1949).
4. Gervis WH (1949) Excision of the trapezium for osteoarthritis of the trapezio-metacarpal joint. *J. Bone. Joint. Surg. Br.* 31B, 537-539 (1949).
5. Murley AHG. Excision of the trapezium in OA of the first CMCJ. *JBJS.* 42b: 502-507 (1960).
6. Burton RI, Pellegrini VD. Surgical Management of basal joint arthritis of thumb: Part II. Ligament reconstruction with tendon interposition arthroplasty. *J. Hand. Surgery.* 11A, 324-332 (1986).
7. Thompson JS. Surgical treatment of trapeziometacarpal arthrosis. *Adv. Orthop. Surg.* 10, 105-120 (1986).
8. Thompson JS. Complications and salvage of trapeziometacarpal arthroplasties. *Instr. Course. Lect.* 38, 3-13 (1989).
9. Swanson AB. Disabling arthritis at the base of the

- thumb: treatment by resection of the trapezium and flexible (silicone) implant arthroplasty. *J. Bone. Joint. Surg. Am.* 54, 456-471(1972).
10. Ruffin RA, Rayan GM. Treatment of trapeziometacarpal arthritis with silastic and metallic implant arthroplasty. *Hand. Clin.* 17, 245-253 (2001).
11. Kokkalis ZT, Znaros G, Weiser RW *et al.* Trapezium resection with suspension and interposition arthroplasty using acellular dermal allograft for thumb carpometacarpal arthritis. *J. Hand. Surg.* 34A, 1029-1036 (2009).
12. Voulliaume D, Forli A, Guinard D *et al.* Anchovy dacron arthroplasty in the treatment of basal osteoarthritis of the thumb: long term results. *Chir. Main.* 22, 197-202 (2003).
13. Lemoine S, Wavreille G, Alnot JY *et al.* Second generation GUEPAR total arthroplasty of the thumb basal joint: 50 months follow-up in 84 cases. *Orthop. Traumatol. Surg. Res.* 95, 63-69 (2009).
14. Van Heest AE, Kallemeier P. Thumb carpal metacarpal arthritis. *J. Am. Acad. Orthop. Surg.* 16, 140-151(2008).
15. Bettinger PC, Linscheid RL, Berger RA *et al.* An anatomic study of the stabilizing ligaments of the trapezium and trapeziometacarpal joint. *J. Hand. Surg. Am.* 24, 786-798 (1999).
16. Pellegrini VD. Osteoarthritis of the trapeziometacarpal joint: the pathophysiology of articular cartilage degeneration. I. Anatomy and pathology of the aging joint. *J. Hand. Surg. Am.* 16, 967-974 (1991).
17. Rab M, Gohritz A, Gohla T *et al.* Long term results after resection arthroplasty in patients with arthrosis of the thumb carpometacarpal joint: comparison of abductor pollicis longus and flexor carpi radialis tendon suspension. *Handchir. Mikrochir. Plast. Chir.* 38, 98-103 (2006).
18. Raven EEJ, Kerkhoffs GMMJ, Rutten S *et al.* Long term results of surgical intervention for osteoarthritis of the trapeziometacarpal joint: comparison of resection arthroplasty, trapeziectomy with tendon interposition and trapezio-metacarpal arthrodesis. *Int. Orthop.* 34, 547-554 (2007).
19. Gray KV, Meals RA. Hematoma and distraction arthroplasty for thumb basal joint osteoarthritis: minimum 6.5-year follow-up evaluation. *J. Hand. Surg. Am.* 32, 23-29 (2007).
20. Vandenberghe L, Degreef I, Didden K *et al.* Long term outcome of trapeziectomy with ligament reconstruction/tendon interposition versus thumb basal joint prosthesis. *J. Hand. Surg. Eur.* 38, 839-843 (2013).
21. Spekreijse KR, Vermeulen GM, Kedilioglu MA *et al.* The Effect of a Bone Tunnel During Ligament Reconstruction for trapeziometacarpal osteoarthritis: A 5-year follow-up. *J. Hand. Surg. Am.* 40, 2214-2222 (2015).
22. Camus E, Farez E, Rtaimate M *et al.* Surgical treatment of carpometacarpal joint osteoarthritis of the thumb by trapeziectomy-interposition-ligamentoplasty. *Chir. Main.* 19, 36-43 (2000).
23. Tomaino MM, Pellegrini VD, Burton RI. Arthroplasty of the basal joint of the thumb. Long-term follow-up after ligament reconstruction with tendon interposition. *J. Bone. Joint. Surg. Am.* 77, 346-355 (1995).
24. Poole JL. Measures of hand function: Arthritis Hand Function Test (AHFT), Australian Canadian Osteoarthritis Hand Index (AUSCAN), Cochin Hand Function Scale, Functional Index for Hand Osteoarthritis (FIHOA), Grip Ability Test (GAT), Jebsen Hand Function Test (JHFT), and Michigan Hand Outcomes Questionnaire (MHQ). *Arthritis. Care. Res.* 63, S189-S199 (2011).