



The role of endobronchial ultrasound in diagnosis, staging and treatment

Felix JF Herth[†] &
Ralf Eberhardt

[†]Author for correspondence
Thoraxklinik am
Universitätsklinikum,
Department of Internal
Medicine, Pneumology
and Critical Care,
Thoraxklinik Heidelberg,
Germany
f@herth.net

Conventional imaging procedures proved to be insufficient for staging of lung cancer especially with respect to N-stage, infiltration of mediastinal structures and early lung cancer. As the endoscopist view is restricted, we developed a new method of endobronchial ultrasonography as adjunct to conventional bronchoscopy. The initial technical problems were solved by development of a balloon catheter for application of miniaturized 20 MHz probes. Endobronchial ultrasonography is a new technology that can be easily applied and is well tolerated. It improves the results of bronchoscopy in addition to conventional diagnostic procedures. Further developments will be made in future to improve the application of ultrasound in chest medicine.

Aim of the report

Many pathologies of the airways involve the bronchial wall and the parabranchial structures. Radiologic imaging has been proven to be unreliable in the diagnosis of the bronchial wall and the enlarged mediastinal nodes [1,2]. The view of the endoscopist however, is restricted to the lumen and the internal surface of the airways. Processes within the airway wall and outside the airways can only be assessed by indirect signs. Especially in malignancies, this can be of decisive importance for the fate of the patient. Therefore expanding the endoscopist's view beyond the airways is essential [3].

As endoluminal ultrasound is superior in comparison to radiologic exploration and has been established as a routine diagnostic procedure in other fields of medicine [4]. This is especially true of gastrointestinal endoscopy where endoluminal ultrasound is firmly established in the staging of esophageal carcinoma, carcinoma of the cardia and rectum in diagnosing primary tumors and lymph node metastasis, as well as involvement of the neighboring structures [4–7]. In these indications, it becomes far superior to therapeutic procedures. In the investigation of mediastinal and parabranchial structures external transthoracic ultrasound has been applied with some success in lesions of the anterior mediastinum and the subcarinal region. The lower paratracheal structures and perihilar structures however are usually out of reach [8].

Since the beginning of 2004, two different endobronchial ultrasound (EBUS) techniques have become available – the so-called miniprobe and the Transbronchial Needle Aspiration

(TBNA)–EBUS scope. The aim of this paper is to highlight the different techniques and to discuss the results of published trials.

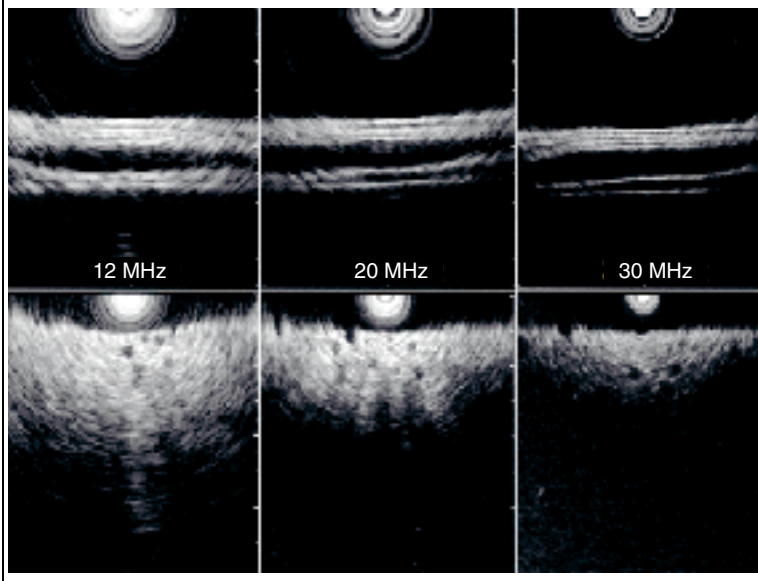
Development of endobronchial ultrasound

Imaging in ultrasound is different from radiologic imaging. Radiologic imaging depends on transmission through tissues in accordance with density, whereas ultrasound operates through reflection or echogenicity at interfaces of tissue density. Instruments that are used for gastrointestinal application could not be applied inside the airways because of their diameter. Furthermore, early animal studies, preliminary experience by using miniaturized endovascular sonographic probes, did not yield useful clinical results and were aborted after a period [9,10]. In addition, the authors summarized that these preliminary results suggest that this US procedure may become an important diagnostic tool during bronchoscopy due to its ability to identify structures beyond the lumen of the tracheobronchial tree [11].

For application inside the central airways, we therefore developed flexible catheters for olympus probes with a balloon at the tip that allows circular contact for the ultrasound, providing a complete 360° image of the parabranchial and paratracheal structures. As the water in the balloon change, the condition of the wave transmission, penetration of the waves produced by 20 MHz probes, increased. Thus under favorable conditions, structures at a distance of up to 4 cm can be visualized.

In case of lower frequencies, such as 7.5 MHz, the waves have a better penetration – up to 8 or 9 cm, but a lower resolution of areas nearest to

Figure 1. Differences between penetration and resolution shown on a paper model.

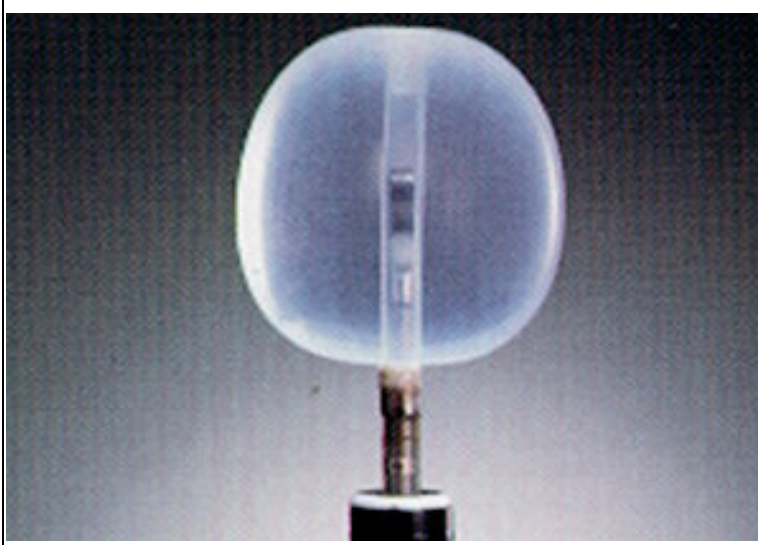

the probe. Using higher frequencies, the depth of penetrations decreases, but the resolutions in the near field improves (Figure 1).

The probes are on the market since 1999 and can be applied with regular flexible endoscopes that have a biopsy channel of at least 2.6 mm (for more technical details see [3,12]). Even complete obstruction of the trachea is tolerated under local anesthesia for up to 2.5 min after sufficient pre-oxygenation and sedation, which is sufficient for acquisition of diagnostic images (Figure 2)[12].

The newest development is the special bronchoscope with an integrated curvilinear electronic

Figure 2. Endobronchial miniprobe within a balloon catheter.



transducer at the tip (Olympus BF-UC40P). So a real-time needle puncture under endoscopic control is possible. The probes provide an ultrasonic frequency of 7.5 MHz with a penetration depth of 5 cm. The scanning direction is parallel to the longitudinal axis of the endoscope with a scanning angle of 50° which enables full ultrasonic monitoring of a needle when inserted via the biopsy channel during scanning (Figure 3).

Sonographic anatomy

The wall of the central airways comprizes a seven-layer structure which can only be demonstrated at high magnification. The layers are representative of the mucosa and submucosa, the three layers of the cartilage and the adjacent external structures of loose and dense connective tissue respectively [13]. According to recent papers, it would appear that the exact number of layers is debatable, and depends on the cartilage plates [14]. A conclusive discussion however, is still missing. Under low-power magnification and in the periphery, only a three-layer structure is visible, orientation by ultrasound within the mediastinum is difficult [15]. Besides the complex mediastinal anatomy this is due to motion artifacts by pulsation and respiration as well as the unusual planes of the ultrasonic images. As with the probes, we have to follow the course of the airways. For orientation therefore, the analysis of characteristic anatomical structures is more reliable than observation of the position of the ultrasound probe inside the airway [16]. Vessels can be diagnosed by their pulsation. However, even after application of echo contrast, media discrimination of venous and arterial vessels can be difficult due to the large number of possible variations. However, pulseoxymetry is applied. Arterial pulsations can be diagnosed according to their synchronism with the acoustic signal. Lymph nodes and solid structures can then be differentiated down to a size of a few mms from the blood vessels by their higher echodensity [17].

Differentiation in the technique

Miniprobes

The radial EBUS probe is conventionally inserted through the working channel of the flexible bronchoscope (outer diameter 2.5 mm). The main problem of application inside the airways is coupling of the ultrasonic probe to the tracheobronchial wall, which results in the naked probe one obtaining only a very limited sectorial view. This was the reason for the introduction of catheters to probes that are equipped with a balloon at the tip. Once this balloon is full of water, it completely

Figure 3. The new EBUS–TBNA scope.

EBUS: Endobronchial Ultrasound; TBNA: Transbronchial Needle Aspiration.

fills the airway and provides a 360° view of the bronchial wall and the mediastinal structures. Water simultaneously serves as an enhancing medium for the ultrasonic waves. Thus, under favourable conditions, even the depth of penetration for the 20 Mhz waves may be up to 5 cm [3]. In the case of a guided puncture, the exact location of the target lymph nodes and their relationship to the tracheobronchial tree can be noted. The probe must be left to work and then removed from the working channel at which time a TBNA is performed.

EBUS–TBNA scope

An ultrasound transducer integrated into a bronchoscope with a separate working channel would potentially increase the yield of TBNA by allowing direct visualization of needle placement within the area of interest. A special ultrasonic puncture bronchoscope by integrating a convex probe (CP) at the tip of the flexible bronchoscope has been developed for this purpose. With this scope, direct TBNA under real time convex probe endobronchial ultrasonography guidance is now possible. The technique is similar to endoesophageal ultrasound-guided needle aspiration (EUS-FNA).

Indications & results of EBUS

Since the early 1990s we have been involved in developing technology, and the miniaturized probe has been on the market since 1999, with EBUS being applied in several centers worldwide. For

some indications the superiority of ultrasound in comparison with conventional imaging has been proven in prospective studies and in some centers, EBUS has already been established as routine procedure [15–17]. According to the structures that can be analyzed, current indications comprise endoluminal, intramural and parabranchial structures. With respect to medical indications early detection and tumor staging, they compose inflammatory destruction of the airways, mediastinal lesions and malformations of mediastinal structures.

Tumor staging

Early cancer

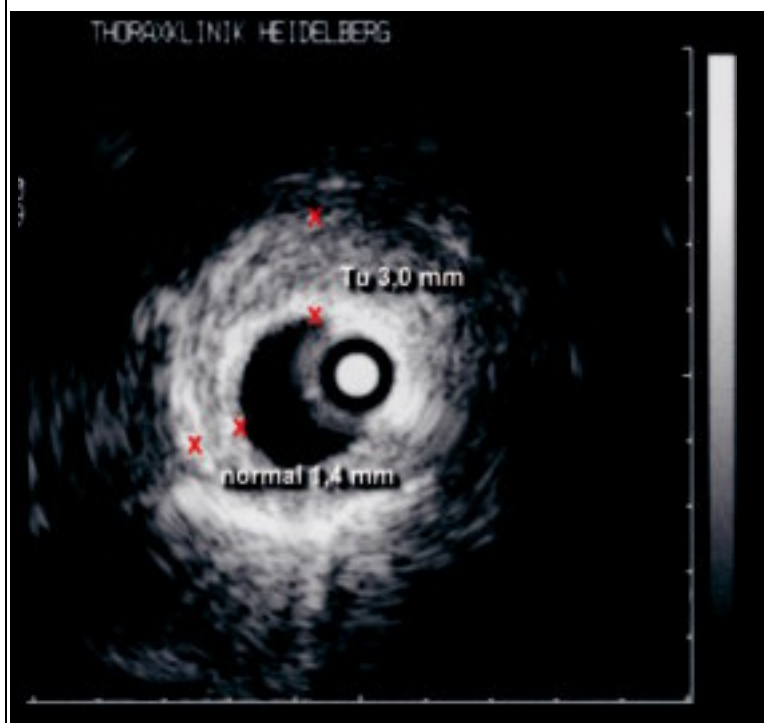
In small radiologically invisible tumors, the decision for local endoscopic therapeutic intervention is dependent on their intraluminal and intramural extent within the different layers of the wall. In contrast to radiologic imaging by EBUS, even very small tumors of a few mms can be analyzed and differentiated from benign lesions. The proof-of-principle was demonstrated by Shaw and colleagues [14]. To assess EBUS versus High Resolution Computed Tomography (HRCT) comparability of airway measures *in vivo*, 12 control subjects underwent imaging of the posterior basal bronchus of the right lower lobe by both techniques. Intra- and interobserver agreement were also assessed. Results with and without the balloon sheath gave comparable measures of airway internal diameter and wall thickness *in vitro*. Statistical analysis showed agreement between EBUS and HRCT, and intra- and interobserver variability *in vivo*. The current study concludes that EBUS, which does not present a radiation risk, could be utilised in the *in vivo* study of cartilaginous airway wall remodelling in respiratory diseases, such as asthma.

As Kurimoto and colleagues demonstrated, EBUS is a very reliable tool in analyzing the extent of these small lesions [18]. We could demonstrate that by EBUS in small autofluorescence (AF)-positive lesions that were negative in white light bronchoscopy (WLB), we could improve specificity (predicting malignancy) from 50–90% [19]. Combination of EBUS with AF has been proven to be efficient in prospective studies and has now become the basis for curative endobronchial treatment of malignancies in some institutions (Figure 4)[20]. Also, a recent publication has shown that the marker of tumor invasion is the disruption of the cartilage layer [21].

Peripheral lesions

The standard procedure for histologic diagnosis of peripheral intrapulmonary lesions by

Figure 4. Small early cancer lesion with thickening of the bronchial wall.



Visible is normal bronchial wall at 7 o'clock (normal) and tumor thickening (Tu) at 3 o'clock.

bronchoscopy is an instrumental approach under fluoroscopic or computed tomography (CT) guidance. This demands expensive x-ray equipment in the bronchoscopy suite or coordination with the radiology department, and results in exposure to radiation for patient and staff. In a prospective study, we were able to show that these lesions could be approached by EBUS guidance with the same success rate of approximately 75% [22] (Figure 5). Recently, these data have been confirmed by another group of Japanese bronchologists [23]. Kurimoto analyzed the ultrasound image of solitary pulmonary nodules. He examined the echogenic pattern of those lesions and found a different pattern between malignant and benign lesions. He summarized that the echogenic pattern of peripheral lesions may allow a statement of the histology [24]. However, fully conclusive studies are still required.

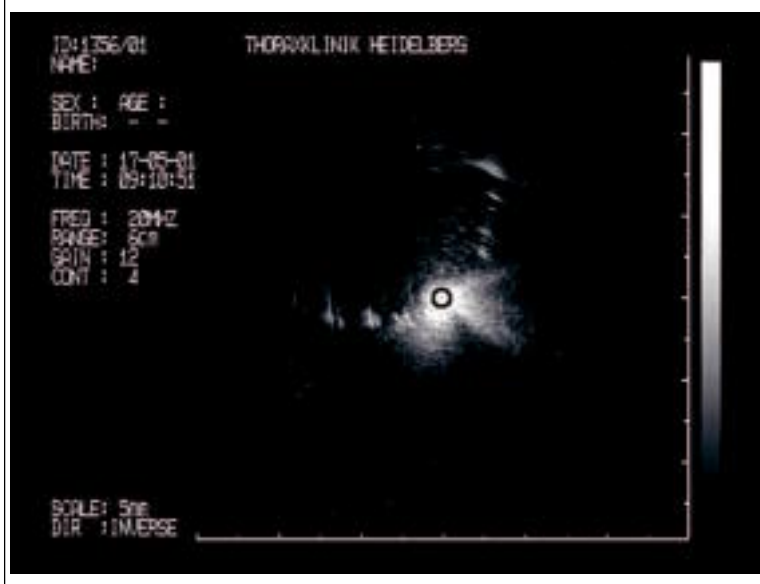
Advanced cancer

In preoperative staging, EBUS allows detailed analysis of intraluminal, submucosal and intramural tumor spread, which can be essential when it comes to decisions regarding resection

margins. EBUS proved especially useful in the diagnosis of mediastinal tumor involvement in the great vessels such as the aorta, cava, main pulmonary arteries, and of the esophageal wall, which by conventional radiology, is frequently impossible. In a prospective study, we demonstrated that differentiation of external tumor invasion from impression of the tracheobronchial wall by EBUS is highly reliable (90%) in contrast to CT imaging (50%) [25]. Thus many patients considered to be nonresectable by the radiologist due to supposed T4 tumors, could be eligible for operation in a curative approach after EBUS. For this purpose, we also successfully applied the miniaturized probes inside the esophagus in order to exclude tumor invasion.

Lymph node staging

Under favorable conditions, lymph nodes can be detected by EBUS down to a size of 2–3 mm and the internal structure (sinuses and folliculi) as well as small lymph vessels can be analyzed. In contrast to previous publications [26] according to our experience with the use of endosonographic localization of lymph nodes, the results of TBNA can be significantly improved – up to 90% [27,28]. This is especially true for those situations in which reliable landmarks on the CT are missing, such as high and low paratracheal localization. There is a significant difference in EBUS-guided TBNA when compared with EUS-controlled biopsy, which is essential for a better understanding. The esophagus is a straight elastic organ without any clear endoscopic landmarks for orientation. It is for this reason that intraprocedural control of the needle during aspiration is essential. In contrast, the tracheobronchial tree is full of landmarks for orientation such as cartilage rings, spurs and branches. Thus, even very small lymph nodes can be safely localized by EBUS and the needle can be sequentially inserted successfully into the lymph node under endoscopic control after the miniature probe is removed from the biopsy channel. In the only comparison trial for both techniques, it was shown that in experienced hands, enlarged mediastinal lymph nodes may be aspirated with either the transbronchial or transesophageal approach. These nonsurgical approaches have similar diagnostic yields, although the transbronchial approach is superior for right-sided lymph nodes. Combining both approaches provides results similar to those of mediastinoscopy [29].

Figure 5. Typical image of a coin lesion.

Lymph-node staging is also the main indication for the new EBUS–TBNA scope. The ultrasonic bronchoscope is introduced to the area of interest via an endotracheal tube under visual control or local anaesthesia to the area of interest. EBUS–TBNA is performed by direct transducer contact with the wall of the trachea or bronchus. When a lesion is outlined, a 22 gauge full length steel needle – Olympus XNA-200C – is introduced via the biopsy channel of the endoscope. Power Doppler examination was used immediately prior to the biopsy in order to avoid unintended puncture of vessels between the wall of the bronchi and the lesion. Under real-time ultrasonic guidance, the needle will be placed in the lesion. Suction was applied with a syringe and the needle was moved back and forth inside the lesion (Figure 6).

Preliminary results are promising. Various authors reported a yield higher than 90% without any complications [30–32]. It is to be expected, that with these guidance tools, future trials may examine punctuation of nodes smaller than 1 cm, such as those published for the EUS technique [33].

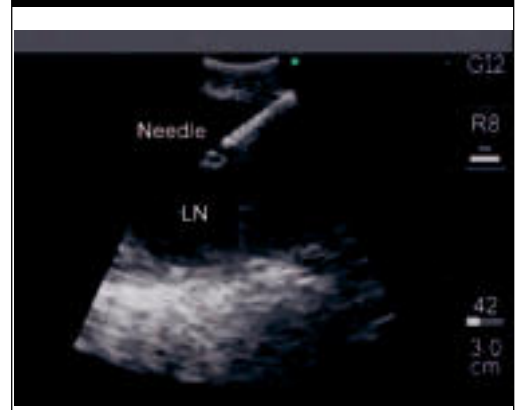Expert opinion

The clinical application and diagnostic results of EBUS is, in some centers, already a routine procedure. Indications for EBUS have been established in studies compared with conventional radiologic methods and other diagnostic procedures.

EBUS proved to be useful in high-resolution imaging of the multilayer structures of the bronchial wall and the adjacent mediastinal

structures in a distance of up to 4 cm. In many instances, it was superior for staging of lung cancer and other pathologies. Since the results of treatment of advanced bronchial carcinoma have been disappointing thus far, detection and treatment at early stages has gained new interest. In particular, new methods such as automated sputum cytology analysis in at-risk individuals and localization of radiologically and macroscopically invisible early carcinoma by fluorescence methods will be used more widely. Lymph nodes could be easily localized for TBNA but tumor infiltration could not be predicted. In addition, other pathologies such as vascular malformations, mediastinal masses, pathologies of neighboring organs and pulmonary lesions could be correctly diagnosed. Thus we come to the conclusion that in the near future, EBUS may play an important role in bronchology at feasible costs. In particular, in on-the-spot decision making during diagnostic and interventional procedures.

A limitation of miniprobes is surely the learning curve. All papers examined herein were published from at least seven different groups. All were well trained and experienced bronchoscopists. Handling of miniprobes and image interpretation remains a difficult diagnostic procedure. Also, only a small number of comparative studies with other diagnostic tools have been published. Nevertheless, with the new technique of the EBUS–TBNA scope, the situation will be changing. Handling has been greatly improved and the learning curve is steep. It is this author's opinion that in the near future, EBUS will be a routine diagnosing and staging procedure in patients with enlarged mediastinal lymph nodes.

Figure 6. Ultrasound-guided real-time puncture of a lymph node (LN).

Bibliography

1. Sihoe AD, Yim AP. Lung cancer staging. *J. Surg. Res.* 117, 92–106 (2004).
2. Spira A, Ettinger DS. Multidisciplinary management of lung cancer. *N. Engl. J. Med.* 350, 379–392 (2004).
3. Herth F, Becker HD. Endobronchial ultrasound of the airways and the mediastinum. *Monaldi Arch. Chest Dis.* 55, 36–45 (2000).
4. Caletti G, Fusaroli P. *Endoscopy* 31, 95–102 (1999).
5. Tio TL, Tytgat GNJ. *Atlas of Transintestinal Ultrasonography*. Mur-Kostver-loren B.V. (Ed.), Almeer, The Netherlands, 1986
6. Tio TL, den Hartog Jager CA, Tytgat GNJ. The role of endoscopic ultrasonography in as-sessing lo-cal resectability of oesophagogastric malignancies. Accuracy, pitfalls and predic-tability. *Scand. J. Ga-stroent.* 21(Suppl. 123), 78 (1986).
7. Vijakumar S, Chan T, Ray V, Grant T, Chiru P, Ray P, Chan GGT. Guidelines for Defi-ning Target Volumes in Radiation Therapy of Prostate Cancer: a Review and Per-spective. *Onkologie* 16, 389–406 (1993).
8. Wernecke K, Pötter K, Peters PE, Koch P. Parasternal mediastinal sonography: sensi-tivity in the detection of anterior mediastinal and subcarinal tumors. *Am. J. Roentgenol.* 150, 1021–1026 (1988).
9. Silverstein FE, Martin RW, Kimmey MB, Jiranek GC, Franklin DW, Proctor A. Experimental evaluation of an endoscopic ultrasound probe: *in vitro* and *in vivo* canine studies. *Gastroenterology* 96(4), 1058–1062 (1989).
10. Hürther Th, Hanrath P: Endobronchial sonography: feasibility and preliminary re-sults. *Thorax* 47, 565–567 (1992).
11. Goldberg BB, Steiner RM, Liu JB *et al.* US-assisted bronchoscopy with use of miniature transducer-containing catheters. *Radiology* 190(1), 233–237 (1994).
12. Herth F, Becker HD. Endobronchial Ultrasound (EBUS) – assessment of a new diagnostic tool in bronchoscopy. *Onkologie* 24, 151–154 (2001).
13. Shirakawa T, Tanaka F, Becker HD. Layer structure of central airway viewed using endobronchial ultrasonography (EBUS). In: *Bronchology and Bronchoesophagology: State of the Art Proceedings of the 11th World Congress for Bronchology (WCB) & the 11th World Congress for Bronchoesophagology* and Compression by Tumor. *Chest* 123, 458–462 (2003).
14. Yoshimura H, Kida A, Arai T *et al.* (Eds), Elsevier, New York, NY, USA (2001).
15. Shaw TJ, Wakely SL, Peebles CR, Mehta RL, Turner JM, Wilson SJ, Howarth PH. Endobronchial ultrasound to assess airway wall thickening: validation *in vitro* and *in vivo*. *Eur. Respir. J.* 23(6), 813–817 (2004).
16. Ono R, Suemasu K, Matsunaka T. Bronchoscopic ultrasonography for diagnosis of lung cancer. *Jpn J. Clin. Oncol.* 23, 34–40 (1993).
17. Endobronchial ultrasound. *Respiration* 70(2), 179–194 (2003).
18. Herth F, Ernst A, Becker HD. Endobronchial ultrasound in therapeutic bronchoscopy. *Eur. Respir. J.* 20(1), 118–121 (2002).
19. Kurimoto N. M. Murayama, K. Morita *et al.* Assessment of usefulness of endobronchial ultrasonography in determination of depth of tracheobronchial tumor invasion. *Chest* 115, 1500–1506 (1999).
20. Herth F, Becker HD. EBUS for early cancer detection. *J. Bronchol.* 10, 249–253 (2003).
21. Miyazu Y, Miyazawa T, Iwamoto Y, Kano K, Kurimoto N. The Role of Endoscopic Techniques, Laser-Induced Fluorescenc Endoscopy, and Endobronchial Ultrasonography in Choice of Appropriate Therapy for bronchial Cancer. *J. Bronchol.* 8, 10–16 (2001).
22. Baba M, Sekine Y, Suzuki M *et al.* Correlation between endobronchial ultrasonography (EBUS) images and histologic findings in normal and tumor-invaded bronchial wall. *Lung Cancer* 35(1), 65–71 (2002).
23. Herth F, Ernst A, Becker HD. Endobronchial Ultrasound (EBUS) guided transbronchial lung biopsy (TBBX) in solitary pulmonary nodules and peripheral lesions. *Eur. Respir. J.* 20, 972–975 (2002).
24. Usefulness of endobronchial ultrasonography for transbronchial lung biopsies of peripheral lung lesions. *Respiration* 71(3), 260–268 (2004).
25. Analysis of the internal structure of peripheral pulmonary lesions using endobronchial ultrasonography. *Chest* 122(6), 1887–1894 (2002).
26. Herth FJ, Ernst A, Schulz M, Becker HD. Endobronchial Ultrasound Reliably Differentiates Between Airway Infiltration and Compression by Tumor. *Chest* 123, 458–462 (2003).
27. Shannon JJ, Bude RO, Orens JB *et al.* En-dobronchial Ultrasound-Guided Needle Aspiration of Mediastinal Adenopathy. *Am. J. Respir. Crit. Care Med.* 153, 1424–1430 (1996).
28. Herth FJ, Becker HD, Ernst A. Ultrasound-Guided Transbronchial Needle Aspiration: An Experience in 242 Patients. *Chest* 123, 604–607 (2003).
29. Herth F, Becker HD, Ernst A. Conventional vs Endobronchial Ultrasound-Guided Transbronchial Needle Aspiration: A Randomized Trial. *Chest* 125(1), 322–325 (2004).
30. Herth FJE, Lunn W, Eberhardt R, Becker HD, Ernst A. Transbronchial vs. Transesophageal Ultrasound-Guided Aspiration of Enlarged Mediastinal Lymph Nodes. *Am. J. Respir. Crit. Care Med.* (2005)
31. Krasnik M, Vilmann P, Larsen SS, Jacobsen GK. Preliminary experience with a new method of endoscopic transbronchial real time ultrasound guided biopsy for diagnosis of mediastinal and hilar lesions *Thorax* 58, 1083–1086 (2003).
32. Yasufuku K, Chhajed PN, Sekine Y *et al.* Endobronchial ultrasound using a new convex probe: a preliminary study on surgically resected specimens. *Oncol. Rep.* 11(2), 293–296 (2004).
33. Yasufuku K, Chiyo M, Sekine Y, Chhajed PN, Shibuya K, Iizasa T, Fujisawa T. Real-time Endobronchial Ultrasound-Guided Transbronchial Needle Aspiration of Mediastinal and Hilar Lymph Nodes. *Chest* 126, 122–128 (2004).
34. LeBlanc JK, Devereaux BM, Imperiale T *et al.* Endoscopic Ultrasound in Non-Small cell lung cancer and negative Mediastinum on computed tomography. *Am. J. Respir. Crit. Care Med.* 171, 177–182 (2005).

Affiliations

Felix JF Herth
 Thoraxklinik am Universitätsklinikum,
 Department of Internal Medicine, Pneumology
 and Critical Care,
 Thoraxklinik Heidelberg, Germany
 Ralf Eberhardt
 Thoraxklinik am Universitätsklinikum,
 Department of Interdisciplinary Endoscopy
 Thoraxklinik Heidelberg, Germany