

# Surgical treatment of congenital brachymetatarsia

HS Gong, MS Chung  
& Goo Hyun Baek<sup>†</sup>

<sup>†</sup>Author for correspondence  
Seoul National University  
College of Medicine,  
Department of Orthopedic  
Surgery, 28 Yongon-dong,  
Chongno-gu,  
Seoul 110-744, Korea  
Tel.: +82 220 722 368  
Fax: +82 2764 2718  
ghbaek@snu.ac.kr

**Introduction:** Congenital brachymetatarsia is a relatively rare condition that concerns metatarsal bone shortening. The aim of this retrospective study was to assess the surgical outcome of various forms of congenital brachymetatarsia treated by using our protocol.

**Patients & methods:** A total of 69 metatarsals in 44 patients with single or multiple congenital brachymetatarsia were included in the study. When a single ray was affected in a foot, we performed a one-stage lengthening using an intercalary autogenous iliac bone graft. When multiple rays were affected in one foot, we performed a one-stage combined shortening and lengthening procedure without an iliac bone graft. If intraoperative distraction of the metatarsal could not achieve satisfactory toe-tip parabola, concomitant proximal phalangeal lengthening was performed. The mean follow up was 3.5 (1.5–9) years.

**Results:** All patients were satisfied with the cosmetic and functional results. The average length gain by one-stage lengthening in 56 metatarsals was 14 (6–21) mm. Six patients with a combined shortening procedure regained a nearly normal parabola of the involved foot. No case was complicated by subsequent neurovascular impairment. **Conclusion:** Our experience suggests that satisfactory results can be achieved for the treatment of patients with congenital brachymetatarsia, if surgical options are carefully individualized concerning the patient's expectation and general foot appearance.

Congenital brachymetatarsia is a relatively rare clinical condition that involves the shortening of metatarsal bone due to premature epiphyseal closure. The fourth metatarsal is most commonly involved, although any or multiple metatarsals can be affected. The condition has a strong female predominance with a reported female to male ratio of 98:4 [1]. The deformity may cause pain because of an altered metatarsal parabola. However, cosmesis is the major concern among young women.

Many surgical techniques have been described for the correction of brachymetatarsia, since an autogenous bone graft from the calcaneus was first reported in 1969 [2]. The most widely used skeletal lengthening procedures are; one-stage lengthening with an intercalary bone graft [1–3], and gradual lengthening by callostasis [4–6]. Each method has its advantages and disadvantages. The advantages of one-stage lengthening over gradual lengthening include a shorter period to bony union, reduced scarring, and less morbidity. The disadvantages of the one-stage procedure include donor-site morbidity after a bone graft, a smaller gain in length and more neurovascular complications caused by rapid stretching [7,8]. The main advantage of gradual lengthening by callostasis is that it does not require a bone graft, and that it allows early weight bearing and has

fewer neurovascular complications. The possible disadvantages of callostasis include stiffness of the metatarsophalangeal joint, scars or hyperpigmentation around pin sites, a longer time for union and the discomfort associated with attaching an external fixator for an extended period [9,10]. Sometimes a shortening osteotomy of the adjacent metatarsal can be performed to restore a normal metatarsal parabola and a cosmetically acceptable foot appearance [11–14].

When assessing a patient with brachymetatarsia, numerous variables should be considered, including the number and sites of the rays affected, the amount of lengthening, the method of lengthening and fixation, and so on [15]. Our approach to treat this deformity is to classify patients first by the number of affected rays, and then by the amount of required lengthening. The purpose of this study was to evaluate the surgical outcome of congenital brachymetatarsia treated according to our protocol.

## Patients & methods

### Subjects & treatment protocol

We reviewed 69 cases of congenital brachymetatarsia in 44 patients, which we had treated according to our protocol between 1989 and 2002. All patients were female and their average age was 16

**Keywords:** combined shortening and lengthening, congenital brachymetatarsia, one-stage lengthening



Future Drugs Ltd

(8 to 36) years. All complained of an unsightly short toe(s), and twelve patients experienced mild occasional pain in adjacent metatarsal heads when walking of which two had plantar callosities and four had associated bilateral brachymetatarsia. The main indication for surgery was cosmetic, but patient selection for surgical treatment was made when the patient fully comprehended the expected results and possible complications. Surgery was not considered if the patient had not reached skeletal maturity due to possible physeal injury related with lengthening, or if the patient had an unrealistic expectation of the results.

We first categorized those patients with congenital brachymetatarsia into single- or multiple-ray involvements and then grouped them by the amount of lengthening required. When a single ray was involved in a foot, we performed a one-stage lengthening with an intercalary autogenous iliac bone graft. The amount of required lengthening was a next consideration, that is, concomitant proximal phalangeal lengthening was planned if the measured target length was rather large (usually more than 40% of the metatarsal length). Actually, this additional proximal phalangeal lengthening was decided during the operation, if intraoperative gradual distraction of the metatarsal could not achieve satisfactory toe-tip parabola. When multiple rays were involved in the same foot, we performed a one-stage combined shortening and lengthening procedure without an iliac bone graft, if the patient agreed to a general shortening of the toes. Additional proximal phalangeal lengthening using an intercalary iliac bone graft was also performed in this combined procedure if the new metatarsal parabola could not produce satisfactory toe-tip parabola. If the patient refused to accept shortening of normal rays, we could choose either one-stage lengthening or gradual lengthening by callosities in all affected rays. However, all patients with multiple-ray involvement accepted the combined procedure. The mean follow up was 3.5 (1.5 to 9) years.

#### *Treatment of single-ray brachymetatarsia*

Sixty-eight one-stage skeletal lengthening procedures (56 metatarsals and 12 proximal phalanges) were performed in 38 patients by means of intercalary autogenous bone grafting to treat congenital brachymetatarsia affecting a single ray of the foot. To achieve the target toe length, 12 proximal phalanges were lengthened

concomitantly with the metatarsal of the same ray. Involvement was unilateral in 20 patients and bilateral in 18. Most of the affected metatarsal was the fourth toe, and only one patient with unilateral involvement and two with bilateral involvement had isolated shortening of the first metatarsal.

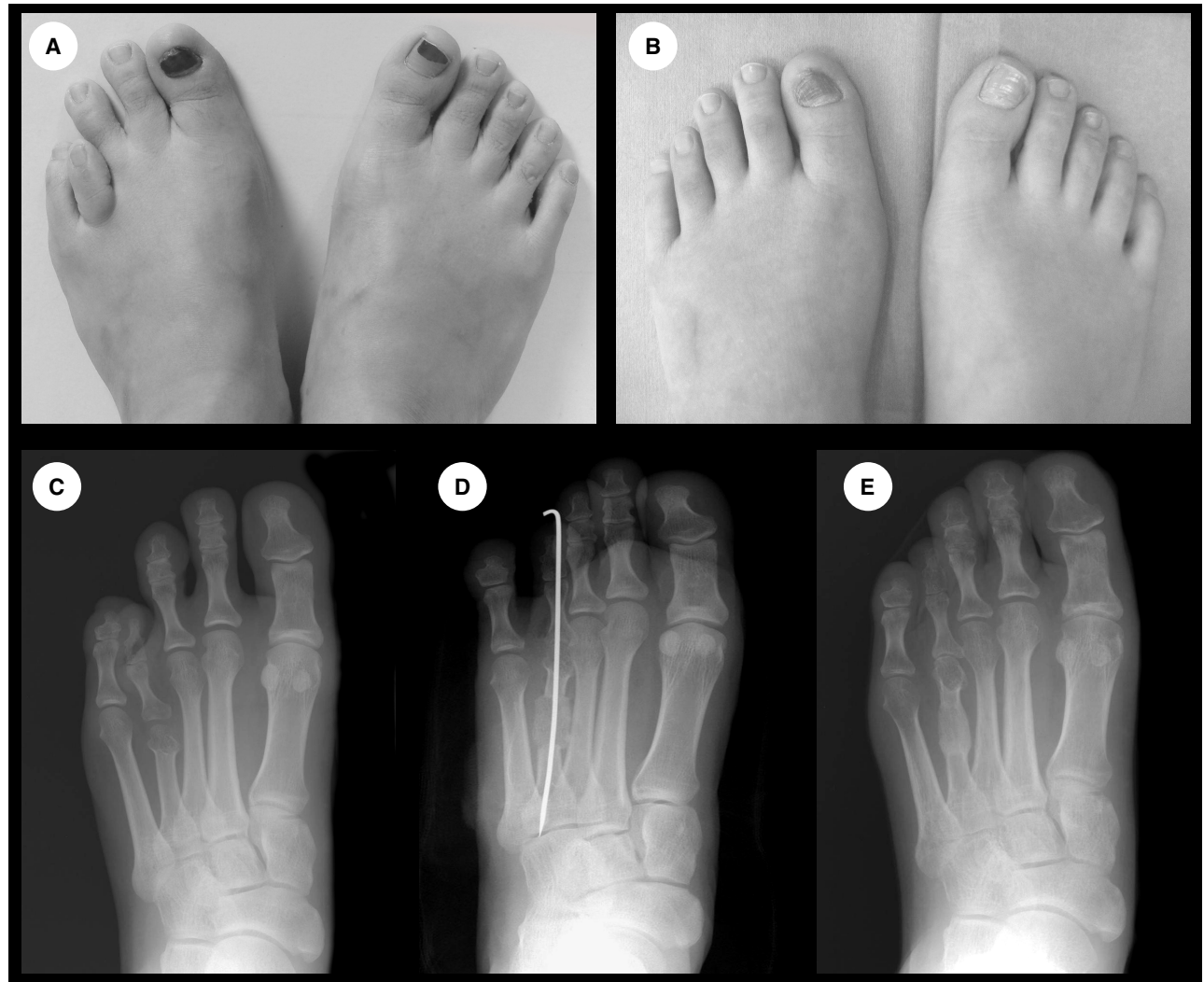
We performed the one-stage lengthening using intercalary bicortical iliac bone as described by Baek and Chung [16]. The osteotomy site was gradually distracted using an Inge bone spreader for about 20 to 30 min to reduce soft-tissue tension. When the amount of distraction was not enough, adjacent deep transverse metatarsal ligaments were cut. This procedure could easily increase several millimeters of further distraction. Between 8 and 10 weeks after surgery, the cast and K-wire were removed, and 12 weeks postoperatively, when radiology showed union was solid, full weight bearing was permitted. The procedure used for proximal phalanx lengthening was similar (Figure 1).

#### *Treatment of multiple-ray brachymetatarsia*

A total of six patients with congenital brachymetatarsia of the first and one or two other metatarsals were treated by a one-stage combined shortening and lengthening procedure [14] using an intercalary autogenous bone graft from an adjacent metatarsal (Figure 2). In all patients, multiple metatarsals were involved bilaterally, five patients had short first and fourth metatarsals and one had short first, fourth and fifth metatarsals. Every patient that received the combined procedure was informed and consulted preoperatively about operation on normal rays, and agreed to accept toe shortening. All operations were performed bilaterally and postoperative management was the same as for one-stage lengthening.

#### **Results**

For one-stage lengthening for single ray involvement, the average length gain and corresponding percentage increase of 68 bones, including 56 metatarsals and 12 proximal phalanges, were 13 (5–21) mm and 33 (11–65)% respectively. In 56 metatarsal lengthening procedures, length-gain averaging 14 (6–21) mm was obtained, which was equivalent to an increase of 32 (11–51%). The corresponding figures for the 12 proximal phalangeal lengthening procedures were 8 (5–11) mm and 54 (47 to 65%). For the one-stage combined shortening and lengthening procedures for 13 metatarsals and three proximal phalanges

**Figure 3. A 22-year-old woman with brachymetatarsia of the left fourth toe.**

A 22-year-old woman with brachymetatarsia of the left fourth toe before **(A)** and 1 year after operation **(B)**. The radiographs show an anteroposterior view before operation **(C)** after one-stage lengthening with an intercalary iliac bone graft **(D)** and 1 year after operation **(E)**.

principal goal of treatment was to obtain a good cosmetic result with restoration of a functional metatarsal parabola.

When we evaluated patients with this deformity, we considered the number of affected rays first, and then the amount of required lengthening. In cases of single ray involvement, we always tried to restore the normal length of the metatarsal. Kim and colleagues reported that shortening of an adjacent bone reduced target length and enabled them to carry out a one-stage lengthening instead of gradual distraction [15]. However, in almost all our cases of single ray involvement, we were able to lengthen the metatarsal by one-stage lengthening with intercalary bone graft

without neurovascular impairment. If longer lengthening was required, we were able to restore normal ray length with concomitant proximal phalangeal lengthening without functional impairment, and gradual lengthening with callus distraction was not necessary. We believe that when only one ray is affected, shortening of a normal ray should be weighed carefully against the complications that may occur.

Proximal phalangeal lengthening was effective to get a cosmetic (toe-tip) parabola, when intra-operative gradual distraction of the metatarsal could not achieve a satisfactory ray length. Although it is ideal to accomplish both metatarsal and toe-tip parabolas, we think that toe-tip

parabola is more important than metatarsal head parabola to the patients, as most of them have no pain or functional problem with their disturbed metatarsal head parabola preoperatively and their concern is mainly cosmesis.

Intraoperative gradual distraction using the phenomenon of creep and stress relaxation has been found sufficient to gain up to 21 mm of lengthening [16]. Additionally, we found that cutting the adjacent deep transverse metatarsal ligaments were effective to gain more soft tissue release without noticeable adverse effects. Gradual lengthening by callotaxis can use more creep and stress relaxation than intraoperative gradual distraction, however, according to Choi and colleagues [17] who conducted a comparative study of one-stage lengthening and lengthening by callotaxis, the overall radiologic and clinical results of the two methods were found to be comparable in terms of length gain, complications, cosmesis and patient satisfaction. The only statistical difference was the time period required to achieve bony consolidation, which was shorter for the one-stage lengthening method. So we believe that one-stage lengthening with intercalary bone graft is the better choice unless multiple or longer lengthening is required.

The surgical procedure for single first metatarsal lengthening was not different from fourth ray. Despite we don't have enough data, we think that the first ray lengthening should be aimed to achieve less than the ideal target length, because the first metatarsophalangeal joint has intrinsic potential of deviation or subluxation, with only one adjacent ray. Kim and colleagues [15] insisted

that postoperatively, shorter metatarsal was preferable to metatarsals equal to or longer than the second, in order to reduce complications associated with excessive bone lengthening.

When multiple rays are short, one-stage lengthening with an autogenous iliac bone graft would require a large amount of bicortical bone to recreate the normal parabola, and thus cause more donor-site morbidity and additional scarring, and it might be associated with the neurovascular compromise due to increased soft tissue tension. On the other hand, callus distraction requires an increased cost and time, the placement of multiple external fixators and an extended lengthening time. Therefore, we addressed patients with multiple affected rays by using a combined shortening and lengthening procedure, and used one incision, which reduced scarring. The incidence of bilaterality has been reported to be high in this deformity, i.e., up to 72% [1], and all of our patients with multiple brachymetatarsia were involved bilaterally. Since they were operated on both feet simultaneously, they were satisfied with their shortened, but symmetrical feet.

Usually no iliac bone graft was required for one-stage combined shortening and lengthening. The excised bone from the adjacent metatarsal was sufficient to achieve the target length, and union was not delayed versus corticocancellous iliac bone grafting. When we took a bicortical iliac bone graft in single metatarsal lengthening, we filled the defect with artificial bone, e.g., Lubbock (OST Development, France). Careful taking of the bicortical bone graft from the inner cortex of the pelvis usually does not cause much disturbance of the contours of the iliac crest, but we have experienced some patients complaining of the dimpling over the crest, especially when a long bicortical bone (usually about 4 cm size) was taken for bilateral single-ray cases. Our experience showed that the artificial bone available in the rectangular shape could maintain the contour effectively.

## Outlook

The treatment of congenital brachymetatarsia can sometimes be difficult and many complications can occur during or after operation. However, if the surgical option is carefully tailored to meet a patient's expectation and general foot appearance, satisfactory results can be expected for the management of congenital brachymetatarsia.

## Highlights

- We conducted a retrospective study to assess the surgical outcome of congenital brachymetatarsia treated using our protocol.
- When a single ray was involved in a foot, we performed one-stage lengthening using an intercalary autogenous iliac bone graft. Concomitant proximal phalangeal lengthening was done, if intraoperative gradual distraction of the metatarsal could not achieve satisfactory toe-tip parabola.
- When multiple rays were involved in the same foot, we performed a one-stage combined shortening and lengthening without iliac bone graft, to restore functional metatarsal parabola. Additional proximal phalangeal lengthening using an intercalary iliac bone graft was performed if the newly-formed metatarsal parabola could not produce satisfactory toe-tip parabola.
- From our experiences, satisfactory results can be achieved in treating patients with congenital brachymetatarsia, by carefully individualizing the surgical approach to meet a patient's expectation and general foot appearance.

**Bibliography**

1. Urano Y, Kobayashi A. Bone-lengthening for shortness of the fourth toe. *J. Bone Joint Surg.* 60, 91–93 (1978).
2. McGlamry ED, Cooper CT. Brachymetatarsia: a surgical treatment. *J. Am. Psycho. Anal.* 59, 259–264 (1969).
3. Marcinko D, Rappaport M, Gordon S. Post-traumatic brachymetatarsia. *J. Foot Surg.* 23, 451–453 (1984).
4. Ferrandez L, Yubero J, Usabiaga J, Ramos L. Congenital brachymetatarsia: Three cases. *Foot Ankle* 14, 529–533 (1993).
5. Kawashima T, Yamada A, Ueda K, Harii K: Treatment of brachymetatarsia by callus distraction (Callotasis). *Ann. Plast. Surg.* 32, 191–199 (1994).
6. Masuda T, Matoh N, Nakajima T, Tomi M, Ohba K. Treatment of brachymetatarsia using a semicircular lengthener. 1–3 years results in 6 patients. *Acta Orthop. Scand.* 66, 43–46 (1995).
7. McGlamry ED, Banks AS, Downey MS. In: *Comprehensive Textbook of Foot Surgery*. Vol. 2, Second ed. Baltimore: Williams and Wilkins 1211–1231 (1992).
8. Takakura Y, Tanaka T, Fujii T, Tamai S. Lengthening of short great toes by callus distraction. *J. Bone Joint Surg.* 79, 955–958 (1997).
9. Masada K, Fujita S, Fuji T, Ohno H. Complications following metatarsal lengthening by callus distraction for brachymetatarsia. *J. Pediatr. Orthop.* 19, 394–397 (1999).
10. Wada A, Bensahel H, Takamura K, Fujii T, Yanagida H, Nakamura T. Metatarsal lengthening by callus distraction for brachymetatarsia. *J. Pediatr. Orthop.* 13, 206–210 (2004).
11. Fox IM. Treatment of brachymetatarsia by the callus distraction method. *J. Foot Surg.* 37, 391–395 (1998).
12. Goforth WP, Overbeek TD. Brachymetatarsia of the third and fourth metatarsals. *J. Am. Podiatr. Assoc.* 91, 373–378 (2001).
13. Handelman RB, Perlman MD, Coleman WB. Brachymetatarsia: a review and case report. *J. Am. Podiatr. Assoc.* 76, 413–416 (1986).
14. Kim JS, Baek GH, Chung MS, Yoon PW. Multiple congenital brachymetatarsia. A one stage combined shortening and lengthening procedure without iliac bone graft. *J. Bone Joint Surg.* 86, 1013–1015 (2004).
15. Kim HT, Lee SH, Yoo CI, Kang JH, Suh JT. The management of brachymetatarsia. *J. Bone Joint Surg.* 85, 683–690 (2003).
16. Baek GH, Chung MS: The treatment of congenital brachymetatarsia by one-stage lengthening. *J. Bone Joint Surg.* 80, 1040–1044 (1998).
17. Choi IH, Chung MS, Baek GH, Cho TJ, Chung CY. Metatarsal lengthening in congenital brachymetatarsia: one-stage lengthening versus lengthening by callosostasis. *J. Pediatr. Orthop.* 19, 660–664 (1999).

**Affiliations**

*H S Gong, MD*

*Seoul National University*

*College of Medicine,*

*Department of Orthopedic Surgery,*

*28 Yongon-dong, Chongno-gu,*

*Seoul 110–744, Korea*

*M S Chung, MD*

*Seoul National University*

*College of Medicine,*

*Department of Orthopedic Surgery,*

*28 Yongon-dong, Chongno-gu,*

*Seoul 110–744, Korea*

*Goo Hyun Baek, MD*

*Seoul National University*

*College of Medicine,*

*Department of Orthopedic Surgery,*

*28 Yongon-dong, Chongno-gu,*

*Seoul 110–744, Korea*

*Tel.: +82 220 722 368*

*Fax: +82 2764 2718*

*ghbaek@snu.ac.kr*