

# Skin biopsy as a routine diagnostic tool for primary Sjögren's syndrome

Sjögren's syndrome is an autoimmune disease characterized by disruption of epithelial cells and lymphoplasmocytic infiltration of exocrine glands throughout the body, mainly salivary and lacrimal glands. The lymphocytic infiltrates in the minor salivary gland biopsy and the presence of autoantibodies are the gold standards for diagnosis. However, skin dryness is often underestimated. In addition, skin biopsy of patients with Sjögren's syndrome may have lymphocytic infiltrates, and some patients with nonconclusive minor salivary glands may present infiltrates in the skin. We propose to add the question of skin dryness to the symptoms questionnaire designed for patients presenting clinical features of Sjögren's syndrome and to perform skin biopsy as a routine tool in the diagnosis of Sjögren's syndrome, especially in patients with nonconclusive minor salivary glands. The emergence of new and potentially active treatments, most notably anti-B lymphocyte monoclonal antibodies, may conduct to the use of skin biopsy instead of salivary gland biopsy in their follow-up.

**KEYWORDS:** B lymphocyte ■ memory B lymphocyte ■ Sjögren's syndrome ■ skin biopsy ■ xerosis

## Definition of primary Sjögren's syndrome

Sjögren's syndrome (SS) is an autoimmune and multifaceted condition with a broad variety of clinical manifestations and biological abnormalities [1]. This enormous polymorphism is associated with the delay in the diagnosis. This disease is characterized by disruption of epithelial cells and lymphoplasmocytic infiltration of exocrine glands throughout the body, mainly salivary and lacrimal glands [2]. The consequences of SS, such as xerostomia and xerophthalmia, reflect the loss of secretory ability. SS can present alone as primary SS (pSS) or accompanying other autoimmune diseases, as secondary SS.

Faced with the ever-growing complexity of criteria for classification of patients [3], physicians with an interest in pSS have continued to devise new tests. In particular, the skin may function as a diagnostic window on the diseases affecting internal organs and other exocrine tissues.

## ■ Dermatologic clinical manifestations of pSS

Cutaneous manifestations of SS include xerosis, immunologic inflammatory manifestations such as vasculitis and other manifestations such as angular cheilitis, eyelid dermatitis and annular erythema [4,5].

Vascular manifestations include flat and palpable purpura, neutrophilic inflammatory vascular disease indistinguishable from leukocytoclastic

vasculitis, mononuclear inflammatory vascular disease and urticarial vasculitis [6].

Xerosis is a common skin manifestation in pSS characterized by roughness, scaling, loss of elasticity and often discomforting sensations of itching and burning [7]. However, this manifestation is underestimated in the clinical follow-up of pSS. The presence of xerosis varies in different series from 23 to 65%. For example, 42 of 62 patients (67%) described by Bloch *et al.* [8] presented cutaneous dryness and 17 patients complained of a decreased sweating; whereas Whaley *et al.* reported only 23% prevalence of xerosis in 171 patients with pSS [9]. An analysis conducted retrospectively by Bernacchi *et al.* showed that xerosis was more frequent in pSS (43%) compared with the secondary form of the disease (26%) [4]. Because xerosis is subjective and often associated with more demanding symptoms, this manifestation can be neglected, which could explain such different results in the prevalence. TABLE 1 shows the percentage of xerosis in different series of pSS and secondary SS. In our recent study 22 pSS patients had a higher score for skin dryness on the visual analogue scale compared with 22 healthy controls ( $58.3 \pm 10.1$  vs  $38.9 \pm 7.6$ ;  $p < 0.01$ ) [10]. Although not reported spontaneously, xerosis was more common in patients (9/22) versus controls (2/22). It seems that clinical xerosis is not associated with other extraglandular manifestations or immunological parameters [4,10].

Gabriel J Tobón<sup>1,2</sup>,  
Anne-Marie Roguedas<sup>3</sup>,  
Laurent Misery<sup>3</sup>,  
Pierre Youinou<sup>1</sup>  
& Jacques-Olivier Pers<sup>\*1</sup>

<sup>1</sup>EA2216, IFR148, Brest University,  
European University in Brittany,  
Brest, France

<sup>2</sup>Division of Clinical Immunology  
& Rheumatology, Fundación Valle del  
Lili, Cali, Colombia

<sup>3</sup>Department of Dermatology, Brest  
University Medical School Hospital,  
Brest, France

\*Author for correspondence:

Tel.: +33 298 223 384

Fax: +33 298 223 847

pers@univ-brest.fr

future  
medicine part of fsg

Table 1. Xerosis in primary Sjögren's syndrome.

Author	n	Frequency of xerosis (%)	Ref.
Markusse <i>et al.</i>	46 primary	56	[36]
Bloch <i>et al.</i>	62 (23 primary)	67	[8]
Whaley <i>et al.</i>	171	23	[9]
Bernacchi <i>et al.</i>	93 (62 primary and 31 secondary)	56 primary and 26 secondary	[4]
Roguedas <i>et al.</i>	22 primary	40	[10]

The understanding of xerosis is not completely clear. This condition may be due to infiltrate of the eccrine or sebaceous glands or dysfunctional sweating.

Initially, it has been suggested that xerosis in pSS may be due to decreased eccrine sweating. Katayama *et al.* evaluated sweating in 49 patients with pSS [11]. Sweating was induced by mental stimulation such as deep breathing or hand grasping, and was evaluated in controls and patients with other types of dermatitis (atopic dermatitis, psoriasis vulgaris and senile xerosis). A perspirometer continuously recorded sweat volume. Sweating was reported to be significantly reduced in pSS ( $p < 0.005$ ). This result suggested that patients with pSS develop impaired sweating as an exocrine manifestation in addition to xerostomia and xerophthalmia.

In one study, Bernacchi *et al.* conducted a histopathological and functional evaluation of xerotic skin in pSS [7]. Skin barrier function was evaluated by corneometry and evaporimetry to detect stratum corneum water content and transepidermal water loss. In the deltoid area transepidermal water loss values were significantly lower in pSS patients compared with controls ( $p = 0.037$ ). No morphological alterations or reduction in number of sebaceous and sweat glands were demonstrated. On the contrary, four samples from pSS patients selected for immunohistochemical analyses showed a marked staining with Ki67 antibody on the basal and spinous layers. In addition, the final phase of keratinocyte differentiation also appeared altered in pSS patients, with expression of involucrin not only in the granulous, but also in the highest part of the spinous layer. The authors conclude that xerosis in pSS was not related to a chronic inflammatory atrophy of sweat glands, although some biochemical alterations of epidermis (increase of epidermal proliferation and perturbation of epidermal differentiation) were present.

Xerosis could be due to the presence of inflammatory infiltrates in the skin. In a case report, Mitchell *et al.* described a 55-year-old

man with pSS who had experienced difficulty in perspiring [12]. The skin biopsy showed a moderate number of eccrine glands and ductal structures in the reticular dermis and the presence of lymphocytes and plasma cells heavily infiltrating the epithelial structures. Eccrine sweat testing was performed by intradermal injection of 0.1 ml of 1:500 metacholine in sterile saline solution and the visualization of sweating was facilitated by bromophenol blue powder. Very few scattered dots were identified, suggesting a marked decrease in eccrine sweating. Whaley *et al.* performed skin biopsy in seven patients, showing a chronic inflammatory process destroying the sweat glands [9]. A nonspecific perivascular lymphocytic infiltrate was also found.

In conclusion, xerosis may be due to biochemical alterations in association with lymphoplasmocytic infiltrates in sweat glands of patients with pSS. In some cases, a chronic inflammatory phenomenon leading to the destruction of sweat glands has been described. Reciprocally, xerosis is common with age in the elderly. Thus, the diagnosis of pSS warrants consideration in elderly patients referred to the dermatologist in order to investigate the etiology of dry skin.

#### ■ Utility of skin biopsy in the diagnosis of pSS

Recently, we have shown the utility of skin biopsy as a routine diagnostic tool in pSS [10]. This study was developed in 22 pSS patients, diagnosed by minor salivary gland (MSG) biopsy and auto-antibodies anti-Ro and/or anti-La, according to the American-European Consensus Group criteria [3]. Of these 22 patients, we disposed of 12 skin biopsies. Axillae region were ideal for the 6-mm punch biopsies of noninvolved skin, given the concomitance of eccrine, apocrine and apoecrine sweat glands [13]. Lymphocytic infiltrates were found in 8 of 12 skin samples (66%). The most important finding was that two patients with noncontributive MSG biopsy had skin infiltrates (FIGURE 1A). By contrast, ten

skin samples from matched healthy volunteers were absolutely devoid of lymphocytes. This result shows that MSG and skin biopsies may be complementary in the study of sicca symptoms and the diagnosis of pSS.

The discrepancy between the results of MSG and skin biopsies in pSS patients is not really surprising, since the extent of lymphocyte infiltrates varies between the fields in one MSG sample, between MSG in one biopsy, and between MSG samples in one patient over time [14–19].

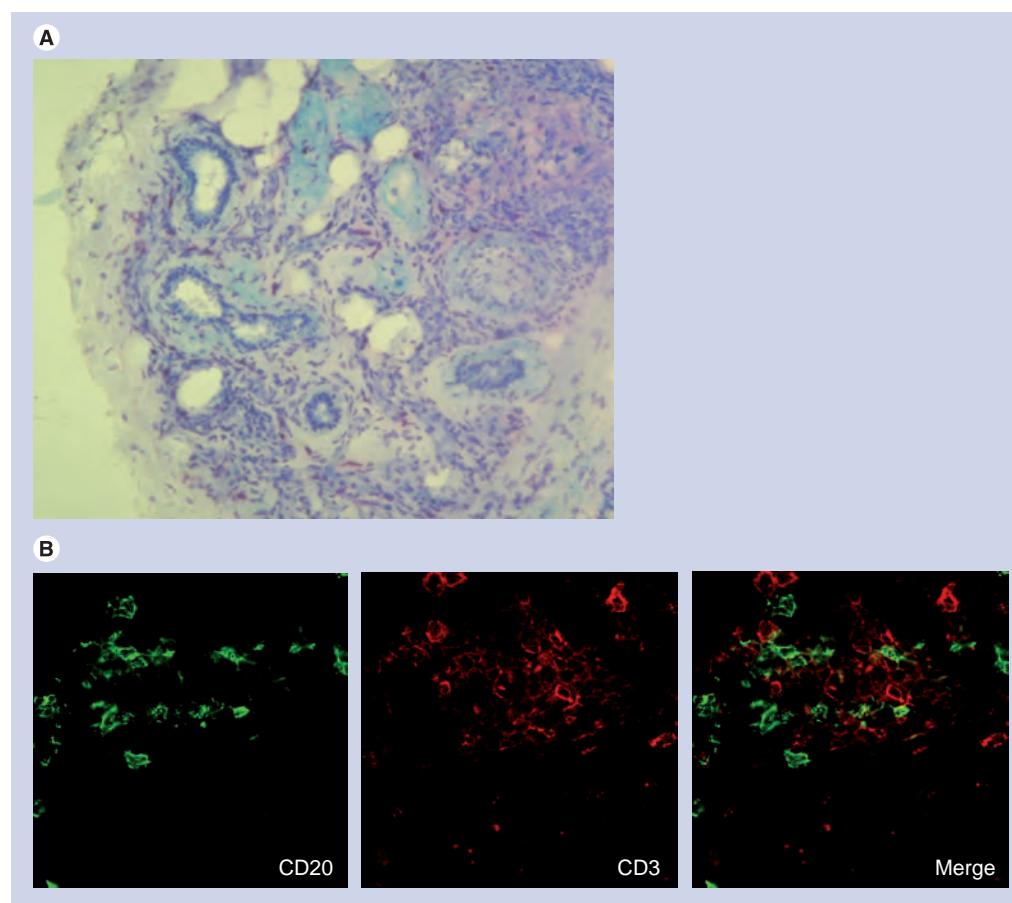
The skin biopsy may serve as an additional factor for the diagnosis of pSS, with supplemental importance in patients with repeatedly negative MSG biopsies. Although MSG biopsy remains the histopathological gold standard for SS diagnosis, some authors hold strong reservations regarding this biopsy, arguing that: this site is nonspecific; and exocrine atrophy is normal as a part of the ageing process. Thus, lymphocytic infiltrates were found in 15% of healthy controls [20]. In addition, some patients present

some distressing sensory neuropathy in a portion of the mental dermatome, whereas the morbidity of skin biopsy is particularly low.

#### ■ Histological findings in skin biopsy

Within the cutaneous infiltrates, T and B cells have been described (FIGURE 1B). Most of the T lymphocytes, defined by the membrane expression of CD3, were positive for CD4 and negative for CD8. B-cell characterization (CD20<sup>+</sup>) showed only 1% CD5-expressing cells, which is a marker for polyspecific autoantibody-producing B lymphocytes. Unexpectedly, B cells were CD27<sup>+</sup>/IgD<sup>+</sup>, which are markers of memory B cells. Some B cells were also CD24<sup>+</sup> immature B cells, resembling transitional B cells.

Assuming that homing receptors for the epidermis are specific for T lymphocytes [21], the migration of B lymphocytes to the skin may be unlikely. The simplest explanation for their detection among the skin lymphocytes is that one of several of the B-lymphocyte chemotactic



**Figure 1. Pathological changes in the cutaneous tissue of patients with primary Sjögren's syndrome.** (A) Epidermis infiltrated with mononuclear cells stained with toluidine blue. (B) Immunofluorescence analysis of the same skin specimen (A) from a patient with primary Sjögren's syndrome shows CD20-positive B lymphocytes (left panel) and CD3-positive T lymphocytes (middle panel) (magnification:  $\times 63$ ).

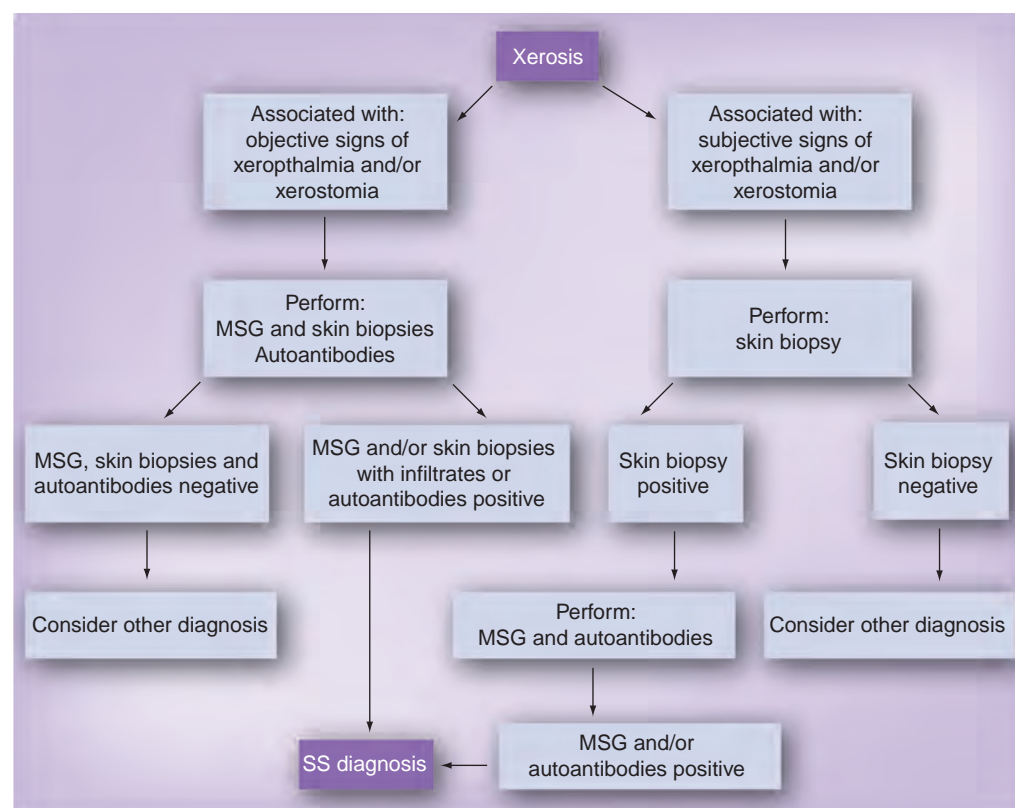
factors described in the MSG [22] are shared by all exocrine tissues. Consequently, these include also cutaneous sweat glands [23]. Furthermore, we were surprised by our finding that memory B lymphocytes infiltrate not only the MSG [24], but also the skin. The local production of B cell activating factor of the TNF family may explain this finding, and deserves further research. Retention of memory B cells in the exocrine tissues may account, at least in part, for their decrease in peripheral blood. CD5-expressing B cells are not reported to generate memory B cells [25], which is consistent with their absence in the B-cell infiltrates from the skin. Among memory B cells, some harbor the CD20<sup>+</sup>/CD24<sup>+</sup> profile, already described in the salivary glands [26], which is in fact closer to that of transitional type 2 B cells than to that of marginal-zone B cells.

Given the ability of T cells, but not conventional B cells, to home specifically to and reside preferentially in healthy, as well as in inflammatory [27] or malignant [28] skin, our finding that B lymphocytes contribute to the cutaneous infiltrate was highly unexpected. This is, nonetheless, consistent with the hypothesis that B cells play a central role in the pathogenesis of pSS [29,30]. Thus, the presence of B lymphocytes

in the skin biopsy might alert the dermatologist on a routine basis, and be regarded as a clue for the diagnosis of pSS.

#### ■ Alternative tools for pSS diagnosis

B-cell alterations are important in pSS pathogenesis [29,30]. Among major breakthroughs in B-cell abnormalities is the dissection of B-lymphocyte subsets. The subsets of mature B cells (Bm) are defined according to the respective membrane expression of IgD and CD38 into sequential stages from Bm1 through Bm5 [31]. Patients with pSS show a high ratio of increased percentages of blood Bm2/Bm2' cells to decreased percentages of eBm5/Bm5 cells in peripheral blood, compared with other autoimmune diseases and healthy controls [32]. This phenomenon is accompanied by the accumulation of memory B cells in the exocrine glands [33], which was also observed in skin infiltrates in pSS. This ratio, more readily available to the community physician than the MSG biopsy, could provide a new additional criterion for pSS [34]. In combination with skin biopsy, these two criteria may be useful as alternative criteria for the pSS diagnosis. However, an additional evaluation in a multicenter prospective study is needed.



**Figure 2. Proposed flow chart including skin biopsy in Sjögren's syndrome diagnosis.** MSG: Minor salivary glands; SS: Sjögren's syndrome.



### Future perspective

Our clinical recommendation is that skin biopsy may be useful as a tool for the pSS diagnosis. This affirmation is more interesting in the case of noncontributive MSG biopsy. In our previous study, two patients presented skin infiltrates, with normal MSG biopsy. In addition, punch skin biopsy taken in the axillae region is harmless and easy to take at the clinical office. The view that any exocrine glands are at risk of undergoing the autoimmune assault connotes that the examination of sweat glands could contribute to the histopathological diagnosis. The emergence of new and potentially active treatments [35], most notably anti-B lymphocyte monoclonal antibodies, may lead to the use of skin biopsy instead of labial salivary gland biopsy in their follow-up.

In clinical practice, the skin of patients suspected of pSS must be carefully examined and, one step further, the epidermis should be evaluated to search for B-cell infiltrates. In FIGURE 2, we proposed a diagnostic flow chart that includes

skin biopsy as a possible tool for the diagnosis of pSS. Xerosis may indeed constitute an early sign of pSS before the onset of xerostomia and xerophthalmia.

In conclusion, we propose to add the question of skin dryness to the symptoms questionnaire designed for patients presenting clinical features suggesting SS. In addition to the MSG biopsy, skin biopsy should be performed as part of the routine clinical care in these patients. The goal is to improve the diagnosis in early stages of SS.

### Financial & competing interests disclosure

*The authors have no relevant affiliations or financial involvement with any organization or entity with a financial interest in or financial conflict with the subject matter or materials discussed in the manuscript. This includes employment, consultancies, honoraria, stock ownership or options, expert testimony, grants or patents received or pending, or royalties.*

*No writing assistance was utilized in the production of this manuscript.*

### Executive summary

#### Definition of primary Sjögren's syndrome

- Sjögren's syndrome (SS) is an autoimmune and multifaceted condition with a broad variety of clinical manifestations and biological abnormalities.
- Xerostomia and xerophthalmia are the main clinical manifestations.
- Many other organs may be affected.

#### Skin disease as a manifestation in SS

- Xerosis is a common and underestimated manifestation in SS.
- The presence of xerosis varies in different series from 23 to 65%. Its prevalence seems higher in primary SS patients compared with secondary SS (43 vs 26%).
- Both biochemical alterations and lymphoplasmocytic infiltration of sweat glands may explain the presence of xerosis.

#### Skin biopsy as a routine tool for the diagnosis of primary SS

- Axillae region is ideal for 6-mm punch biopsies of noninvolved skin, given the concomitance of eccrine, apocrine and apoeccrine sweat glands.
- B- and T-cell infiltrates may be present in 66% of primary SS patients. A non-negligible number of patients have skin infiltrates with a minor salivary gland biopsy nonconclusive for the primary SS diagnosis.

#### Recommendations

- Skin symptoms must be investigated in patients with clinical suspicion of SS.
- Skin biopsy is a simple and safe test, and the results may help SS diagnosis, mainly in patients with nonconclusive minor salivary glands.

### Bibliography

Papers of special note have been highlighted as:  
▪ of interest

- 1 Chiorini JA, Cihakova D, Ouellette CE, Caturegli P: Sjögren's syndrome: advances in the pathogenesis from animal models. *J. Autoimmun.* 33, 190–196 (2009).
- 2 Moutsopoulos HM: Sjögren's syndrome: autoimmune epithelitis. *Clin. Immunol. Immunopathol.* 72, 162–165 (1994).
- 3 Vitali C, Bombardieri S, Moutsopoulos HM *et al.*: Classification criteria for Sjögren's syndrome. A revised version of the European

criteria proposed by the American-European Consensus Group. *Ann. Rheum. Dis.* 61, 554–558 (2002).

- 4 Bernacchi E, Amato L, Parodi A *et al.*: Sjögren's syndrome: a retrospective review of the cutaneous features of 93 patients by the Italian Group of immunodermatology. *Clin. Exp. Rheumatol.* 22, 55–62 (2004).
- Evaluated the cutaneous features of 93 patients with Sjögren's syndrome (SS). Patients were subdivided into primary and secondary SS. Xerosis and angular cheilitis were more prevalent in patients

with primary SS compared with secondary. The authors conclude that xerosis is the most frequent and characteristic cutaneous manifestation of primary SS.

- 5 Roguedas AM, Youinou P, Lemasson G *et al.*: Primary Gougerot-Sjögren syndrome: a dermatological approach. *J. Eur. Acad. Dermatol. Venereol.* 20, 243–247 (2006).
- 6 Albrecht J, Atzeni F, Baldini C *et al.*: Skin involvement and outcome measures in systemic autoimmune diseases. *Clin. Exp. Rheumatol.* 24, S52–S59 (2006).

- 7 Bernacchi E, Bianchi B, Amato L, Giorgini S, Fabbri P: Xerosis in primary Sjögren syndrome: immunohistochemical and functional investigations. *J. Dermatol. Sci.* 39, 53–55 (2005).
- 8 Bloch KJ, Buchanan WW, Whohl MJ: Sjögren's syndrome. A clinical, pathological and serological study of sixty-two cases. *Medicine (Baltimore)* 44, 187–231 (1965).
- 9 Whaley K, Williamson J, Chisholm DM, Webb J, Mason DK, Buchanan WW: Sjögren's syndrome. 1. Sicca components. *Q. J. Med.* 42, 279–304 (1973).
- 10 Roguedas AM, Pers JO, Lemasson G *et al.*: Memory B-cell aggregates in skin biopsy are diagnostic for primary Sjögren's syndrome. *J. Autoimmun.* 35, 241–247 (2010).
- **Found a higher proportion of xerosis in patients with primary SS compared with healthy controls. In addition, the axilla skin was analyzed by punch biopsy. Lymphocytic infiltration was seen in the skin of eight of the 12 patients tested. Two of them had normal salivary glands biopsy. Most interestingly, B-cell infiltrates were identified in skin infiltrates, so their presence might be a clue to the diagnosis of primary SS. B cells were memory B cells (CD27<sup>+</sup>) and immature B cells (CD20<sup>+</sup>/CD24<sup>+</sup>). The authors suggest that skin biopsies warrant inclusion into the routine clinical care of patients with suspected primary SS.**
- 11 Katayama I, Yokozeki H, Nishioka K: Impaired sweating as an exocrine manifestation in Sjögren's syndrome. *Br. J. Dermatol.* 133, 716–720 (1995).
- 12 Mitchell J, Greenspan J, Daniels T *et al.*: Anhidrosis in Sjögren's syndrome. *J. Am. Acad. Dermatol.* 16, 233–235 (1987).
- 13 Sato K, Leidal R, Sato F: Morphology and development of an apoeccrine sweat gland in human axillae. *Am. J. Physiol.* 252, R166–R180 (1987).
- 14 Leroy JP, Pennec YL, Letoux G, Youinou P: Lymphocytic infiltration of salivary ducts: a histopathologic lesion specific for primary Sjögren's syndrome? *Arthritis Rheum.* 35, 481–482 (1992).
- 15 Pijpe J, Kalk WW, van der Wal JE *et al.*: Parotid gland biopsy compared with labial biopsy in the diagnosis primary Sjögren's syndrome. *Rheumatology (Oxford)* 46, 335–341 (2007).
- 16 Pennec YL, Leroy JP, Jouquan J, Lelong A, Katsikis P, Youinou P: Comparison of labial and sublingual salivary gland biopsies in the diagnosis of Sjögren's syndrome. *Ann. Rheum. Dis.* 49, 37–39 (1990).
- 17 Scardina GA, Spanó G, Carini F *et al.*: Diagnostic evaluation of serial sections of labial salivary gland biopsies in Sjögren's syndrome. *Med. Oral Patol. Oral Cir. Bucal.* 12, E565–E568 (2007).
- 18 Morbini P, Manzo A, Caporali R *et al.*: Multilevel examination of minor salivary gland biopsy for Sjögren's syndrome significantly improves diagnostic performance of AECG classification criteria. *Arthritis Res. Ther.* 7, R343–R348 (2005).
- 19 Al-Hashimi I, Wright JM, Cooley CA, Nunn ME: Reproducibility of biopsy grade in Sjögren's syndrome. *J. Oral Pathol. Med.* 30, 408–412 (2001).
- 20 Radfar L, Kleiner DE, Fox PC, Pillemer SR: Prevalence and clinical significance of lymphocytic foci in minor salivary glands of healthy volunteers. *Arthritis. Rheum.* 47, 520–524 (2002).
- 21 Sigmundsdottir H, Butcher EC: Environmental cues, dendritic cells and the programming of tissue-selective lymphocyte trafficking. *Nat. Immunol.* 9, 981–987 (2008).
- 22 Pers JO, Devauchelle V, Daridon C *et al.*: BAFF-modulated repopulation of B lymphocytes in the blood and salivary glands of rituximab-treated patients with Sjögren's syndrome. *Arthritis. Rheum.* 56, 1464–1477 (2007).
- **Analyzed the repopulation of B-cell subsets in peripheral blood as well as their homing into salivary glands after rituximab treatment in patients with primary SS. Baseline serum levels of B-cell activating factor correlated inversely with the duration of B-cell depletion. Sequential salivary gland biopsies showed that B cells were absent for 12 months after treatment, and then reappeared 24 months after treatment. Thus, in addition to salivary glands, skin biopsy may be useful to evaluate the response after B-cell-targeted therapies in primary SS.**
- 23 Delaleu N, Immervoll H, Cornelius J, Jonsson R: Biomarker profiles in serum and saliva of experimental Sjögren's syndrome: associations with specific autoimmune manifestations. *Arthritis. Res. Ther.* 10, R22 (2008).
- 24 Hansen A, Reiter K, Ziprian T *et al.*: Dysregulation of chemokine receptor expression and function by B cells of patients with primary Sjögren's syndrome. *Arthritis. Rheum.* 52, 2109–2119 (2005).
- 25 Martin F, Kearney JF: B1 cells: similarities and differences with other B cell subsets. *Curr. Opin. Immunol.* 13, 195–201 (2001).
- 26 Daridon C, Pers JO, Devauchelle V *et al.*: Identification of transitional type II B cells in the salivary glands of patients with Sjögren's syndrome. *Arthritis. Rheum.* 54, 2280–2288 (2006).
- 27 Bos JD, de Rie MA, Teunissen MB, Piskin G: Psoriasis: dysregulation of innate immunity. *Br. J. Dermatol.* 152, 1098–1107 (2005).
- 28 Nashan D, Faulhaber D, Stander S, Luger TA, Stadler R: Mycosis fungoides: a dermatological masquerader. *Br. J. Dermatol.* 156, 1–10 (2007).
- 29 Youinou P, Devauchelle V, Hutin P, Le Berre R, Saraux A, Pers JO: A conspicuous role for B cells in Sjögren's syndrome. *Clin. Rev. Allergy. Immunol.* 32, 231–237 (2007).
- 30 Dörner T, Lipsky PE: Abnormalities of B cell phenotype, immunoglobulin gene expression and the emergence of autoimmunity in Sjögren's syndrome. *Arthritis Res.* 4, 360–371 (2002).
- 31 Pascual V, Liu YJ, Magalski A, de Bouteiller O, Banchereau J, Capra JD: Analysis of somatic mutation in five B cell subsets of human tonsil. *J. Exp. Med.* 180, 329–339 (1994).
- 32 Bohnhorst JO, Bjorgan MB, Thoen JE, Natvig JB, Thompson KM: Bm1-Bm5 classification of peripheral blood B cells reveals circulating germinal center founder cells in healthy individuals and disturbance in the B-cell subpopulations in patients with primary Sjögren's syndrome. *J. Immunol.* 167, 3610–3618 (2001).
- 33 Hansen A, Odendahl M, Reiter K *et al.*: Diminished peripheral blood memory B cells and accumulation of memory B cells in the salivary glands of patients with Sjögren's syndrome. *Arthritis Rheum.* 46, 2160–2171 (2002).
- 34 Binard A, Le Pottier L, Devauchelle-Pensec V, Saraux A, Youinou P, Pers JO: Is the blood B-cell subset profile diagnostic for Sjögren syndrome? *Ann. Rheum. Dis.* 68, 1447–1452 (2009).
- 35 Tobón GJ, Saraux A, Pers JO, Youinou P: Emerging biotherapies for Sjögren's syndrome. *Expert. Opin. Emerg. Drugs.* 15, 269–282 (2010).
- 36 Markusse HM, Oudkerk M, Vroom TM, Breedveld FC: Primary Sjögren's syndrome: clinical spectrum and mode of presentation based on an analysis of 50 patients selected from a department of rheumatology. *Neth. J. Med.* 40, 125–134 (1992).