

# Role of musculoskeletal ultrasound in juvenile idiopathic arthritis

Juvenile idiopathic arthritis is a serious autoimmune childhood disease that encompasses several types of chronic arthritis. Diagnosis is largely based on history and physical examination, although imaging modalities may play a role in diagnosis and also guiding management. In the past few years, technological advances in musculoskeletal ultrasound have led to a dramatic increase in the application of ultrasound in diagnosing and monitoring juvenile arthritis and other rheumatologic diseases. This article will review recent publications regarding the use of ultrasound in the diagnosis and treatment of juvenile idiopathic arthritis.

**KEYWORDS:** enthesitis ■ juvenile idiopathic arthritis ■ steroid injection ■ synovitis ■ tenosynovitis ■ ultrasound

Over the past decade, musculoskeletal ultrasound (MSK-US) has been described by many rheumatologists as the 'stethoscope' of the joint. Unlike conventional radiography, an established imaging technique for identifying progressive joint damage, US is sensitive to soft tissue lesions and can detect early erosive bone lesions [1,2]. The development of higher frequency probes (12–18 MHz) and portable US machines has led to better resolution of small joints and the increased use of MSK-US in patients with rheumatologic disease. Improvements in color Doppler (CD) and power Doppler (PD) imaging, where the amount of color is related to degree of blood flow, allow for better assessment of soft tissue inflammation [1,3,4]. Several studies have emerged supporting the clinical utility of MSK-US in evaluating rheumatologic diseases in children, especially in juvenile idiopathic arthritis (JIA), which will be described in this review. MSK-US is particularly well suited to the pediatric population in that it has no ionizing radiation, does not require sedation and can be easily performed in a clinical outpatient setting. Additionally, MSK-US allows for the dynamic assessment of clinically challenging joints and is relatively inexpensive compared with computed tomography (CT) or MRI [5,6].

JIA is the most common rheumatic disease in children and encompasses several types of chronic arthritis. JIA is a serious autoimmune disease that can cause significant short-term and long-term disability, including permanent joint damage [7]. Diagnosis of JIA is largely based on history and physical examination; however, imaging modalities including plain film radiography,

CT, MRI and also MSK-US may play a role in diagnosing and managing JIA. Advances in MSK-US have led to more widespread interest among pediatric rheumatologists in the application of US to diagnose JIA and to monitor the effects of localized and systemic therapy.

This article will review recent publications regarding the use of US in the diagnosis and treatment of JIA. Although the International League of Arthritis and Rheumatism (ILAR) classification is the most commonly used classification system for juvenile arthritis today, many of the research and published reports in childhood arthritis use terminology established by older classification criteria, such as juvenile chronic arthritis (JCA) and juvenile rheumatoid arthritis (JRA). All three classifications refer to chronic arthritis in children in which all other diseases are excluded [7]. This review article refers to the original classifications used in each study.

## Overview of JIA

The incidence of JIA ranges from one to 22 per 100,000, while the prevalence ranges from eight to 150 per 100,000 [8]. JIA is characterized by objective arthritis in one or more joints for a minimum of 6 weeks in a patient less than or equal to 16 years of age after other types of childhood arthritis have been excluded. There are no specific laboratory tests for the diagnosis of JIA, and diagnosis is largely dependent on patient history and physical examination. Arthritis is clinically defined as the presence of joint swelling not due to bony enlargement or inactive synovitis or, in the absence of joint swelling, limitation of motion accompanied

Johanna Chang<sup>1,2</sup>  
& Alessandra Bruns<sup>\*2</sup>

<sup>1</sup>Department of Pediatrics, Division of Allergy/Immunology/Rheumatology, University of San Diego, CA, USA

<sup>2</sup>Ultrasound Clinic, Department of Rheumatology, University of Sherbrooke, Sherbrooke, Canada

\*Author for correspondence:  
alessandra.bruns@usherbrooke.ca

by heat and tenderness [9,10]. Most institutions classify childhood arthritis using the 1997 criteria proposed by the ILAR that further differentiates JIA into different subtypes: polyarticular, oligoarticular, systemic, enthesitis-related (ERA), psoriatic or undifferentiated [7].

Oligoarticular JIA is the most common form of JIA, involving 50–60% of patients with JIA. Peak age of onset is between 1 and 5 years, with a female-to-male ratio of 4:1. Children with oligoarticular JIA have arthritis in less than five joints for at least 6 weeks [8]. Children with a diagnosis of psoriasis, a family history of psoriasis, a positive HLA-B27 or a positive rheumatoid factor (RF) are excluded from the diagnosis of oligoarticular JIA. Children with anti-nuclear antibody (ANA)-positive oligoarticular JIA are at high risk for the development of uveitis, which is often asymptomatic and requires frequent ophthalmologic examinations for early detection to prevent eye damage [7,11,12].

Children with polyarticular JIA have arthritis in five or more joints for at least 6 weeks. Polyarticular JIA affects 30–55% of patients with JIA. Patients with a positive RF or anticyclic citrullinated protein (CCP) antibody tend to have more erosive disease and a chronic course progressing into adulthood. Peak age of onset is biphasic with a female-to-male ratio of 5:1. Children with polyarticular JIA typically present with symmetric arthritis involving the small joints of the hands, although arthritis of larger joints such as the knee or ankle can also accompany small joint disease. Children with polyarticular JIA can rarely develop rheumatoid nodules. Uveitis affects approximately 5% of patients with polyarticular disease [7,11,12].

Systemic JIA involves 4–17% of patients with JIA [12]. Systemic JIA does not have a peak onset and affects males and females equally. Patients with systemic JIA usually present with fever and rash accompanied by high inflammatory markers. Although many present with symmetric, polyarticular arthritis, some children with systemic JIA develop arthritis later during the disease course. Diagnosis requires the presence of arthritis with a minimum of 2 weeks of daily quotidian fevers accompanied by an evanescent, nonfixed, erythematous rash, lymphadenopathy, hepatomegaly or splenomegaly, or serositis. Approximately 10% of children with systemic JIA develop a life-threatening complication known as macrophage activation syndrome (MAS) [7,12].

Children with enthesitis-related arthritis (ERA) typically have arthritis of both small and large joints with involvement of the hips,

sacro-iliac joints and lower back, as well as enthesitis, or inflammation at the region of tendon insertions. ERA includes patients with arthritis secondary to inflammatory bowel disease (IBD), reactive arthritis or ankylosing spondylitis. Patients with ERA account for 3–11% of patients with JIA and 13% of all patients with a rheumatologic condition [12]. ERA mainly affects male patients over the age of 6 years, although it typically involves older patients who are in their preteen or adolescent years. ERA is strongly associated with uveitis. Most patients have a positive HLA-B27; 82–95% of patients with ankylosing spondylitis are HLA-B27 positive [7,11,12].

Psoriatic arthritis is characterized by swelling of the digits ('dactylitis') and is usually accompanied by a diagnosis of psoriasis in the patient or in a first-degree family member. Diagnosis is obtained in patients with chronic arthritis and definite psoriasis or chronic arthritis and two of the following criteria: dactylitis, nail pitting or onycholysis, or a family history of psoriasis. Psoriatic arthritis can occur before, during or after dermatologic manifestations. Psoriatic arthritis affects 2–11% of patients with JIA. Age of onset is typically during the preschool years as well as middle-to-late childhood. Psoriatic arthritis is slightly more common in girls with a female-to-male ratio of 2.5:1. In total, 15–20% of patients with psoriatic arthritis have an asymptomatic chronic uveitis, while a very low percentage can develop a painful symptomatic uveitis similar to that seen in patients with ERA [7,11,12].

Patients who do not satisfy inclusion criteria for any of the six ILAR classifications or meet criteria for more than one of the six ILAR classifications can be included in the category of undifferentiated arthritis. Patients with undifferentiated arthritis must have objective arthritis for a minimum of 6 weeks [7,11].

### Technical aspects of MSK-US

Modern US devices utilize multifrequency probes. The frequency of the sound wave determines how deeply the tissue will be penetrated and also impacts image resolution. For the best resolution, the highest possible US frequency should be used. US in rheumatology is generally performed with linear probes, with the choice of probe frequency depending on the joint region to be examined. For instance, for small joints such as those of the wrist, hand, and feet, frequencies of 10–18 MHz are recommended. Middle-sized joints such as the knees and

shoulders are examined at 10–12 MHz, and deeper joints such as those of the hip are scanned with linear probes at 5–7.5 MHz or, for deeper penetration, with curved array probes at 3.5 MHz [4]. Probes are typically used to scan in longitudinal and transverse planes.

Because sonography is notoriously ‘operator-dependent’, patient positioning is also important while performing MSK-US. In an effort to standardize MSK-US, various groups including the Working Group for Musculoskeletal Ultrasound in Rheumatology of the European League Against Rheumatism (EULAR) and the Outcome Measures in Rheumatology task force have described detailed patient positioning as well as standard scans in adult patients [4].

It is important to note that definitions for US pathology in the pediatric population have not yet been standardized. The OMERACT committee has defined US measures for joint pathology in adults for rheumatoid arthritis [13], although the validity of applying these definitions in the pediatric population is still not clear. Growing cartilage and other musculoskeletal changes in maturing children pose challenges in appropriate sonographic interpretation. Because use of MSK-US in the field of pediatric rheumatology is an evolving phenomenon, more research in establishing definitions of normal and pathological joint findings in children is greatly needed.

Most MSK-US is performed using B (brightness)-mode US (also known as ‘grayscale’ US) in which sound waves are displayed as a 2D image consisting of variable shades of darkness corresponding to the different densities of the scanned object. Other techniques are often combined with B-mode US to provide more information about the scanned anatomy, including color Doppler (CD), power Doppler (PD) and the use of intravenous (iv.) contrast material. CD shows colored blood flow superimposed on the grayscale image. PD is another color flow imaging technique used to detect increased capillary vascularization that is more sensitive to blood flow compared with conventional CD. Increased blood flow on CD or PD may occur with inflammation and neovascularization and is useful in determining the presence of synovitis. However, some sonographers suggest that increased PD signals can be present near the epiphyses of growing bones in healthy children, which may be incorrectly interpreted on MSK-US as synovitis [14]. Another study noted the presence of PD signal in physeal/epiphyseal cartilage in 4.2% of the studied joints in healthy

children [15]. A few studies have compared the use of CD and PD in children with JIA. One study of 30 patients with JIA and knee arthritis noted that CD detected synovial vessels in ten out of 13 subjects (76.9%), while PD detected synovial vessels in 13 out of 17 subjects (76.5%). A significant correlation was found between the degree of vascularity detected by PD and Juvenile Arthritis Functional Assessment Report (JAFAR) score and also between PD and a numerical knee score based on pain, swelling and limitation [14]. Another study of 30 JIA patients with bilateral knee arthritis demonstrated a statistically significant correlation between clinical and US PD findings of arthritis and response to treatment over time [16]. Some sonographers have also studied the use of contrast-enhanced color Doppler. In a study using SHU 508, also known as Levovist, subjects with JIA with clinically inactive arthritis with elevated inflammatory markers who received the iv. contrast were found to have increased mean pixel intensity values of synovium compared with patients with inactive disease and control patients before and after contrast administration [17]. Overall, the roles of PD and CD signal as well as contrast-enhanced Doppler have not been fully established in JIA, and further investigations are required to fully determine the utility of these techniques for detecting disease activity in children. The use of iv. contrast material in the pediatric population may have some additional risks, including the risk of allergic reaction, and also increases the invasiveness of MSK-US. In addition, the possible misinterpretation of PD signals in the growing bones of young children highlights the importance of providing normal standards for interpreting Doppler signals found in various age groups.

### Synovitis

Several studies have shown increased sensitivity of sonography compared with clinical examination for the detection of synovitis [18–24]. Evidence of persistent synovial disease has been documented by both US as well as MRI in several patients in clinical remission [18]. Synovitis is identified on clinical examination by the presence of swelling or effusion with increased heat, limitation of range of motion and/or pain on motion in one or more joints [7]. On US imaging, synovitis is defined by the OMERACT task force as the presence of an abnormally hypoechoic joint space reflecting synovial hypertrophy, distinct from the intra-articular fat pad and noncompressible with the transducer, in which a Doppler signal may be seen. Synovial fluid is detected on US

by the presence of an abnormally hypoechoic or anechoic space within the joint, which is compressible. PD signal is considered positive with presence of colored pixels on PD imaging and is thought to represent inflammation [4,13].

Studies comparing clinical and US findings of arthritis in various joints have largely shown increased sensitivity of US in detecting signs of arthritis [15,19,20,22,25–27]; some of these studies demonstrated US findings of inflammation in clinically asymptomatic joints [19,20,25,27]. Overall, clinical synovitis moderately correlated with sonographic findings of synovitis; some studies have shown increased correlation in joints with more obvious clinical findings [19,22,26]. Breton *et al.* performed B-mode and PD US in 31 patients with JIA and 41 healthy children. In this study, sonographic synovitis of the metatarsophalangeal (MTP) and metacarpophalangeal (MCP) joints was significantly associated with clinical detection of abnormalities ( $p < 0.0001$ ), but agreement was low between sonographic and physical findings. No synovitis was detected in any of the healthy controls [15]. Karmazyn *et al.* used B-mode and CD US to score the metacarpophalangeal (MCP) joints in 20 children with JIA and 12 age-matched controls. While the correlation between US abnormalities and physical examination scores were statistically significant, interobserver agreement between US and physical examination was poor, although agreement improved in children with moderate or severe clinical findings [26]. In the studies conducted by Cellierini *et al.* and Kakati *et al.*, US demonstrated significant increase of effusion and synovial thickening in subjects with JIA with clinically symptomatic knee arthritis. The correlation between clinical and sonographic findings was statistically significant for subjects with clinically active knees, but not statistically significant for subjects with clinically inactive arthritis [19,22]. US detected effusion and synovial thickening in 70% of clinically quiescent patients [19]. Another study using grayscale sonography found that 21% of knees in patients with JIA contained intra-articular fluid not detected on physical examination [27]. A grayscale US study from 2003 concluded that sonographic findings of knee effusion provided the highest correlation with clinical measures of disease activity. This study also found that 50% of patients with JRA had sonographic findings of arthritis in the absence of clinically active coxitis. In this study, there was no significant correlation between sonographic and clinical measures of

disease activity in coxitis [20]. Another grayscale US study of hip arthritis in 24 children with JRA demonstrated the presence of bilateral effusion in one in three children with a normal hip examination and bilateral effusions in three in 16 children with a negative examination of one hip [25].

Although sonographic synovitis is defined by the presence of synovial hyperplasia, the significance of US findings of synovial thickness is somewhat unclear. The studies from Cellierini *et al.* and Kakati *et al.* both detected synovial thickening in knees in patients with quiescent JIA compared with controls, although Frosch *et al.* did not note significant difference in synovial thickness in patients with clinically inactive and active arthritis. However, Frosch *et al.* did note hyperplasia of the synovium in the hips of the patients with JRA, which correlated with reduction of joint mobility and elevated C-reactive protein levels ( $p < 0.05$ ) [19,20,22]. In a study by Breton *et al.*, US synovitis was defined as ‘synovial hypertrophy plus PD signal’; in this study, US synovitis was significantly associated with synovial hypertrophy, although isolated synovial hypertrophy without US synovitis was noted in 5% of the studied joints [15]. Such findings highlight the importance of further evaluation of the clinical and prognostic indications of various US findings and the importance of establishing definitions for MSK-US pathology in JIA.

The significance of subclinical synovitis detected by US is also not completely known, as there have been few longitudinal studies evaluating the outcome of patients with subclinical synovitis. Many authors argue that the increased sensitivity of US in detecting subclinical disease may lead to reclassification of JIA subtype, which has implications on both treatment as well as prognosis. One study from 2010 detected subclinical synovitis in six in 17 children with JIA, mostly in the hands and feet. One in 17 subjects could be reclassified as having polyarticular disease based on US findings [21]. Magni-Manzoni *et al.* examined 1664 joints in 32 patients with JIA. Of the 1560 clinically normal joints, 86 (5.5%) had subclinical synovitis. US led to classifying five subjects as having polyarthritis who were classified as having oligoarthritis or were found to have no synovitis on clinical evaluation [23].

In our experience, effusion and synovial thickening can be present even in clinically quiescent disease [24]. One grayscale US study evaluating correlation between clinical US

findings of TMJ arthritis in JIA patients suggested that high-resolution US detected TMJ pathology before clinical symptoms appeared [28]. Other studies have shown that histologic evidence of synovial inflammation in clinically asymptomatic joints [29] and US findings of inflammation may better reflect actual joint pathophysiology in children with chronic arthritis compared with physical examination. Interestingly, a recent study from 2012 concluded that US pathology did not predict an early flare of synovitis in the affected joints. In this study, 32 clinically inactive patients with JIA were followed by US and clinical examination for 2 years; during the study period, 15 patients had an arthritis flare, although only 17 of the 45 flared joints had US abnormalities at the beginning of the study [30]. More longitudinal studies are needed to further characterize the clinical significance of US-detected synovitis in asymptomatic children with JIA.

### Tenosynovitis

US may be particularly useful in detecting tenosynovitis, which on physical examination can be easily confused with tendonitis or arthritis. The OMERACT task force has defined tenosynovitis as 'hypoechoic or anechoic thickened tissues with or without fluid within the tendon sheath that may exhibit Doppler signal' [13]. Studies applying MSK-US to medium-sized joints involving numerous tendons, particularly the ankles, suggest a role for US to better elucidate the actual pathology of these joints in children with JIA.

Rooney *et al.* [5] and Pascoli *et al.* [6] used US to evaluate the anatomical basis for clinically detected ankle joint swelling in JIA. In the retrospective study by Rooney *et al.*, 49 clinically swollen ankles in 34 JIA patients were assessed clinically and also by US examination. Results of the study showed tenosynovitis in 71% of ankles, tenosynovitis and tibiotalar effusion in 33% of ankles, and isolated tibiotalar effusion in only 29% of swollen ankles. This study concluded that tibiotalar disease may be overdiagnosed, while tendon involvement may be underdiagnosed [5]. Pascoli *et al.* performed a prospective study of 42 JIA patients. In this study, 61 swollen and/or painful ankles were assessed clinically and also by US. Very poor agreement was observed comparing clinical and US scores for the tibiotalar joint and medial and lateral tendons. The authors concluded that the discrepancy between US and clinical scoring for tibiotalar arthritis and tenosynovitis of the

ankle tendons may lead to incorrect classification of children into JIA subtypes [6]. Examination findings by a rheumatologist and one to two podiatrists varied significantly from MSK-US examination of the foot ( $k < 0.40$ ) in a study by Hendry *et al.* In this study, 30 patients with JIA and a history of foot disease underwent clinical and US examination of 24 foot joints, ten tendons and six periarticular soft tissues. Each site was examined independently by a rheumatologist and a podiatrist for synovitis and tenderness/swelling and then by a sonographer for effusion, synovial hypertrophy, PD signal, tenosynovitis or abnormal tendon thickening. In this study, clinical examination both under- and overestimated clinical signs compared with MSK-US findings. This study noted particularly poor agreement between US and the podiatrist's examination of tenderness. The authors suggest that 'inaccurate' clinical examination may result in failure to administer adequate medication or, in cases of clinician overestimation of inflammatory disease, lead to overly aggressive administration of pharmacologic therapy [31].

### Enthesitis

A few studies have been conducted regarding the sensitivity of US in detecting enthesitis or inflammation of the insertion of tendons, ligaments, capsules or fascia to bone, which is commonly seen in ERA. As defined by the OMERACT network, enthesitis is visualized sonographically as 'an abnormally hypoechoic and/or thickened tendon or ligament at its bony attachment seen in two perpendicular planes that may exhibit Doppler signal and/or bony changes' [13]. Other US signs of enthesopathy include loss of normal tendon or ligament fibrillar structure, intratendinous or intraligamentary calcifications, erosions, new bone formation and associated abnormalities of adjacent bursae.

One US study detected decreased echogenicity of the insertion of the gluteus medius tendon onto the posterior iliac crest in patients with focal, palpable tenderness as well as significantly thicker entheses in JIA patients compared with healthy controls ( $p < 0.003$  left side,  $p < 0.001$  right side). The authors concluded that these findings may represent chronic, inactive disease in some of the patients [32]. However, another study noted tendon thickening as well as cartilage vascularization in healthy, asymptomatic controls. In this study, clinical findings of enthesitis in five different locations (proximal and distal quadriceps tendon insertions, Achilles tendon and plantar fascia) were significantly associated with US



findings of PD signal present at the enthesal insertion ( $p < 0.0001$ ). However,  $\kappa$ -coefficients for concordance with US-PD enthesitis were only 0.35 for clinical tenderness and 0.50 for clinical swelling. US did show findings of enthesitis in 50% of clinically normal distal patellar tendons [33]. As for MSK-US findings of synovitis, further studies are needed to determine the long-term consequences of subclinical enthesitis.

### Comparison with other imaging modalities

While MSK-US has many advantages over other imaging modalities and procedures to determine inflammation, it is important to note its comparative sensitivity and specificity. One study demonstrated a positive correlation between capsule distention of the hip as measured by MSK-US and increased intracapsular pressure and severe synovitis revealed on arthroscopy [34]. Another study using MRI and US to monitor the response of ten JCA patients to intra-articular steroid (IAS) injections of the knees and hips concluded that US was as sensitive as MRI in detecting pannus and/or effusion before IAS injection, although US distinction between the two entities was less clear compared with MRI [35]. El-Miedany *et al.* compared x-ray, US and MRI findings in the knees of 38 patients with clinically active JIA and also in ten healthy control patients. Grayscale US detected synovial proliferation in 18 out of 38 cases compared with MRI, which detected 28 cases of synovial proliferation. US detected cartilage destruction in seven out of 38 patients compared with MRI detection of destruction in 22 out of 38 and five out of 38 patients by x-ray. Of note, PD-US was not used in this study [1]. Malattia *et al.* compared MRI, conventional radiography, and grayscale US in identifying bone erosions in the wrists of 26 JIA patients. In this study, 25 subjects had one or more erosions detected by MRI, while US and conventional radiology revealed erosions in 13 and 12 subjects, respectively [36]. Interestingly, the significance of erosions detected only by MRI has been questioned; previous studies by McQueen *et al.* in adult subjects with rheumatoid arthritis showed that only one of four erosions detected on MRI progress to become radiographic erosions [37]. In addition, several MRI studies of the wrists of healthy children have shown carpal cortical depressions similar to MRI findings of true bony erosions in the early stages [38–40]. Further studies on the significance of erosions detected by MSK-US will be helpful in determining the prognostic indications of

these findings. Weiss *et al.* compared grayscale US and contrast-enhanced MRI for the detection of acute and chronic changes of TMJ arthritis in 32 new-onset JIA patients. In this study, acute TMJ arthritis was diagnosed in 75% of the children by MRI and in none by US; chronic arthritis was diagnosed in 69% by MRI and in 28% by US [41]. Muller *et al.* performed a pilot study comparing rheumatologic and orthodontic examinations and grayscale US against MRI in diagnosing TMJ arthritis. This study revealed that 63% of subjects with JIA had signs of TMJ involvement on MRI, but rheumatologic, orthodontic and US examinations correctly diagnosed TMJ arthritis in 58, 47 and 33% patients, respectively [42]. These studies suggest that US may be of limited utility in evaluating TMJ arthritis, although PD was not used in any of these studies; use of PD and/or other techniques may possibly increase sensitivity and specificity of sonographic detection of TMJ inflammation, but more studies regarding this have yet to be performed.

### Treatment of JIA using intra-articular steroid injections

Intra-articular steroid injections are often used in various subtypes of JIA to allow for symptomatic relief and quickly reduce synovitis. In oligoarticular JIA, IAS injections may induce disease remission, thus avoiding patient exposure to systemic medications. IAS injections are also used as bridging therapy when starting new systemic medications in patients with other JIA subtypes. Many studies have identified US as a potential tool for aiding or monitoring the results of IAS injections in JIA. In a review article by Scott *et al.*, US was described as a 'valuable tool' that could aid practitioners in gaining accuracy in needle placement and achieving better results [43]. A retrospective study evaluating US-guided IAS injections of the TMJ used CT to confirm that 91% of US-guided TMJ injections were intra-articular [44]. Besides allowing more accurate medication delivery, MSK-US can also be used to evaluate disease progression or regression following IAS therapy. Tynjala *et al.* used MSK-US to evaluate 20 hips in 13 JIA patients before and for 12 months after IAS injection. This study showed a successful treatment response, defined as absence of synovitis clinically and lack of effusion on US, in half of the subjects 12 months after steroid injection [45]. Another study of 48 children with JIA who received US-guided IAS injection of the hips showed remission of coxitis assessed

clinically and with US and MRI at 2 years in 76% of the hips after single or repeated injections [46].

### Challenges of MSK-US in JIA

Although MSK-US has many advantages for assessing joint inflammation and musculoskeletal pathology, it is not yet a validated tool to diagnose and evaluate the course of JIA. As discussed previously, definitions for pathology as identified by MSK-US are largely derived using OMERACT criteria and have not yet been validated in large studies in the pediatric population. A recent systematic literature review of 20 studies using US to assess synovitis in JIA found significant heterogeneity in US definition and measurements of synovitis [47]. Interpretation of MSK-US in the pediatric population is complicated by evolving bone and cartilage vascularization and cortical irregularities that appear in normal, growing children [15,38–40]. While PD signals in conjunction with other findings can be interpreted as signs of inflammation, PD signals can be seen in clinically asymptomatic children and also detected in areas of normal cartilage vasculature [14,15]. The definition of ‘synovial hypertrophy’ as described by the OMERACT committee may not be applicable to a pediatric population in which normal ranges of synovial thickness have not been established. As demonstrated by MRI and US studies, bony depressions that appear similar to pathological erosions can occur in the wrists, MCPs and MTPs of asymptomatic children [15,38–40]. These studies highlight the importance of establishing normal standards of US anatomy of joints in growing children in order to accurately interpret US findings in children with JIA. The lack of parameters describing normal sonographic anatomy of children is at this time one of the greatest limitations of MSK-US studies of JIA; however, a few studies have emerged focusing on normal findings in children and also on the establishment of reference values for normal pediatric joint anatomy. One study investigated the hips, knees and fingers of 60 healthy children ages 2–16 years old. This study described the presence of a small amount of fluid in the suprapatellar recess and also in the MCP and PIP joint recesses and flexor tendon sheaths without any PD signal; however, an intracapsular PD signal in the posterior layer of the hip capsule was noted in 5% of children younger than 5 years [48]. Spannow *et al.* described normal ranges of cartilage in the hips, knees,

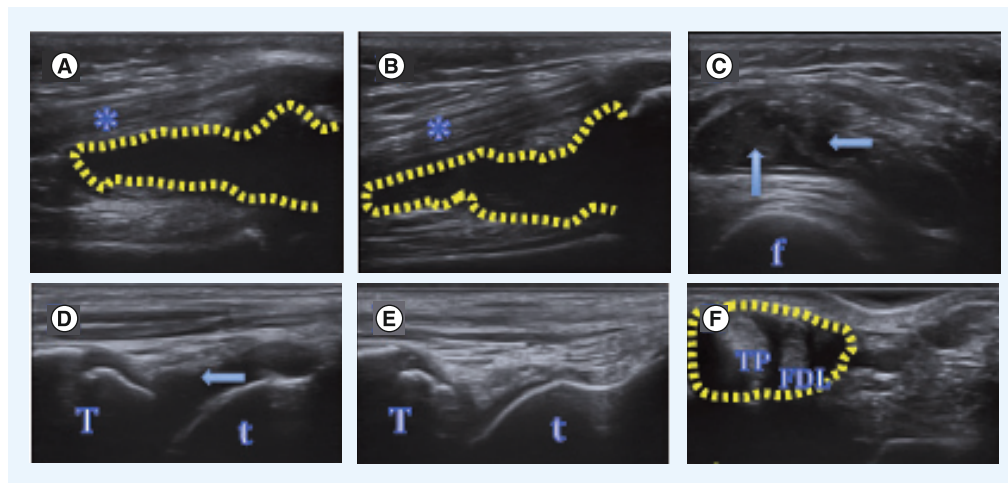
ankles, second MCP and second PIP joints in 11 children ranging from 9.3 to 10 years. This study noted a high level of agreement for measurement of the cartilage thickness in these joints that was statistically significant between a skilled and nonskilled sonographer [49]. A larger study of the measurement of the same five joints in 74 healthy children with ages ranging from 7 to 16 years showed good inter- and intra-observer agreement for the knee and MCP joints, acceptable agreement for the ankle and PIP joints, but poor agreement in the wrist joint [50]. In both studies, the authors found that positioning of the joint and transducer was of major importance for reproducibility of US measurements. These studies indicate a need to collect more information from studying healthy, clinically normal children in order to establish definitions of joint pathology to accurately diagnose and monitor juvenile arthritis.

### Practical aspects

We have reviewed several studies demonstrating the utility of MSK-US in detecting joint pathology in patients with JIA. We would also like to include a few cases from our US clinic to show some of the practical aspects of using MSK-US in an outpatient pediatric rheumatology setting. In our experience, pediatric patients and their families appreciate sonographic visualization of joint anatomy to accompany the physical examination. We would again like to emphasize that clinical outcomes in patients with JIA and sonographic abnormalities have not yet been well studied, and at this time we largely base our therapeutic decisions on history and physical examination. However, we feel that there is a definite role for MSK-US in the clinical setting, especially in supporting clinical findings of joint abnormalities, distinguishing between joint effusion and tenosynovitis in joints such as the ankles and wrists, and guiding procedures such as joint aspirations and intra-articular steroid injections, which typically are carried out in an outpatient setting based on knowledge of anatomy and palpation and visualization of bony landmarks.

#### ■ Case 1

A 6-year-old female with history of oligoarticular JIA was referred to our US clinic. Clinical history was remarkable for active arthritis of the right knee as well as tenderness with inversion and eversion of the left ankle. On physical examination, the left ankle showed no swelling or warmth with normal range of motion of the



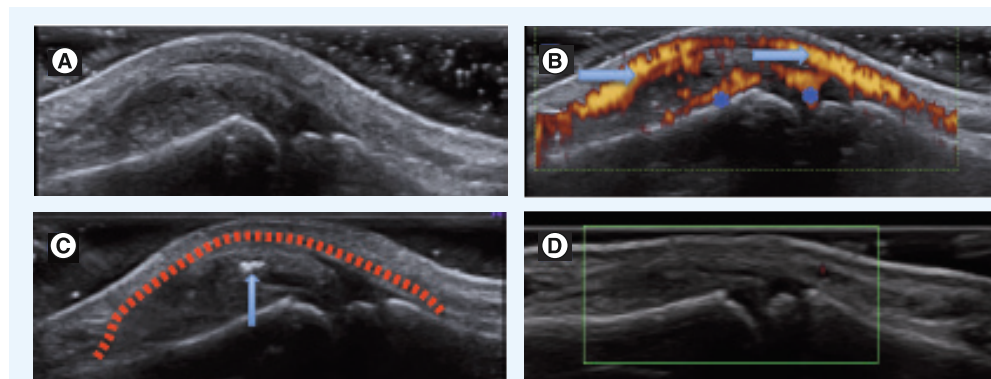
**Figure 1. Images of patient with clinically active arthritis of the right knee.** (A) Longitudinal view of the suprapatellar recess of the clinically asymptomatic left knee showing effusion (outlined in yellow) on ultrasound. (B) Longitudinal view of the suprapatellar recess of the clinically active right knee. Effusion is outlined in yellow. (C) Transverse view of the suprapatellar recess of the clinically active right knee. Upward arrow indicates synovial proliferation. Left arrow indicates effusion. (D) Longitudinal view of the clinically normal left tibiotalar joint showing effusion; left arrow indicates effusion. (E) Longitudinal view of the clinically normal right tibiotalar joint. (F) Transverse view of the medial compartment of the clinically asymptomatic right ankle showing tenosynovitis (outlined in yellow). \*: Quadriceps tendon; F: Femur; FDL: Flexor digitorum longus tendon; t: Talus; T: Tibia; TP: Tibialis posterior tendon.

tibiotalar and subtalar joints. Left knee and right ankle were clinically normal. We performed US on both knees and ankles and noted synovial hyperplasia and effusion of both knees and the left tibiotalar joint, as well as tenosynovitis of all tendons of the medial and lateral compartments of both ankles. The subtalar joints were normal. PD signal was present in the right knee and in the thickened sheath of all tendons of the medial and lateral compartments of both ankles (FIGURE 1). Sonographic evidence supported our clinical

diagnosis of arthritis, and in this case the patient was started on a disease-modifying antirheumatic drug. In addition, MSK-US in this patient also revealed subclinical synovitis and was helpful in differentiating between tenosynovitis and arthritis.

#### Case 2

A 10-year-old boy with history of juvenile psoriatic arthritis was referred to our US clinic for evaluation and treatment of his left third finger.



**Figure 2. Images of patient with dactylitis.** (A) Dorsal longitudinal view of the left third proximal interphalangeal joint showing synovial hyperplasia and effusion. (B) Same view showing vessel on top (marked by arrows) and also Doppler signal reverberation (marked by \*). (C) Ultrasound confirming intra-synovial presence of steroid (marked by arrow) after injection of the left third proximal interphalangeal joint. Joint capsule is outlined in red. (D) Ultrasound performed 1.5 months after steroid injection showed decrease in synovial hyperplasia and no Doppler signal.



Clinical examination was notable for dactylitis of the left third finger. We performed US of the patient's left hand that showed synovitis of the patient's left third PIP. We elected to treat the patient with an IAS injection of his left third PIP, which was performed under US guidance. US was performed 1.5 months after the procedure and revealed decreased synovial thickness compared to previous, and no Doppler signal was detected (FIGURE 2). Clinically, the patient had decreased swelling and tenderness of this joint. This case highlights the advantage of US in aiding steroid injections of small joints and in monitoring steroid response.

## Conclusion

US appears to be a sensitive tool in detecting synovitis and other signs of inflammation of

several joints, including the knees, ankles, hips, wrists, fingers and TMJs. The sensitivity of MSK-US can be improved with the use of CD, PD and contrast-enhanced Doppler. MSK-US appears to be more sensitive than physical examination in detecting synovitis, tenosynovitis and enthesitis; the clinical significance of this is still unclear, and more longitudinal studies regarding patient outcome and studies examining physician decision-making based on MSK-US findings will be helpful. US can be helpful in guiding routine rheumatology procedures, such as joint aspiration and IAS injections. Studies continue to be carried out regarding normal MSK-US findings in growing children and the establishment of normal values such as cartilage thickness, which will be important as MSK-US

## Executive summary

### Overview of juvenile idiopathic arthritis

- Juvenile idiopathic arthritis (JIA) is a serious childhood autoimmune disease that can lead to significant short-term and long-term disability.
- JIA is typically categorized into six different subcategories of chronic arthritis.

### Technical aspects of musculoskeletal ultrasound

- Musculoskeletal ultrasound (MSK-US) uses multi-frequency probes; different frequencies are chosen based on joint sizes to establish the best resolution.
- Patient positioning is important and has been standardized by various MSK-US groups.
- Definitions for US pathology have been established for joint pathology in adults with rheumatoid arthritis; these definitions have not been standardized for juvenile arthritis.
- MSK-US is usually performed using B-mode or grayscale US.
- Techniques such as color Doppler, power Doppler or use of intravenous contrast material can be used to increase sensitivity of MSK-US in detecting inflammation.

### Synovitis

- Synovitis is clinically defined as the presence of swelling or effusion with increased heat, limitation of range of motion or pain on motion in one or more joints.
- Synovitis is defined sonographically by the OMERACT group as the presence of increased synovial fluid or synovial hypertrophy that may exhibit Doppler signal.
- MSK-US can be used to detect synovitis in JIA.
- Many studies show increased sensitivity of MSK-US compared with clinical examination in detecting synovitis.

### Tenosynovitis

- MSK-US has been shown to be more sensitive than clinical examination in differentiating between arthritis and tenosynovitis, especially in lower extremity joints.

### Enthesitis

- MSK-US is sensitive in detecting enthesitis.

### Comparison with other imaging modalities

- Several studies have been carried out comparing sensitivity and specificity of MSK-US with MRI, x-ray and physical examination.

### Treatment of JIA using intra-articular steroid injections

- MSK-US can be used to both guide intra-articular steroid injections as well as monitor the results of steroid injections in patients with JIA.

### Challenges of MSK-US in JIA

- MSK-US has not yet been validated as a means to diagnose and evaluate the course of JIA.
- More studies need to be carried out to establish normal standards of US anatomy in growing children in order to define US joint pathology in JIA.

becomes more commonly used in the outpatient pediatric rheumatology setting. MSK-US can be considered a useful adjunct to routine practice of pediatric rheumatology and will likely advance knowledge of pathophysiology of patients with JIA as well as guide diagnosis and treatment and improve disease monitoring.

### Future perspective

Despite current limitations with MSK-US, we feel that the many advantages of US will eventually lead to routine use of MSK-US as an adjunctive part of routine pediatric rheumatology care. The addition of technology such as CD and PD has increased sensitivity in detecting signs of inflammation on MSK-US examination of joints. 3D volumetric US is a newer technology that may further enhance sensitivity and

specificity of joint pathology in adults with chronic arthritis, although to our knowledge this has not yet been applied in large studies of juvenile arthritis. MSK-US is gaining increased use in the pediatric rheumatology population, and further studies will help establish definitions of joint pathology in children with JIA.

### Financial & competing interests disclosure

*The authors have no relevant affiliations or financial involvement with any organization or entity with a financial interest in or financial conflict with the subject matter or materials discussed in the manuscript. This includes employment, consultancies, honoraria, stock ownership or options, expert testimony, grants or patents received or pending, or royalties.*

*No writing assistance was utilized in the production of this manuscript.*

### References

- El-Miedany YM, Housny IH, Mansour HM, Mourad HG, Mehanna AM, Megeed MA. Ultrasound versus MRI in the evaluation of juvenile idiopathic arthritis of the knee. *Joint Bone Spine* 68(3), 222–230 (2001).
- Tok F, Demirkaya E, Ozcakar L. Musculoskeletal ultrasound in pediatric rheumatology. *Pediatr. Rheumatol. Online J.* 9, 25 (2011).
- Hau M, Schultz H, Tony HP *et al.* Evaluation of pannus and vascularization of the metacarpophalangeal and proximal interphalangeal joints in rheumatoid arthritis by high-resolution ultrasound (multidimensional linear array). *Arthritis Rheum.* 42(11), 2303–2308 (1999).
- Backhaus M, Burmester GR, Gerber T *et al.* Guidelines for musculoskeletal ultrasound in rheumatology. *Ann. Rheum. Dis.* 60(7), 641–649 (2001).
- Rooney ME, Mcallister C, Burns JF. Ankle disease in juvenile idiopathic arthritis: ultrasound findings in clinically swollen ankles. *J. Rheumatol.* 36(8), 1725–1729 (2009).
- Pascoli L, Wright S, Mcallister C, Rooney M. Prospective evaluation of clinical and ultrasound findings in ankle disease in juvenile idiopathic arthritis: importance of ankle ultrasound. *J. Rheumatol.* 37(11), 2409–2414 (2010).
- Cassidy JT. *Textbook of Pediatric Rheumatology (6th Edition)*. Saunders, Philadelphia, PA, USA (2010).
- Weiss JE, Ilowite NT. Juvenile idiopathic arthritis. *Pediatr. Clin. North Am.* 52(2), 413–442, vi (2005).
- Cassidy JT, Levinson JE, Bass JC *et al.* A study of classification criteria for a diagnosis of juvenile rheumatoid arthritis. *Arthritis Rheum.* 29(2), 274–281 (1986).
- Brewer EJ, Jr, Bass J, Baum J *et al.* Current proposed revision of JRA Criteria. JRA Criteria Subcommittee of the Diagnostic and Therapeutic Criteria Committee of the American Rheumatism Section of The Arthritis Foundation. *Arthritis Rheum.* 20(Suppl. 2), 195–199 (1977).
- Goldmuntz EA, White PH. Juvenile idiopathic arthritis: a review for the pediatrician. *Pediatr. Rev.* 27(4), e24–32 (2006).
- Ravelli A, Martini A. Juvenile idiopathic arthritis. *Lancet* 369(9563), 767–778 (2007).
- Wakefield RJ, Balint PV, Szkudlarek M *et al.* Musculoskeletal ultrasound including definitions for ultrasonographic pathology. *J. Rheumatol.* 32(12), 2485–2487 (2005).
- Shahin AA, El-Mofty SA, El-Sheikh EA, Hafez HA, Ragab OM. Power Doppler sonography in the evaluation and follow-up of knee involvement in patients with juvenile idiopathic arthritis. *Z. Rheumatol.* 60(3), 148–155 (2001).
- Breton S, Jousse-Joulin S, Cangemi C *et al.* Comparison of clinical and ultrasonographic evaluations for peripheral synovitis in juvenile idiopathic arthritis. *Semin. Arthritis Rheum.* 41(2), 272–278 (2011).
- Shanmugavel C, Sodhi KS, Sandhu MS *et al.* Role of power Doppler sonography in evaluation of therapeutic response of the knee in juvenile rheumatoid arthritis. *Rheumatol. Int.* 28(6), 573–578 (2008).
- Doria AS, Kiss MH, Lotito AP *et al.* Juvenile rheumatoid arthritis of the knee: evaluation with contrast-enhanced color Doppler ultrasound. *Pediatr. Radiol.* 31(7), 524–531 (2001).
- Brown A, Hirsch R, Laor T *et al.* Patients with juvenile idiopathic arthritis in clinical remission have evidence of persistent inflammation as revealed by 3T MRI. *Arthritis Care Res. (Hoboken)* 64(12), 1846–1854 (2012).
- Cellerini M, Salti S, Trapani S, D'elia G, Falcini F, Villari N. Correlation between clinical and ultrasound assessment of the knee in children with mono-articular or pauci-articular juvenile rheumatoid arthritis. *Pediatr. Radiol.* 29(2), 117–123 (1999).
- Frosch M, Foell D, Ganser G, Roth J. Arthrosonography of hip and knee joints in the follow up of juvenile rheumatoid arthritis. *Ann. Rheum. Dis.* 62(3), 242–244 (2003).
- Haslam KE, Mccann LJ, Wyatt S, Wakefield RJ. The detection of subclinical synovitis by ultrasound in oligoarticular juvenile idiopathic arthritis: a pilot study. *Rheumatology (Oxford)* 49(1), 123–127 (2010).
- Kakati P, Sodhi KS, Sandhu MS, Singh S, Katariya S, Khandelwal N. Clinical and ultrasound assessment of the knee in children with juvenile rheumatoid arthritis. *Indian J. Pediatr.* 74(9), 831–836 (2007).
- Magni-Manzoni S, Epis O, Ravelli A *et al.* Comparison of clinical versus ultrasound-determined synovitis in juvenile idiopathic arthritis. *Arthritis Rheum.* 61(11), 1497–1504 (2009).
- Rebollo-Polo M, Koujok K, Weisser C, Jurencak R, Bruns A, Roth J. Ultrasound findings on patients with juvenile idiopathic arthritis in clinical remission. *Arthritis Care Res. (Hoboken)* 63(7), 1013–1019 (2011).
- Friedman S, Gruber MA. Ultrasonography of the hip in the evaluation of children with

- seronegative juvenile rheumatoid arthritis. *J. Rheumatol.* 29(3), 629–632 (2002).
- 26 Karmazyn B, Bowyer SL, Schmidt KM *et al.* US findings of metacarpophalangeal joints in children with idiopathic juvenile arthritis. *Pediatr. Radiol.* 37(5), 475–482 (2007).
  - 27 Sureda D, Quiroga S, Arnal C, Boronat M, Andreu J, Casas L. Juvenile rheumatoid arthritis of the knee: evaluation with US. *Radiology* 190(2), 403–406 (1994).
  - 28 Jank S, Haase S, Strobl H *et al.* Sonographic investigation of the temporomandibular joint in patients with juvenile idiopathic arthritis: a pilot study. *Arthritis Rheum.* 57(2), 213–218 (2007).
  - 29 Kraan MC, Patel DD, Haringman JJ *et al.* The development of clinical signs of rheumatoid synovial inflammation is associated with increased synthesis of the chemokine CXCL8 (interleukin-8). *Arthritis Res.* 3(1), 65–71 (2001).
  - 30 Magni-Manzoni S, Scire CA, Ravelli A *et al.* Ultrasound-detected synovial abnormalities are frequent in clinically inactive juvenile idiopathic arthritis, but do not predict a flare of synovitis. *Ann. Rheum. Dis.* 72(2), 223–228 (2013).
  - 31 Hendry GJ, Gardner-Medwin J, Steultjens MP, Woodburn J, Sturrock RD, Turner DD. Frequent discordance between clinical and musculoskeletal ultrasound examinations of foot disease in juvenile idiopathic arthritis. *Arthritis Care Res. (Hoboken)* 64(3), 441–447 (2012).
  - 32 Laurell L, Court-Payen M, Nielsen S *et al.* Ultrasonography and color Doppler of proximal gluteal enthesitis in juvenile idiopathic arthritis: a descriptive study. *Pediatr. Rheumatol. Online J.* 9(1), 22 (2011).
  - 33 Jousse-Joulin S, Breton S, Cangemi C *et al.* Ultrasonography for detecting enthesitis in juvenile idiopathic arthritis. *Arthritis Care Res. (Hoboken)* 63(6), 849–855 (2011).
  - 34 Rydholm U, Wingstrand H, Egund N, Elborg R, Forsberg L, Lidgren L. Sonography, arthroscopy, and intracapsular pressure in juvenile chronic arthritis of the hip. *Acta Orthop. Scand.* 57(4), 295–298 (1986).
  - 35 Eich GF, Halle F, Hodler J, Seger R, Willi UV. Juvenile chronic arthritis: imaging of the knees and hips before and after intraarticular steroid injection. *Pediatr. Radiol.* 24(8), 558–563 (1994).
  - 36 Malattia C, Damasio MB, Magnaguagno F *et al.* Magnetic resonance imaging, ultrasonography, and conventional radiography in the assessment of bone erosions in juvenile idiopathic arthritis. *Arthritis Rheum.* 59(12), 1764–1772 (2008).
  - 37 McQueen FM, Stewart N, Crabbe J *et al.* Magnetic resonance imaging of the wrist in early rheumatoid arthritis reveals progression of erosions despite clinical improvement. *Ann. Rheum. Dis.* 58(3), 156–163 (1999).
  - 38 Avenarius DM, Oeding Muller LS, Eldevik P, Owens CM, Rosendahl K. The pediatric wrist revisited – findings of bony depressions in healthy children on radiographs compared to MRI. *Pediatr. Radiol.* 42(7), 791–798 (2012).
  - 39 Boavida P, Hargunani R, Owens CM, Rosendahl K. Magnetic resonance imaging and radiographic assessment of carpal depressions in children with juvenile idiopathic arthritis: normal variants or erosions? *J. Rheumatol.* 39(3), 645–650 (2012).
  - 40 Muller LS, Avenarius D, Damasio B *et al.* The pediatric wrist revisited: redefining MR findings in healthy children. *Ann. Rheum. Dis.* 70(4), 605–610 (2011).
  - 41 Weiss PF, Arabshahi B, Johnson A *et al.* High prevalence of temporomandibular joint arthritis at disease onset in children with juvenile idiopathic arthritis, as detected by magnetic resonance imaging but not by ultrasound. *Arthritis Rheum.* 58(4), 1189–1196 (2008).
  - 42 Muller L, Kellenberger CJ, Cannizzaro E *et al.* Early diagnosis of temporomandibular joint involvement in juvenile idiopathic arthritis: a pilot study comparing clinical examination and ultrasound to magnetic resonance imaging. *Rheumatology (Oxford)* 48(6), 680–685 (2009).
  - 43 Scott C, Meiorin S, Filocamo G *et al.* A reappraisal of intra-articular corticosteroid therapy in juvenile idiopathic arthritis. *Clin. Exp. Rheumatol.* 28(5), 774–781 (2010).
  - 44 Parra DA, Chan M, Krishnamurthy G *et al.* Use and accuracy of US guidance for image-guided injections of the temporomandibular joints in children with arthritis. *Pediatr. Radiol.* 40(9), 1498–1504 (2010).
  - 45 Tynjala P, Honkanen V, Lahdenne P. Intra-articular steroids in radiologically confirmed tarsal and hip synovitis of juvenile idiopathic arthritis. *Clin. Exp. Rheumatol.* 22(5), 643–648 (2004).
  - 46 Neidel J, Boehnke M, Kuster RM. The efficacy and safety of intraarticular corticosteroid therapy for coxitis in juvenile rheumatoid arthritis. *Arthritis Rheum.* 46(6), 1620–1628 (2002).
  - 47 Collado P, Jousse-Joulin S, Alcalde M, Naredo E, D'agostino M A. Is ultrasound a validated imaging tool for the diagnosis and management of synovitis in juvenile idiopathic arthritis? A systematic literature review. *Arthritis Care Res. (Hoboken)* 64(7), 1011–1019 (2012).
  - 48 Collado P, Naredo E, Calvo C, Crespo M. Assessment of the joint recesses and tendon sheaths in healthy children by high-resolution B-mode and power Doppler sonography. *Clin. Exp. Rheumatol.* 25(6), 915–921 (2007).
  - 49 Spannow AH, Stenboeg E, Pfeiffer-Jensen M, Herlin T. Ultrasound measurement of joint cartilage thickness in large and small joints in healthy children: a clinical pilot study assessing observer variability. *Pediatr. Rheumatol. Online J.* 5, 3 (2007).
  - 50 Spannow AH, Pfeiffer-Jensen M, Andersen NT, Herlin T, Stenbog E. Ultrasonographic measurements of joint cartilage thickness in healthy children: age- and sex-related standard reference values. *J. Rheumatol.* 37(12), 2595–2601 (2010).