



Recent developments and current management of penile cancer

Practice Points

Primary penile tumor section

- A high clinical suspicion and a biopsy are required for the diagnosis of carcinoma *in situ* and invasive penile cancer.
- Penile-preserving surgical techniques have been developed. These operations aim to achieve clear surgical margins while maintaining penile length and function. Many series have confirmed the oncological safety of surgery, but more data are needed on quality of life and measures of both sexual and urinary functional outcome operatively.
- External beam radiotherapy is generally reserved for palliation of inoperable tumors. Brachytherapy as curative treatment appears promising in a few centers. No randomized controlled trials comparing surgery with brachytherapy have been performed to date.

Management of lymph nodes

- The presence of nodal disease is the most important prognostic factor for patients with penile squamous cell carcinomas.
- Approximately half of men will have impalpable inguinal lymph nodes at presentation, of which 20% will harbor occult micro-metastases. Computed tomography–PET and MRI–PET appear promising at detecting metastases, but are not yet in routine practice. To reduce morbidity from unnecessary lymph node dissection (LND), dynamic sentinel lymph node biopsy has been widely accepted as a minimally invasive operation to aid detection of micrometastases, with a false-negative rate of <5%. If the sentinel lymph node contains metastases a complete inguinal LND is performed.
- For men with palpable inguinal lymph nodes at presentation, up to 80% will have metastases. A fine needle aspiration cytology or excisional biopsy is usually performed, followed by a radical inguinal LND. If extranodal spread of disease is found, adjuvant radiotherapy is recommended.
- Minimally invasive surgical techniques have been used for both inguinal and pelvic LND. Robotic-assisted laparoscopic inguinal LND has been shown to be oncologically safe. Data on postoperative complications and learning curves is eagerly awaited.

Penile carcinoma is a rare disease, with over 95% of tumors being squamous cell carcinomas. Due to the low case numbers there has been a paucity of good-quality prospective studies available on which to base best clinical practice. The development of specialist high-volume centers in both the UK and Europe has started to permit multicenter collaboration and analysis of larger cohorts, with a knock-on improvement in patient care. Advances in diagnostic imaging, surgical techniques for both the penis and inguinal regions, and improved delivery of radiotherapy have helped to improve outcomes and quality of life. Molecular biology has started to shed light on the pathogenesis of the disease and the role that human papillomavirus may play. The aim of this article is to give an up-to-date review of the management of penile cancer encompassing the above.

Keywords: carcinoma • penis • sentinel lymph node

Paul Hadway¹, Varun Sahdev¹,
Manit Arya² & Asif Muneer^{*,2}

¹Harold Hopkins Department of Urology,
Royal Berkshire NHS Foundation Trust,
Craven Road, Reading, RG1 5AN, UK

²Department of Urology, University
College Hospital, 235 Euston Road,
London, NW1 2BU, UK

*Author for correspondence:
asif.muneer@uclh.nhs.uk

Future
Medicine part of

fsg

In western Europe and North America, penile cancer is rare. In England and Wales, the annual incidence is between 1.2 and 1.5 per 100,000, accounting for less than 1% of male malignancies [1]. However, the disease is far more prevalent in other countries, accounting for up to 20% of male cancers in parts of South America, Africa and Asia [2]. More than 95% of penile cancers are squamous cell carcinomas (SCC), the remaining 5% comprising melanomas, sarcomas and basal cell carcinomas.

Penile SCC can manifest in many different forms and with varying growth patterns. When visible, the penile lesion can appear as a nodular, ulcerative or an erythematous lesion (Figure 1). Often there is a pathological phimosis covering the tumor, which can only be palpated as a hard mass under the foreskin. Diagnosis of invasive penile cancer tends to be straightforward, unlike that of premalignancy, which may be confused with benign genital dermatoses. Where there is diagnostic uncertainty, a biopsy should be performed in view of the risk of progression from carcinoma *in situ* (CIS) to invasive SCC. It is also important to note that CIS coexists with invasive disease in approximately 25% of cases.

The diagnosis of penile cancer is based on clinical suspicion of malignancy and is confirmed by means of a penile biopsy prior to surgical treatment. A rare exception to this rule would be if a histological diagnosis of malignancy has already been made from a biopsy from a metastasis, most likely sited in an inguinal lymph node in a patient with an obvious penile cancer. It is vital that the inguinal regions are assessed thoroughly at presentation. If patients have palpable inguinal lymph nodes, an ultrasound-guided fine-needle aspiration cytology (FNAC) should be arranged. If the cytology is negative, an excision biopsy or a modified inguinal lymph node dissection can be performed, depending on the pathological features of the primary tumor. Those men

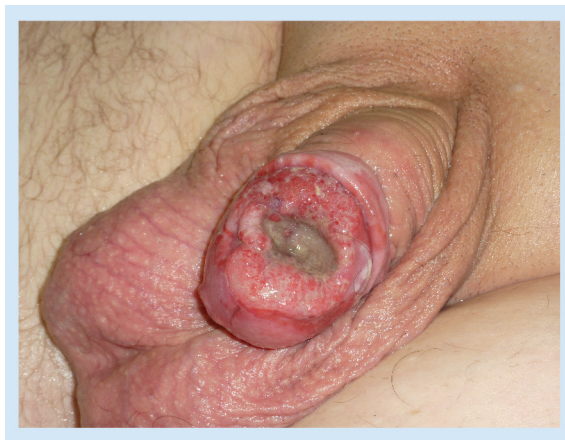

Figure 1. A squamous cell carcinoma of the distal penis requiring a glansectomy.

with impalpable inguinal nodes at presentation still have an approximately 20% risk of micrometastatic disease. After risk stratification of the primary tumor, they will either enter surveillance (CIS, Ta, T1G1 tumors), or be offered bilateral sentinel lymph node biopsies or a bilateral modified inguinal lymph node dissection (T1G2 or higher stage/grade), depending on the unit's preferred technique and expertise.

The current Tumor, Node, Metastasis (TNM) staging for penile cancer was revised in 2009 and the grading, traditionally by Broder's system of well, moderate and poorly differentiated lesions [3], has recently been altered to adopt grades 1–4, with grade 4 being undifferentiated disease.

Over the last two decades, the management of penile cancer has benefited considerably from both improved understanding of the natural history of the disease and cohesive research collaboration. The UK approach has changed significantly, with centralization of patients into high volume centers of excellence where advanced imaging techniques and surgical strategies are employed. Together these advances have resulted in reduced patient morbidity and improved cure rates, from 50% in the 1990s to 80% in recent years [4]. However, it remains that men continue to present after several months or years of symptoms, with a consequent adverse impact on the overall survival, particularly in those patients with systemic, metastatic or nodal disease. If survival rates from penile carcinoma are to be improved further, the education of both the general public and physicians with regards to the risk factors and recognition of the disease at an early stage needs to be addressed.

This article aims to review recent advances made in the management of penile cancer, including that of the primary penile lesion in both CIS and invasive disease. The management of the regional lymph nodes, current chemotherapy trials and the latest viewpoint on prophylaxis with human papillomavirus (HPV) vaccinations and targeted therapies will be discussed, in addition to an overview of recent outcomes and survival data.

Management of the primary penile tumor

Although topical therapy may be sufficient for CIS, higher stage/grade penile cancer management has comprised radical surgery in the form of partial or total penectomy (to allow at least a 2-cm clear margin from the tumor) or radiotherapy (external beam or brachytherapy). While providing excellent locoregional control, radical surgery is associated with an adverse impact on urinary and sexual function, and incurs significant psychological morbidity [5]. On the other hand, radical radiotherapy usually preserves the penis at the cost of higher complication rates when compared

with surgery. Furthermore, recurrence rates may be as high as 40% following external beam radiotherapy, and such cases can prove difficult to detect and treat. That being said, a series of brachytherapy for tumors less than 4 cm in size located on the glans penis has been reported recently. De Crevoisier *et al.* described 144 patients with a median follow-up of 5.7 years, and found a 10-year recurrence rate of 20%. After salvage treatment, 86% were in remission. With regard to complications, 26% developed painful ulceration, 29% urethral stenosis and 5% required penile amputation for necrosis [6]. A randomized controlled trial comparing brachytherapy with surgery in the management of primary penile tumors is lacking in the world literature. In all but a few centers of excellence the mainstay of treatment for the primary tumor is surgical and this is reflected in this review article.

The consensus remains that radical surgery is still required for stage T4, high-grade T3 or large proximal stage T2 disease, but in light of the aforementioned factors there has been a drive to develop penile-preserving techniques for more distal tumors involving the glans penis. Such an approach aims to provide oncological control with a reduction in the anatomical and functional morbidity. There is now considerable literature supporting this surgical strategy. Several authors have presented data disputing the need for a conventional 2-cm resection margin. In one study, examining 64 partial and total penectomy specimens, Agrawal and colleagues found that of 52 grade 1 and 2 tumors, only seven had positive margins 5 mm from the visible tumor, and 25% of grade 3 tumors had microscopic extension up to 10 mm [7]. Hoffman's group studied 14 men who underwent conventional surgery for penile SCC and found that at 33 months postoperatively, none had developed local recurrence, despite 50% having resection margins of ≤ 10 mm [8]. In a larger series, Minhas and coworkers reviewed the resection margins and local recurrence rates in patients undergoing penile-preserving surgery. They reported that 48% had a surgical clearance of ≤ 10 mm, while 90% had a clearance of ≤ 20 mm. With a mean follow-up of 26 months, local recurrence occurred in only 4%. Moreover, with most cases deemed to be surgically salvageable, no compromise in long-term survival is inferred [9].

Early diagnosis and accurate staging is essential for the successful implementation of penile-preserving techniques. In the UK, where only approximately 15% of tumors invade the corpora at presentation, the vast majority of patients can benefit from a more refined surgical strategy. The treatment options available depend on the site and extent of disease and are reviewed below.

Carcinoma *in situ* & superficial verrucous carcinoma (Tis & Ta)

Topical therapy

Although CIS is not a malignancy, it accounts for approximately 10% of penile lesions at diagnosis and its management is worthy of discussion. CIS may arise on the shaft of the penis, eponymously called Bowen's disease, or as one or more red, moist patches on the mucosal surfaces of the glans penis or inner prepuce, known as erythroplasia of Queyrat (EQ) [10]. CIS can be misdiagnosed as a benign skin condition or another penile dermatosis such as candidal balanitis, Zoon's balanitis or lichen planus. It can also co-exist with lichen sclerosus. Thus, it is important that a biopsy is taken to make the diagnosis and determine the most appropriate treatment option. If left untreated, the observed risk of progression to invasive SCC is 5–33% [11].

Circumcision is generally recommended in men with CIS to facilitate the application of topical therapy, abolish the foreskin as a risk factor for progression and allow subsequent surveillance. In the absence of invasive disease, first-line treatment for CIS is topical 5% 5-fluorouracil (5-FU) cream, usually applied on alternate days for 6 weeks. This therapy is safe and generally well tolerated, and response rates close to 100% at 5 years have been demonstrated in small studies (<10 patients) [12]. Further topical therapy using 5% imiquimod (an immune-modulating cream) in a similar regimen can be offered to patients who do not respond or develop recurrence. Case reports have been published describing success of this approach [13].

Laser therapy

Laser therapy has been used in the treatment of both CIS and low-grade/stage invasive disease. It produces excellent functional and cosmetic results and may be carried out in the outpatient setting. CO₂ and Neodymium:YAG (Nd:YAG) are the most frequently used types. The main difference between these lasers is the depth of penetration: the CO₂ laser has a longer wavelength and does not penetrate human tissues as well as Nd:YAG. The latter can achieve a depth of 4–6 mm, but any tumor invading to greater than 6 mm is unsuitable for laser surgery. It is therefore essential to assess tumor depth, with either imaging (ultrasound or MRI) or biopsy, before embarking on this treatment option. It should be noted, however, that all of these modalities have limitations and run the risk of under-representing the carcinoma.

A study by Windhal and Hellsten in 1995 reported two recurrences among 19 men managed with CO₂ laser alone (eight men) or in combination with Nd:YAG (11 men). Both recurrences were salvageable, with further laser therapy and were found to be dis-

ease free at 12 and 52 months [14]. Shirahana and colleagues demonstrated the importance of case selection [15]. They included patients with carcinomas less than 6 mm thick, based on imaging studies. Of ten cases of CIS/stage T1 carcinoma, all were free of disease at 6 years. Two further patients with stage T2 carcinoma, treated aggressively with a combination of chemoradiation and adjuvant laser therapy, were also described. Both were clear from recurrence at 7 years follow-up. More recently, a study by Meijer and colleagues described 44 patients with tumors ranging from Tis to T2 managed with laser therapy. They reported a local recurrence rate of 48%, with 23% progressing during follow-up to develop nodal spread. A total of 80% of the latter had presented with T2 disease, hence highlighting the danger of disease progression in higher stage and grade cases [16].

Overall, as with any topical therapy, local recurrences are higher than with conventional surgery and close follow-up is essential after treatment. Complications of laser therapy include bleeding, pain and preputial lymphoedema, and occur in 1–7% [17–19].

Total glans resurfacing

Although the topical therapies described above have a high success rate, they all have limitations and side effects. They rely upon a high degree of patient compliance and can be awkward to apply, often causing discomfort and pain. Furthermore, a risk of insufficient treatment and recurrence is posed by the diffuse nature of EQ, and such patients therefore need careful long-term surveillance. The technique of total glans resurfacing (TGR) offers a surgical alternative for nonresponsive disease or recurrence. This procedure was first described by Bracka for the treatment of severe lichen sclerosis [20], but has been adapted for use in CIS and stage Ta penile cancer in extensive or relapsing disease [21]. Just the glans epithelium and subepithelial tissues are removed before frozen sections are taken from the underlying corpus spongiosum to confirm that there is no invasive component. The corpus spongiosum is then covered with a split-thickness skin graft.

Watkin and coworkers published early outcome data for ten patients treated with TGR. At a median follow-up of 30 months (range: 7–45 months) there was no evidence of disease recurrence. The grafts took successfully in all cases and produced good cosmetic results. All men who had been sexually active prior to surgery regained this function within 3–5 months [21]. The medium-term outcomes of TGR have also recently been reported by Shabbir and colleagues. The group's results confirm TGR as a safe and reproducible technique, but they did report a 28% positive surgical margin rate requiring further surgery [22].

There are several advantages of TGR over the more conventional alternatives. Complete excision of the glans and subcoronal tissues means the chance of local recurrence is minimized, although long-term follow-up data are awaited. Moreover, TGR is the only technique that obtains an undamaged histological specimen to confirm complete excision of disease. In addition, if the graft heals well, TGR restores the penile anatomy with minimal scarring. It is particularly suitable for younger men in whom operative risk is very low and cure is paramount.

T1 lesions confined to the prepuce Circumcision/wide local excision

Circumcision is the most common surgical procedure performed in penile cancer and aims for primary cure in low-stage preputial disease [23]. If necessary, for more extensive lesions, the excision may be extended onto the penile shaft skin or coronal sulcus [24,25]. Resection margin CIS can be treated topically with 5% 5-FU or imiquimod cream and closely observed. Circumcision is also indicated prior to radiotherapy, to improve the accuracy of targeting and tumor definition. Postradiotherapy, circumcision avoids the complication of phimosis and facilitates surveillance for local recurrence.

Close follow-up is indicated after circumcision, as recurrence rates of up to 30% are reported [26,27], the majority of these occurring in the first 2 years [28]. Salvage surgery has a high success rate and appears not to affect the long-term disease-specific survival [24,29].

T1 lesions involving the glans penis

Several options are available for these lesions and careful case selection is important. For small (<2 cm), low-grade (G1/2) lesions at sufficient distance from the external meatus, WLE and primary closure may be possible. For slightly larger tumors (<4 cm), WLE followed by a full- or split-thickness skin graft to minimize distortion of the glans is an option. However, these approaches are complicated by recurrence in up to 50% of men, mostly occurring in the first two postoperative years [30]. Therefore, close surveillance and patient education is vital for the early detection of recurrence. In most cases, such disease can be managed successfully with further surgery, such as total glansectomy ([TG], see below), without compromising overall survival [29,31]. There is an argument that TG with skin graft reconstruction is an appropriate first-line treatment for larger tumors in this group. Brachytherapy for tumors <4 cm in size in previously circumcised men is another option in a few centers of excellence, as previously discussed [6].

T2 lesions confined to the glans penis

Although these tumors can be successfully managed with conventional partial penectomy, such patients can now benefit from penile-preserving surgery. Bracka was the first to propose glansectomy for men with penile cancer confined to the glans [32], and this technique may be appropriate for up to 80% of all cases of invasive penile cancer. The extent of tumor invasion can be assessed with preoperative gadolinium-enhanced MRI combined with an artificial erection (Figure 2) [33].

Total glansectomy

This technique involves the excision of the glans penis from the corporal heads. A split-thickness skin graft is then harvested from the thigh and carefully quilted to the exposed corpora to create a neo-glans (Figure 3) [28].

A novel dressing technique that allows immediate postoperative mobilization has recently been described by Malone *et al.* (Figure 4) [34]. Instead of ‘quilting’ the skin graft to the neoglans, a gauze tie-over dressing, soaked in proflavine, is sutured to the corona proximally and the newly formed meatus distally. Over 80% of the 29 patients described were discharged from hospital within 48 h with a urethral catheter. Catheters and dressings were removed 10 days postoperatively, and graft take and cosmetic results were reported as excellent [34].

With regard to outcomes, Pietrzak and coworkers found that of 39 patients who underwent TG and skin graft reconstruction, all were disease free at 2 years [28]. The same group have published medium-term outcome data on a cohort of 72 patients (65 new tumors and seven recurrences postradiotherapy; 49% T1, 51% T2) undergoing glansectomy and reconstruction. At a mean follow-up of 27 months (range: 4–68 months), three late recurrences (6%) were reported. No disease-specific mortality was incurred, however, and very good functional and cosmetic results were described [35].

With the aim of reducing the morbidity that may be associated with skin grafts, novel techniques have been developed whereby primary closure after glans excision is achieved with advancement of the shaft skin and urethral mucosal eversion. In a study of five men (tumor stages T1G2 [n = 2], T1G3 [n = 2] and T2G2 [n = 1], Brown and coworkers described subtotal glans excision without grafting, where the urethral meatus was sutured down to the distal corpora and the penile skin advanced and approximated to it [36]. They were able to preserve the urethral meatus while excising the glans penis (clearance margins ≥ 5 mm on frozen sections), and found no disease recurrence after a mean follow-up of 1 year. An advantage com-

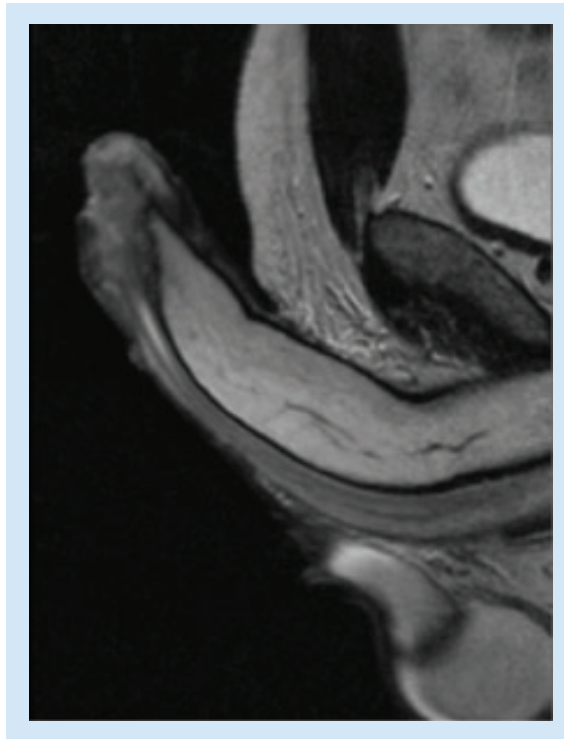


Figure 2. MRI with caverject of a penile carcinoma.

pared with glansectomy is that urethral preservation results in fewer problems with spraying during micturition. However, this procedure is not suitable for any patient where tumor invades the urethra. Furthermore, patients need to be counselled regarding the unusual postoperative appearance of the penis.

Gulino and colleagues have pioneered another novel modification to avoid skin grafting in which the entire urethra is mobilized from the corpora. An approximately 3-cm opening is then made in the ventral aspect of the urethra, which is fashioned to cover the corporal heads [37].

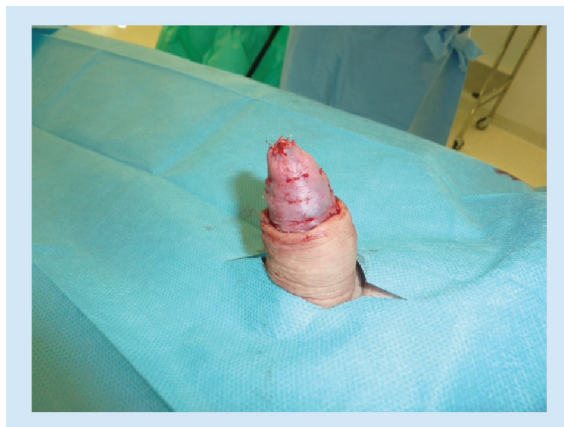

Figure 3. Postglansectomy appearance with application of a split thickness skin graft.

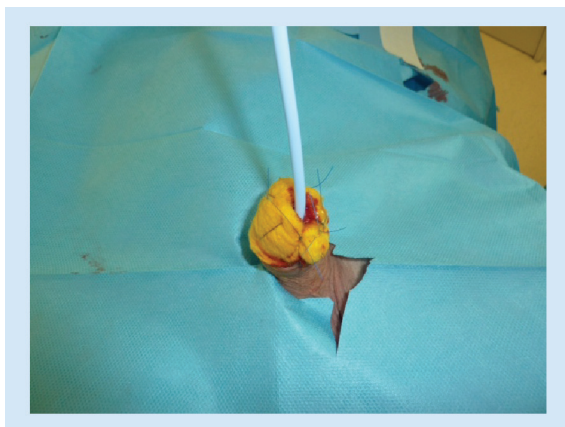


Figure 4. Tie over dressing for graft application following glansectomy.

T2 tumors invading the corpora cavernosa Distal corporectomy (partial penectomy) & split-thickness skin grafting

More extensive surgery is necessary if there is evidence of corporal involvement either clinically or on MRI, or if intraoperative frozen sections are positive (Figure 4). The operation is similar to TG but includes resection of the distal corporal bodies and adjacent urethra. A rounded neo-glans is then reconstructed from the corpora. The penis can then be lengthened by 2–3 cm by dividing the penile suspensory ligaments beneath the pubic arch [38], and tethering and tension reduced by a dorsal V-Y skin advancement and a ventral V-Y phalloplasty to lower the insertion of the scrotal skin [39]. Despite these maneuvers, not all patients will have adequate penile length for micturition while standing or for sexual intercourse. Therefore, patients need to be counselled preoperatively and expectations managed accordingly. Case selection and close follow-up are important. The technique can also be used to salvage recurrent disease [40].

Salvage surgery postradiotherapy

Following radical radiotherapy, up to 40% of men will require salvage surgery for local recurrence [41]. An additional challenge is the difficulty in detection of such disease consequent to the chronic skin changes associated with radiotherapy. Watkin's group recently published their data from 17 cases presenting with recurrence at a mean of 9 years (range: 1–29 years) postradiotherapy. All underwent salvage surgery, and 14 were treated with TG. They described some technical challenges due to friable noncompliant tissues, but postoperatively all skin grafts took well. After a mean of 3 years (range: 1–6 years) follow-up, 16 out of 17 patients were recurrence free and there was no incidence of nodal disease. The authors suggested that all chronic ulceration and nonhealing tissue in such cases should be treated as malignant unless proven otherwise [40].

Mohs micrographic surgery

This technique involves the excision of the penile lesion in thin layers with simultaneous microscopic assessment of the underside of the specimen along with the use of frozen sections [42]. The aim of Mohs micrographic surgery (MMS) is to preserve as much healthy penile tissue as possible while ensuring clear surgical margins. Complication rates of 1.2–3.6% have been reported, including residual urethral disease, wound dehiscence, meatal stenosis and a recurrence rate of 32% [43]. The technique is time consuming, requires highly skilled personnel, and can leave the glans penis misshapen, requiring reconstructive surgery. While most appropriate for smaller Ta and T1 lesions, in expert hands the technique has been used to treat distal penile tumors up to T3 involving the distal urethra.

Management of inguinal lymph nodes

Lymph node metastasis is the most important prognostic factor for patients with penile cancer [44]. Although more than 50% of patients with SCC have no palpable inguinal nodes at the time of presentation, up to 20% harbor occult micrometastases (<2 mm) in this location [45]. Conventional imaging techniques remain inaccurate for detecting such disease [46]. The use of ¹⁸F-FDG-PET combined with CT, however, appears very promising in several small series. Schlenker and coworkers reported on its use in 35 patients with invasive penile SCC. The reference standard for the technique was either histology post-lymph node dissection or clinical surveillance (mean: 48.4 months; range: 31–68 months). They reported a sensitivity of 88.2% and a specificity of 98.1%, where two out of 70 inguinal regions had missed metastases of 5 and 7 mm in size, respectively [47]. Data confirming the reproducibility of this technique are awaited.

In view of the problem with inadequate imaging, prophylactic bilateral inguinal lymph node dissection (LND) may be undertaken. This approach is associated with high cure rates, but the operation historically has a high level of morbidity (30–50%) and a significant mortality (3%) [48], although more recent series report complication rates as low as 10.3% [49]. Bearing in mind that up to 80% of men will prove to have negative nodes, much of this morbidity is incurred with no clinical benefit. In support of this, a recent two-center review of 342 patients with clinically impalpable inguinal nodes undergoing sentinel lymph node biopsy (SLNB) concluded that 77% of men in the EAU high-risk group for metastases could have had an unnecessary inguinal LND [50]. Furthermore, there is little evidence that using predictive factors for nodal metastasis (e.g., stage, grade, depth of infiltration, lymphovascular invasion) to identify patient subgroups

more likely to benefit from prophylactic LND avoids inappropriate surgery [50–53].

Sentinel lymph node biopsy

This technique aims to identify and subsequently remove specific lymph nodes that predict the nodal status of patients with a malignancy. Its use in penile cancer dates back to 1977, at which time a purely anatomical approach was used to locate the sentinel lymph node (SLN) [54]. This proved difficult to reproduce and the technique fell out of favor [55].

During the 1990s, the use of nanocolloids and patent blue dye was adopted to aid localization of the SLN both pre- and intra-operatively. This produced excellent results in malignant melanoma and breast cancer, and consequently SLNB is now routine in the management of these conditions [56–58]. This success fostered renewed wider interest, particularly among those researching penile carcinoma [59].

Since 1994, The Netherlands Cancer Institute (NKI) have pioneered the use of dynamic lymphoscintigraphy and SLNB in the treatment of penile cancer (Figure 5) [60]. Over a 10-year period, SLNs were identified in 98% of 123 patients with $\geq T2$ tumors and clinically impalpable inguinal nodes, and 23% of excised nodes contained metastatic disease. The initially unsatisfactory false-negative rate (FNR) of 18% resulted in multiple protocol changes, including the addition of preoperative ultrasonography (US) with or without FNAC, and serial sectioning of excised specimens prior to the use of specific immunohistochemical stains. The NKI's current FNR is approximately equal to 5% [61]. The technique is reproducible, with similar results reported in other centers worldwide [62,63]. Significantly, improved outcome has been demonstrated for men undergoing immediate LND for occult nodal metastases detected by SLNB. A disease-specific survival at 3 years of 84% is reported, compared with only 35% for cases with no palpable nodes treated by clinical surveillance [64].

A recent systematic review and meta-analysis of the accuracy of SLNB based on 19 studies found favorable pooled sensitivity (88%; 95% CI: 83–92) and detection rates (90.1%; 95% CI: 83.6–94.1). The authors also concluded that using radiotracer and blue dye for SLN mapping, and including only cN0 disease, confers the highest sensitivity and detection rate [65].

With the emergence of long-term data confirming SLNB safety and benefit in both reducing morbidity from unnecessary LND and improved 5-year cancer-specific survival, it is clear that SLNB has been a major advance for patients with penile cancer [63,66]. The latest EAU guidelines recommend SLNB when available in patients with clinically impalpable inguinal nodes and intermediate- to high-risk disease [67].

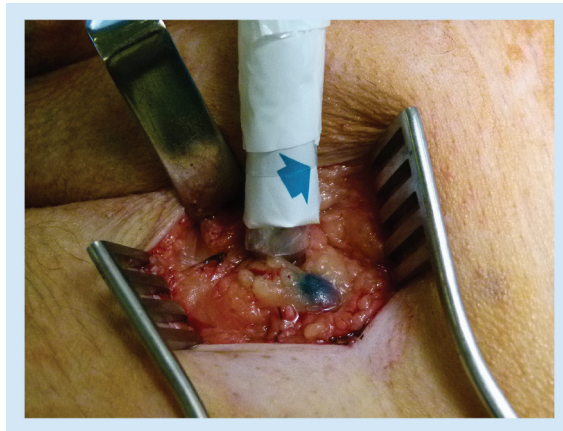


Figure 5. Sentinel lymph node biopsy showing a node detected using a gamma probe and with patent blue dye.

An exciting modification to the SLNB technique to aid intraoperative visualization has recently been described. A hybrid fluorescent–radioactive tracer, indocyanine green- ^{99m}Tc -nanocolloid, was compared with the standard technique using blue dye and ^{99m}Tc -nanocolloid. The authors from the NKI found that by using a fluorescence camera intraoperatively to visualize the SLN aided detection, with 95% of SLNs being seen as fluorescent compared with 54% being seen with standard blue dye [68].

In an attempt to reduce the morbidity from open inguinal lymph node surgery, several groups have recently reported their experience of video-endoscopic inguinal surgery (both laparoscopic and robotic assisted). In a Phase I study specifically examining oncological adequacy, a group from Texas have described the robotic assisted video endoscopic inguinal lymphadenectomy (RAVEIL) technique. In ten patients 19 RAVEIL operations were performed, followed by an open inguinal lymph node dissection to look for missed nodes. They concluded that in 18 out of 19 operations (94.7%) an adequate dissection was achieved and all nodes containing disease had been detected. Although promising, this work needs to be expanded to allow assessment of complications and examine reproducibility in other units [69].

Overall survival

The majority of research regarding survival from penile cancer comprises individual studies with relatively low patient numbers. However, Verhoeven and coworkers examined the population-based survival of patients with penile cancer in Europe and the USA using data from registries contributing to the European Network for Indicators on Cancer (EUNICE) Survival Working Group and its American equivalent, the Surveillance, Epidemiology and End Results (SEER) program [70].

This incorporated data from 3297 European and 1820 American penile cancer patients diagnosed with penile cancer from 1985 to 2007.

They reported that in Europe, overall 5-year survival increased marginally, but not to statistical significance, from 65 to 70% between 1990 and 2007. Within this group, a notable exception was northern Europe, where an improvement from 63 to 77% was seen within the same time frame. Interestingly, the outlook was worse in the USA, with a statistically significant decrease in 5-year survival from 72 to 63% from 1990 to 2007. Furthermore, there was no significant improvement in age-specific survival estimates during the period measured [70]. Further European data from the Surveillance of Rare Cancers in Europe (RARECARE) group revealed a similar overall 5-year survival rate of 69% in patients with penile cancer diagnosed from 1995 until 2002 [71].

There is a general consensus that age predicts mortality from penile cancer. Verhoeven *et al.*'s study showed a significant increased risk of disease-specific mortality with increasing age [70], and Sant and coworkers found that 5-year survival after the age of 75 was as low as 35% [72]. The reason behind this is unclear, as although there were insufficient data recorded in the EUNICE registries, there is no evidence for more advanced disease stage in penile cancer patients presenting later in life [70]. This is supported by Graafland and colleagues, who carried out a study of 2000 patients diagnosed with penile cancer in The Netherlands between 1989 and 2006, and found that stage distribution did not vary significantly between age groups [73].

The reasons for the overall lack of improvement in survival is a matter for debate, and some authors postulate that it is simply because the impact of newer approaches such as SLNB have not had time to become apparent in the data. This may explain the emergence of more promising data from Northern Europe, as this region was the first to adopt the technique [70]. Other authors argue that the poor outcome data should prompt centralization of the treatment of penile cancer, only taking place in specialized units with a higher patient volume [71,72].

Human papillomavirus

Several types of HPV have been identified in premalignant penile lesions and approximately 50% of penile cancers express HPV type 16 or 18 [74,75]. Significantly, an association between HPV status and histological grade has also been reported, with higher grade tumors being more likely to be HPV positive [76]. There are two vaccines available that protect against HPV: a bivalent vaccine that provides protection against HPV 16 and 18, and a quadrivalent vaccine that targets

HPV 6, 11, 16 and 18. The latter is approved for preventing HPV-related disease in males [74], and both have been shown to be effective and safe [75]. In the UK, immunization with the bivalent vaccine has been in effect since 2008 for girls aged 12–13 years with the aim of preventing cervical cancer, but no such scheme is in place for boys.

Marty and coworkers used a computer-based model to examine the incremental benefit of vaccinating boys and girls using the quadrivalent vaccine versus girls-only vaccination, looking for several diseases caused by HPV including penile cancer [74]. They found that vaccination of both girls and boys could reduce the incidence of penile cancer by 68% based on a figure of 70% coverage. Despite this, a national vaccination program aimed solely at preventing HPV-related penile cancer is unlikely to be cost effective in the UK, but in countries with a higher prevalence of the disease there may be a stronger case for such action [75].

If one considers the overall benefits of vaccinating men with regards to preventing other diseases associated with HPV and the increased herd immunity, then an economic case can be made [77]. Indeed, the Advisory Committee on Immunizations Practices from the CDC has recently changed its guidelines in favor of immunizing boys and men aged between 13 and 26 years in the USA [78].

Chemotherapy

Systemic chemotherapy has been used mainly in the palliative setting for metastatic and advanced loco-regional disease that is not amenable to surgery. It also has a role in downstaging locally advanced tumors prior to surgery. Single chemotherapeutic agents in the 1970s were characterized by poor response rates and high levels of toxicity [79]. As a result, combination regimens were used throughout the 1990s, and from these it became apparent that cisplatin is a key chemotherapeutic agent in the treatment of SCC of the penis [80]. Taxane-based regimens then became more popular in the 2000s, with three agent combinations dominating [81]. These included the Dexeus group's regimen consisting of cisplatin, methotrexate and bleomycin [82]. Their initial study reported promising results with only moderate side effects, but with wider adoption of this protocol, poorer results and more severe side effects were seen [82]. More recent combination regimens comprising differing combinations of cisplatin, 5-FU and paclitaxel have shown promise in the neoadjuvant treatment of penile cancer [83,84].

Adjuvant & neoadjuvant treatment

The EAU guidelines recommend adjuvant chemotherapy for N2–3 disease. This is based on a study of 25

patients that revealed an 84% long-term disease-free survival rate [67]. In men with fixed palpable nodes, neoadjuvant chemotherapy appears promising. In 2007, Leijte and colleagues showed that 12 out of 19 patients receiving five different neoadjuvant chemotherapy regimens showed a response, with eight achieving long-term disease-free survival after subsequent surgery [85]. Two further studies published in 2007 and 2010 reported up to a 50% response using paclitaxel, cisplatin and ifosfamide [83,84]. The EAU guidelines therefore recommend neoadjuvant chemotherapy followed by lymph node dissection in patients with fixed or relapsed lymph node metastases [67].

Adjuvant radiotherapy may improve locoregional control in patients with extensive metastases and/or extranodal spread, but control is achieved at the cost of severe side effects including lymphedema and pain [67].

Molecular biology of penile cancer

EGF receptor

The cell-surface receptor EGF receptor (EGFR) is involved in a key pathway that controls intracellular signalling [86]. Several types of ligands bind to this receptor to activate intracellular pathways that regulate processes such as cell proliferation, differentiation and apoptosis [87]. Overexpression of EGFR is a key characteristic in many tumors including brain, lung, prostate and stomach cancers [88]. This has been shown to be associated with uncontrolled cell division and proliferation of tumors by angiogenesis, as well as protecting tumor cell from undergoing apoptosis.

Lavens and colleagues showed overexpression of EGFR in 17 patients diagnosed with penile SCC [87], and Di Lorenzo and coworkers found similar results in 30 patients but were unable to identify specific mutations known to cause other tumors associated with EGFR overexpression [89]. A more recent paper by the latter group demonstrated that the presence of cytosolic phosphorylated EGFR predicted recurrence and survival [90]. They therefore put the case forward for the use of phosphorylated EGFR status in informing the need for adjuvant therapy in patients with N0 and N1 disease.

Other mutations

Gou examined the expression of *EGFR* and *RASSF1A*, as well as the mutation status of *KRAS* and *BRAF*, in 150 patients with penile SCC [91]. Once again, *EGFR* overexpression was found in all cases, but only 3.42% expressed *RASSF1A*, one patient displayed the *KRAS* mutation and none expressed the *BRAF* mutation. This conflicts somewhat with a series of 28 cases from Spain where *KRAS* mutations were found in 22% of tumors [92]. Andersson *et al.* also reported mutations

in *PIK3CA*, *HRAS* and *KRAS* [93]. Stankiewicz and colleagues found HER-3 and -4 protein overexpression in penile SCC. Further analysis of their data revealed that HPV-positive tumors were more associated with HER-2 expression and less associated with p-EGFR overexpression [94]. Additional work by this group showed HPV positivity was also associated with p16 and p21 expression and RB suppression in a series of 148 patients [95].

With regard to p53 mutations, some studies report an association with lymph node metastasis and poor survival, but others do not [96,97]. Interestingly Golinjanin and coworkers found that COX-2 and prostaglandin-E synthase 1 are highly expressed in dysplasia, penile intraepithelial neoplasia and carcinoma [98]. This suggests a mechanism for inflammation in the pathogenesis of penile SCC as well raising the possibility of a therapeutic role for COX-2 inhibitors.

Targeted therapy

Given the key role that EGFR appears to play, several studies have examined the use of the monoclonal antibodies panitumumab and cetuximab in penile cancer. Carthorn and colleagues administered monoclonal antibodies together with differing combinations of platinum-based regimens to 13 patients with advanced penile SCC [99]. Median time to progression was 3.4 months and overall survival was 9.8 months, although four patients survived longer, which compared favorably to results from chemotherapy [100].

Tyrosine kinase inhibitors may have an important role in targeting angiogenesis in penile SCC. Zhu and colleagues studied the effects of sorafenib and sunitinib on angiogenesis in six patients with penile SCC refractory to chemotherapy treatment [101]. One patient responded partially and four had stable disease; however, one patient died of sepsis another suffered a ruptured femoral vein.

Conclusion

The last two decades has seen major advances for men diagnosed with penile cancer. Penile-preserving techniques provide a surgical option with preservation of sexual and voiding function. The advent of SLNB has proved to be a safe and reproducible option for patients with impalpable inguinal nodes. Data from the NKI in The Netherlands show a clear improvement in 5-year survival, which may be due to the introduction of the technique for patients with clinically impalpable inguinal lymph nodes. Furthermore, centralization of penile cancer patients to centers of excellence in both the UK and several European countries has allowed for greater experience to be gained by a few and improved research collaboration to take place.

Future perspective

As highlighted throughout this review, the diagnosis and management of men with penile cancer is continually evolving. Several areas are key to an ongoing improvement in outcome. First, increased education and awareness of the early signs of disease among both the general public and healthcare professionals are necessary. A significant impact on disease prevention may be achieved through childhood circumcision and HPV vaccination, particularly in regions of high disease prevalence.

With regard to diagnosis, there is current progress in noninvasive imaging techniques to detect both regional and distant metastatic disease. ¹⁸F-FDG-PET/MRI is currently being trialed and may become the gold standard staging investigation within 5 years.

In terms of management of the penile tumor, a randomized controlled trial comparing penile-preserving surgical techniques and brachytherapy should be performed, looking at effectiveness and quality of life outcomes. Moreover, multimodal management of advanced disease needs to be assessed in a trial setting. With the development of specialist, high-volume

centers such a prospective study could become a reality within the next decade. A further consideration is that with the widespread use of robotic surgery in other areas of urological oncology, the next few years may see routine use of robotic-assisted inguinal and pelvic lymph node dissections in an attempt to reduce postoperative pain and complications.

Finally, understanding of the disease and its pathogenesis will occur through the use of molecular biology and proteomics within the next 5 years. Hopefully this will translate into improvements in clinical practice through targeted therapy within 10 years.

Financial & competing interests disclosure

The authors have no relevant affiliations or financial involvement with any organization or entity with a financial interest in or financial conflict with the subject matter or materials discussed in the manuscript. This includes employment, consultancies, honoraria, stock ownership or options, expert testimony, grants or patents received or pending, or royalties.

No writing assistance was utilized in the production of this manuscript.

References

- 1 Cancer trends in England and Wales, 1950–1999. www.statistics.gov.uk
- 2 Pow Sang MR, Benavente V, Pow Sang JE *et al.* Cancer of the penis. *Cancer Control* 9, 305–314 (2002).
- 3 Broders AC. Squamous cell epithelioma of the skin. *Ann. Surg.* 73(2), 141–160 (1921).
- 4 Pizzocaro G, Algaba F, Horenblas S *et al.* EAU Penile Cancer Guidelines 2009. *Eur. Urol.* 57(6), 1002–1012 (2010).
- 5 Opjordsmoen S, Fossa SD. Quality of life in patients treated for penile cancer. A follow-up study. *Br. J. Urol.* 74(5), 652–657 (1994).
- 6 de Crevoisier R, Slimane K, Sanfilippo N *et al.* Long-term results of brachytherapy for carcinoma of the penis confined to the glans (N- or NX). *Int. J. Radiat. Oncol. Biol. Phys.* 74(4), 1150–1156 (2009).
- 7 Agrawal A, Pai D, Ananthakrishnan N, Smile SR, Ratnakar C. The histological extent of the local spread of carcinoma of the penis and its therapeutic implications. *BJU Int.* 85(2), 299–301 (2000).
- 8 Hoffman M, Renshaw A, Loughlin KR. Squamous cell carcinoma of the penis and microscopic pathologic margins. How much margin is needed for local cure? *Cancer* 85(7), 1565–1568 (1999).
- 9 Minhas S, Kayes O, Hegarty P *et al.* What surgical resection margins are required to achieve oncological control in men with primary penile cancer? *BJU Int.* 96(7), 1040–1043 (2005).
- 10 Goette DK. Review of erythroplasia of Queyrat and its treatment. *Urology* 8(4), 311–315 (1976).
- 11 Malek RS. Laser treatment of premalignant and squamous cell lesions of the penis. *Lasers Surg. Med.* 12(3), 246–253 (1992).
- 12 Goette DK, Elgart M, DeVillez RL. Erythroplasia of Queyrat. Treatment with topically applied fluorouracil. *JAMA* 232(9), 934–937 (1975).
- 13 Micali G, Nasca MR, Tedeschi A. Topical treatment of intraepithelial penile carcinoma with imiquimod. *Clin. Exp. Dermatol.* 28(Suppl. 1), 4–6 (2003).
- 14 Windahl T, Hellsten S. Laser treatment of localised squamous cell carcinoma of the penis. *J. Urol.* 154(3), 1020–1023 (1995).
- 15 Shirahama T, Takemoto M, Nishiyama K *et al.* A new treatment for penile conservation in penile carcinoma: a preliminary study of combined laser hyperthermia, radiation and chemotherapy. *Br. J. Urol.* 82(5), 687–693 (1998).
- 16 Meijer RP, Boon TA, van Venrooij GE, Wijburg CJ. Long-term follow-up after laser therapy for penile carcinoma. *Urology* 69(4), 759–762 (2007).
- 17 Windahl T, Anderson SO. Combined laser treatment for penile carcinoma: results after long-term follow-up. *J. Urol.* 169(6), 2118–2121 (2003).
- 18 Tietjen DN, Malek RS. Laser therapy of squamous cell dysplasia and carcinoma of the penis. *Urology* 52(4), 559–565 (1998).
- 19 Bandieramonte G, Colecchia M, Mariani L *et al.* Penoscopically controlled CO₂ laser excision for conservative treatment of *in situ* and T1 penile carcinoma: report of 224 patients. *Eur. Urol.* 54(4), 875–882 (2008).
- 20 Depasquale I, Park AJ, Bracka A. The treatment of balanitis xerotica obliterans. *BJU Int.* 86(4), 459–465 (2000).

- 21 Hadway P, Corbishley CM, Watkin NA. Total glans resurfacing for premalignant lesions of the penis: initial outcome data. *BJU Int.* 98(3), 532–536 (2006).
- 22 Shabbir M, Muneer A, Kalsi J, Shukla CJ, Zacharakis E, Garaffa G *et al.* Glans resurfacing for the treatment of carcinoma *in situ* of the penis: surgical technique and outcomes. *Eur. Urol.* 59(1), 142–147 (2011).
- 23 Bissada NK. Conservative extirpative treatment of cancer of the penis. *Urol. Clin. N. Am.* 19(2), 283–292 (1992).
- 24 McDougall WS, Kirchner FK, Edward RH, Killian LT. Treatment of carcinoma of the penis: the case of primary lymphadenectomy. *J. Urol.* 136(1), 38–41 (1986).
- 25 Das S. Penile amputation for the management of primary carcinoma of the penis. *Urol. Clin. N. Am.* 19(2), 277–282 (1992).
- 26 Pizzocaro G, Piva L, Tana S. Up-to-date management of carcinoma of the penis. *Eur. Urol.* 32(1), 5–15 (1997).
- 27 Colberg JW, Andriole GL. Surgical management of penile cancer. In: *Comprehensive Textbook of Genitourinary Oncology*. Williams & Wilkins, MD, USA, 1103–1109 (1999).
- 28 Pietrzak P, Corbishley C, Watkin NA. Organ sparing surgery for invasive penile cancer. Early follow-up data. *BJU Int.* 94(9), 1253–1257 (2004).
- 29 Lindegaard JC, Nielsen OS, Lundbeck FA, Mamsen A, Studstrup HN, von der Maase H. A retrospective analysis of 82 cases of cancer of the penis. *Br. J. Urol.* 77(6), 883–890 (1996).
- 30 Horenblas S, Van Tinteren H. Squamous cell carcinoma of the penis. IV. Prognostic factors of survival: analysis of tumour, nodes, and metastatic classification system. *J. Urol.* 151(5), 1239–1243 (1994).
- 31 Lont AP, Gallee MPW, Meinhardt W, van Tinteren H, Horenblas S. Penis onserving treatment for T1 and T2 penile carcinoma: clinical implications of a local recurrence. *J. Urol.* 176(2), 575–580 (2006).
- 32 Bracka A. Organerhaltende operationstechnik bei karzinomen der glans penis. *Akt. Urol.* 27, I–VI (1996).
- 33 Scardino E, Villa G, Bonomo G *et al.* Magnetic resonance imaging combined with artificial erection for local staging of penile cancer. *Urology* 63(6), 1158–1162 (2004).
- 34 Malone PR, Thomas JS, Blick C. A tie over dressing for graft application in distal penectomy and glans resurfacing: the TODGA technique. *BJU Int.* 107(5), 836–840 (2011).
- 35 Smith Y, Hadway P, Biedrzcki O, Perry MJA, Corbishley C, Watkin NA. Reconstructive surgery for invasive squamous carcinoma of the glans penis. *Eur. Urol.* 52(4), 1179–1185 (2007).
- 36 Brown CT, Minhas S, Ralph DJ. Conservative surgery for penile cancer: subtotal glans excision without grafting. *BJU Int.* 96(6), 911–912 (2005).
- 37 Gulino G, Sasso F, Falabella R *et al.* Distal urethral reconstruction of the glans for penile carcinoma: results of a novel technique at 1-year follow-up. *J. Urol.* 178(3), 941–944 (2007).
- 38 Smith Y, Hadway P, Ahmed S *et al.* Penile preserving surgery for male distal urethral carcinoma. *BJU Int.* 100(1), 82–87 (2007).
- 39 Miranda-Sousa A, Keating M, Moreira S, Baker M, Carrion R. Concomitant ventral phalloplasty during penile implant surgery: a novel procedure that optimizes patient satisfaction and their perception of phallic length after penile implant surgery. *J. Sex Med.* 4(5), 1494–1499 (2007).
- 40 Shabbir M, Hughes BE, Swallow T, Corbishley C, Perry MJ, Watkin N. Management of chronic ulceration after radiotherapy for penile cancer. *J. Urol.* 179(4), S273 (2008).
- 41 McLean M, Ahmed M, Warde P *et al.* The results of primary radiation therapy in the management of squamous cell carcinoma of the penis. *Int. J. Radiat. Oncol. Biol. Phys.* 25(4), 623–628 (1993).
- 42 Mohs FE, Snow SN, Larson PO. Mohs micrographic surgery for penile tumours. *Urol. Clin. N. Am.* 19(2), 291–304 (1992).
- 43 Shindel AW, Mann MW, Lev RY *et al.* Mohs micrographic surgery for penile cancer: management and long-term follow-up. *J. Urol.* 178(5), 1980–1985 (2007).
- 44 Ornellas AA, Seixas AL, Marota A, Wisnesky A, Campos F, De Moraes JR. Surgical treatment of invasive squamous cell carcinoma of the penis: retrospective analysis of 350 cases. *J. Urol.* 151(5), 1244–1249 (1994).
- 45 Abi-Aad AS, DeKernion JB. Controversies in ilioinguinal lymphadenectomy for cancer of the penis. *Urol. Clin. N. Am.* 19(2), 319–324 (1992).
- 46 Horenblas S, Van Tinteren H, Delemarre JF, Moonen LM, Lustig V, Kroger R. Squamous cell carcinoma of the penis: accuracy of tumor, nodes and metastasis classification system, and role of lymphangiography, computerized tomography scan and fine needle aspiration cytology. *J. Urol.* 146(5), 1279–1283 (1991).
- 47 Schlenker B, Scher B, Tiling R *et al.* Detection of inguinal lymph node involvement in penile squamous cell carcinoma by ¹⁸F-fluorodeoxyglucose PET/CT: a prospective single-center study. *Urol. Oncol.* 30(1), 55–59 (2012).
- 48 Bevan-Thomas R, Slaton JW, Pettaway CA. Contemporary morbidity from lymphadenectomy for penile squamous cell carcinoma: the MD Anderson Cancer Center Experience. *J. Urol.* 167(4), 1638–1642 (2002).
- 49 Koifman L, Hampl D, Koifman N, Vides AJ, Ornellas AA. Radical open inguinal lymphadenectomy for penile carcinoma: surgical technique, early complications and late outcomes – evaluation of 340 procedures. *J. Urol.* 190(6), 2086–2092 (2013).
- 50 Graafland NM, Lam W, Leijte JA *et al.* Prognostic factors for occult inguinal lymph node involvement in penile carcinoma and assessment of the high-risk EAU subgroup: a two-institution analysis of 342 clinically node-negative patients. *Eur. Urol.* 58(5), 742–747 (2010).
- 51 Solsona E, Iborra I, Rubio J, Casanova JL, Ricos JV, Calabuig C. Prospective validation of the association of local tumor stage and grade as a predictive factor for occult lymph node micrometastasis in patients with penile carcinoma and clinically negative inguinal lymph nodes. *J. Urol.* 165(5), 1506–1509 (2001).

- 52 Slaton JW, Morgenstern N, Levy DA *et al*. Tumor stage, vascular invasion and the percentage of poorly differentiated cancer: independent prognosticators for inguinal lymph node metastasis in penile squamous cancer. *J. Urol.* 165(4), 1138–1142 (2001).
- 53 Solsona E, Iborra I, Ricos JV *et al*. Corpus cavernosum invasion and tumor grade in the prediction of lymph node condition in penile carcinoma. *Eur. Urol.* 22(2), 115–118 (1992).
- 54 Cabanas RM. An approach for the treatment of penile carcinoma. *Cancer* 39(2), 456–466 (1977).
- 55 Pettaway CA, Pisters LL, Dinney CP *et al*. Sentinel lymph node dissection for penile carcinoma: the M. D. Anderson Cancer Center experience. *J. Urol.* 154(6), 1999–2003 (1995).
- 56 Mansel RE, Fallowfield L, Kissin M *et al*. Randomized multicentre trial of sentinel node biopsy versus standard axillary treatment in operable breast cancer: the ALMANAC trial. *J. Natl Cancer Inst.* 98(9), 599–609 (2006).
- 57 Veronesi U, Paganelli G, Viale G *et al*. A randomized comparison of sentinel node biopsy with routine axillary dissection in breast cancer. *N. Engl. J. Med.* 349(6), 546–553 (2003).
- 58 Goyal A, Mansel R. Current status of sentinel lymph node biopsy in solid malignancies. *World J. Surg. Oncol.* 2, 9 (2004).
- 59 Hadway P, Lynch M, Heenan S, Watkin NA. Current status of dynamic lymphoscintigraphy and sentinel lymph node biopsy in urological malignancies. *BJU Int.* 96(9), 1235–1239 (2005).
- 60 Kroon BK, Horenblas S, Meinhardt W *et al*. Dynamic sentinel node biopsy in penile carcinoma. evaluation of 10 years experience. *Eur. Urol.* 47(5), 601–606 (2005).
- 61 Leijte JAP, Kroon BK, Valdes Olmos RA, Nieweg OE, Horenblas S. Reliability and safety of current dynamic sentinel node biopsy for penile carcinoma. *Eur. Urol.* 52(1), 170–177 (2007).
- 62 Leijte JA, Hughes B, Graafland NM *et al*. Two-center evaluation of dynamic sentinel node biopsy for squamous cell carcinoma of the penis. *J. Clin. Oncol.* 27(20), 3325–3329 (2009).
- 63 Lam W, Alnajjar HM, La-Touche S *et al*. Dynamic sentinel lymph node biopsy in patients with invasive squamous cell carcinoma of the penis: a prospective study of the long-term outcome of 500 inguinal basins assessed at a single institution. *Eur. Urol.* 63(4), 657–663 (2013).
- 64 Kroon BK, Horenblas S, Lont AP, Tanis PJ, Gallee MP, Nieweg OE. Patients with penile carcinoma benefit from immediate resection of clinically occult lymph node metastases. *J. Urol.* 173(3), 816–819 (2005).
- 65 Sadeghi R, Gholami H, Zakavi SR, Kakhki VR, Tabasi KT, Horenblas S. Accuracy of sentinel lymph node biopsy for inguinal lymph node staging of penile squamous cell carcinoma: systematic review and meta-analysis of the literature. *J. Urol.* 187(1), 25–31 (2012).
- 66 Djajadiningrat RS, Graafland NM, van Werkhoven E. Contemporary management of regional nodes in penile cancer: improvement of survival? *J. Urol.* 191(1), 68–73 (2013).
- 67 Pizzocaro G, Algaba F, Horenblas S *et al*. EAU guidelines on penile cancer. *Eur. Urol.* 57(6), 1002–1012 (2010).
- 68 Brouwer OR, Buckle T, Vermeeren L *et al*. Comparing the hybrid fluorescent–radioactive tracer indocyanine green–^{99m}Tc-nanocolloid with ^{99m}Tc-nanocolloid for sentinel node identification: a validation study using lymphoscintigraphy and SPECT/CT. *J. Nucl. Med.* 53(7), 1034–1040 (2012).
- 69 Matin SF, Cormier JN, Ward JF *et al*. Phase 1 prospective evaluation of the oncological adequacy of robotic assisted video-endoscopic inguinal lymphadenectomy in patients with penile carcinoma. *BJU Int.* 111(7), 1068–1074 (2013).
- 70 Verhoeven RH, Janssen-Heijnen ML, Saum KU *et al*. The EUNICE Survival Working Group. Population-based survival of penile cancer patients in Europe and the United States of America: no improvement since 1990. *Eur. J. Cancer* 49(6), 1414–1442 (2013).
- 71 Visser O, Adolffson J, Rossi S *et al*. Incidence and survival of rare urogenital cancers in Europe. *Eur. J. Cancer* 48(4), 456–464 (2012).
- 72 Sant M, Allemani C, Santaquilani M, Knijn A, Marchesi F, Capocaccia R. EUROCORE Working Group. EUROCORE-4. Survival of cancer patients diagnosed in 1995–1999. Results and commentary. *Eur. J. Cancer* 45(6), 931–991 (2009).
- 73 Graafland NM, Verhoeven RH, Coebergh JW, Horenblas S. Incidence trends and survival of penile squamous cell carcinoma in The Netherlands. *Int. J. Cancer* 128(2), 426–432 (2011).
- 74 Marty R, Roze S, Bresse X, Largeron N, Smith-Palmer J. Estimating the clinical benefits of vaccinating boys and girls against HPV-related diseases in Europe. *BMC Cancer* 8, 13:10 (2013).
- 75 Shabbir M, Barod R, Hegarty PK, Minhas S. Primary prevention and vaccination for penile cancer. *Ther. Adv. Urol.* 5(3), 161–169 (2013).
- 76 Cubilla AL, Lloveras B, Alejo M *et al*. The basaloid cell is the best tissue marker for human papillomavirus in invasive penile squamous cell carcinoma: a study of 202 cases from Paraguay. *Am. J. Surg. Pathol.* 34(1), 104–114 (2010).
- 77 Eichler H, Kong S, Gerth W, Mavros P, Jönsson B. Use of cost–effectiveness analysis in health-care resource allocation decision-making: how are cost–effectiveness thresholds are expected to emerge? *Value Health* 7(5), 518–528 (2004).
- 78 Dunne EF, Markowitz LE, Chesson H *et al*. Centers for Disease Control and Prevention. Recommendations on the use of quadrivalent human papillomavirus vaccine in males – Advisory Committee on Immunization Practices (ACIP). *Morb. Mortal Wkly Rep.* 60(50), 1705–1708 (2011).
- 79 Protzel C, Hakenberg OW. Chemotherapy in patients with penile carcinoma. *Urol. Int.* 82(1), 1–7 (2009).
- 80 Kattan J, Culine S, Droz JP *et al*. Penile cancer chemotherapy: twelve years' experience at Institut Gustave-Roussy. *Urology* 42(5), 559–562 (1993).
- 81 Hakenberg O, Protzel C. Chemotherapy in penile cancer. *Ther. Adv. Urol.* 4(3) 133–138 (2012).

- 82 Dexeus FH, Logothetis CJ, Sella A *et al.* Combination chemotherapy with methotrexate, bleomycin and cisplatin for advanced squamous cell carcinoma of the male genital tract. *J. Urol.* 146(5), 1284–1287 (1991).
- 83 Pagliaro LC, Williams DL, Daliani D *et al.* Neoadjuvant paclitaxel, ifosfamide, and cisplatin chemotherapy for metastatic penile cancer: a Phase II study. *J. Clin. Oncol.* 28(24), 3851–3857 (2010).
- 84 Bermejo C, Busby JE, Spiess PE, Heller L, Pagliaro LC, Pettaway CA. Neoadjuvant chemotherapy followed by aggressive surgical consolidation for metastatic penile squamous cell carcinoma. *J. Urol.* 177(4), 1335–1338 (2007).
- 85 Leijte JA, Kerst JM, Bais E, Antonini N, Horenblas S. Neoadjuvant chemotherapy in advanced penile carcinoma. *Eur. Urol.* 52(2), 488–494 (2007).
- 86 Wells A. EGF receptor. *Int. J. Biochem. Cell Biol.* 31(6), 637–643 (1999).
- 87 Lavens N, Gupta R, Wood LA. EGFR overexpression in squamous cell carcinoma of the penis. *Curr. Oncol.* 17(1), 4–6 (2010).
- 88 Salomon DS, Brandt R, Ciardiello F, Normanno N. Epidermal growth factor-related peptides and their receptors in human malignancies. *Crit. Rev. Oncol. Haematol.* 19(3), 183–232 (1995).
- 89 Di Lorenzo G, Buonerba C, Gaudioso G *et al.* EGFR mutational status in penile cancer. *Expert Opin. Ther. Target* 17(5), 501–505 (2013).
- 90 Di Lorenzo G, Perdonà S, Buonerba C *et al.* Cytosolic phosphorylated EGFR is predictive of recurrence in early stage penile cancer patients: a retrospective study. *J. Transl. Med.* 11(1), 161 (2013).
- 91 Gou HF, Li X, Qiu M, Cheng K *et al.* Epidermal growth factor receptor (EGFR)-RAS signaling pathway in penile squamous cell carcinoma. *PLoS ONE* 8(4), e62175 (2013).
- 92 Valverde CM, Hernandez-Losa J, Ferrandiz-Pulido C *et al.* BRAF and KRAS mutations in penile cancer and their correlation with clinical features. *J. Clin. Oncol.* 29(Suppl. 7), Abstract 221 (2011).
- 93 Andersson P, Kolaric A, Windahl T *et al.* PIK3CA, HRAS and KRAS gene mutations in human penile cancer. *J. Urol.* 179(5), 2030–2034 (2008).
- 94 Stankiewicz E, Prowse DM, Ng M *et al.* Alternative HER/PTEN/Akt pathway activation in HPV positive and negative penile carcinomas. *PLoS ONE* 6(3), e17517 (2011).
- 95 Stankiewicz E, Prowse DM, Ktori E *et al.* The retinoblastoma protein/p16 INK4A pathway but not p53 is disrupted by human papillomavirus in penile squamous cell carcinoma. *Histopathology* 58(3), 433–439 (2011).
- 96 Lopes A, Bezerra AL, Pinto CA *et al.* p53 as a new prognostic factor for lymph node metastasis in penile carcinoma: analysis of 82 patients treated with amputation and bilateral lymphadenectomy. *J. Urol.* 168(1), 81–86 (2002).
- 97 Poetsch M, Hemmerich M, Kakies C *et al.* Alterations in the tumor suppressor gene p16 (INK4A) are associated with aggressive behavior of penile carcinomas. *Virchows Arch.* 458(2), 221–229 (2011).
- 98 Golijanin D, Tan JY, Kazior A *et al.* Cyclooxygenase-2 and microsomal prostaglandin E synthase-1 are overexpressed in squamous cell carcinoma of the penis. *Clin. Cancer Res.* 10(3), 1024–1031 (2004).
- 99 Carthon BC, Pettaway C, Pagliaro LC. Epidermal growth factor receptor (EGFR) targeted therapy in advanced metastatic squamous cell carcinoma (AMSCC) of the penis: updates and molecular analyses. *J. Clin. Oncol.* 28(Suppl.), Abstract e15022 (2010).
- 100 Sonpavde G, Pagliaro LC, Buonerba C, Dorff TB, Lee RJ, Di Lorenzo G. Penile cancer: current therapy and future directions. *Ann. Oncol.* 24(5), 1179–1189 (2013).
- 101 Zhu Y, Li H, Yao XD *et al.* Feasibility and activity of sorafenib and sunitinib in advanced penile cancer: a preliminary report. *Urol. Int.* 85(3), 334–340 (2010).
- 102 Edge SB, Byrd DR, Compton C *et al.* *AJCC Cancer Staging Manual 7th Edition*. Springer, NY, USA, 447–456 (2009).