

Interferon- α therapy and Type 1 diabetes mellitus in patients with hepatitis C: pathophysiologic insights

Ayşe Aytaman[†],
Gül Bahtiyar &
Samy I McFarlane

[†]Author for correspondence
Division of Gastroenterology
VA New York Harbor
Healthcare Center,
Brooklyn Campus,
800 Poly Place, Brooklyn,
NY 11209, USA
Tel.: +1 718 836 6600
Ext.: 6939
ayse.aytaman@med.va.gov

Chronic hepatitis C virus infection is associated with an increased risk for the development of Type 2 diabetes mellitus. Proposed mechanisms include increased insulin resistance, development of nonalcoholic fatty liver disease and direct infection of the pancreas by hepatitis C virus. However, the development of Type 1 diabetes mellitus is usually associated with interferon- α therapy for hepatitis C virus infection with development of anti-islet cell antibodies. The pathogenetic mechanisms underlying this autoimmune destruction of the pancreas are not completely understood. In this review the authors discuss hepatitis C virus and Type 1 diabetes, highlighting the role of interferon- α therapy in the development of Type 1 diabetes in hepatitis C virus-infected patients. The mechanisms of action of interferon- α related to the development of Type 1 diabetes in this patient population will also be discussed.

Chronic hepatitis C virus (HCV) infection and Type 2 diabetes mellitus (DM) are two major epidemics affecting millions of people worldwide. Data from the authors' group (Aytaman and colleagues) indicate that up to a quarter of patients with chronic HCV also have Type 2 DM, with an adjusted odds ratio (OR) of 3.66 [1]. This is consistent with data from the National Health and Nutrition Examination Survey III (NHANES), which revealed that HCV-positive people who are aged 40 years or older had an adjusted OR of 3.77 for the development of Type 2 DM [2]. Although Thuluvath and colleagues demonstrated in a small cohort study a higher prevalence of HCV infection among blacks after adjusting the risk factors for age, sex and severity of the liver disease, the authors' analysis of the large cohort of 3600 patients does not support this result [3]. Our data revealed that the prevalence of Type 2 DM does not appear to be influenced by the different ethnic backgrounds after correcting for other risk factors for the disease [4]. However, this prevalence is much higher than that observed in the general population and is also higher than that observed with other chronic liver diseases, such as hepatitis B virus infection, alcoholic liver disease and primary biliary cirrhosis [5–10], after correcting for severity of the liver disease. A recently published study reported that the association between HCV and Type 2 DM is not explained by coexistent cirrhosis [11]. Cirrhosis was not more frequent in biopsies from hepatitis C diabetic patients than nondiabetic or hepatitis B

patients [12]. The pathophysiologic mechanisms of the strong association between HCV and Type 2 DM have not been clearly established [13]. Suggested mechanisms include impaired insulin secretion, destruction of the β -cells either directly or by an immune response, peripheral insensitivity to insulin and dysregulation of hepatic glucose production due to steatosis and increased iron stores [14].

Type 1 DM, on the other hand, appears to be strongly associated with interferon (IFN)-based therapy for chronic HCV infection [15,16]. Accumulating evidence indicates that IFN therapy can induce or exacerbate autoimmune disorders [17–20] such as thyroiditis [18], interstitial pneumonitis [21] and optic neuritis [22]. These disorders have all been attributed to the development or acceleration of an autoimmune process by IFN- α therapy. Many case reports have been published showing the increased incidence of Type 1 DM with the use of IFN- α in patients with HCV [23–25], which is considered a potential complication, but not a contraindication to treatment. Several pathogenetic factors may be involved in this process, one of which could be an imbalance towards a T-helper (Th) type-1-mediated response [25]. Analysis of blood sugar, islet cell antibody, glutamic acid decarboxylase (GAD) autoantibodies levels, before and during IFN treatment, have been recommended [26]. Among all the autoimmune side effects of IFN therapy, Type 1 DM represents a unique challenge for the clinicians in term of diagnosis and management.

Keywords: hepatitis C virus, interferon- α , Type 1 diabetes



Epidemiology of hepatitis C infection & associated disorders

Chronic HCV infection is a worldwide disorder that is approaching epidemic proportions. [27]. Although the numbers of acute infections are declining, given the chronicity of the disease and the recognition and diagnosis of patients presenting with advanced liver disease infected 2 to 3 decades ago, the prevalence of HCV infection is on the increase [28,29]. However, despite advances in diagnostic and therapeutic modalities, HCV infection accounts for up to 8000 to 13,000 deaths each year [27]. HCV infection also leads to cirrhosis in 20 to 30% of affected individuals and it is the most common cause of liver transplantation in the USA [30–32]. Despite a similar incidence of acute infection among patients with different ethnic backgrounds, chronicity appears to occur with a higher frequency among blacks and male patients than in females [28]. Hepatocellular carcinoma is a serious complication that occurs in almost 7% of patients with chronic HCV infection. Unlike hepatitis B, hepatocellular carcinoma only occurs in patients with cirrhosis associated with HCV infection [33,34].

The HCV is a single-stranded RNA virus and, like many other RNA viruses, its polymerase enzyme lacks a proofreading ability and is unable to correct copying errors made during viral replication, resulting in increased viral heterogeneity. This heterogeneity is important in the diagnosis and response to therapy. However, it also allows the virus to escape eradication by the host's immune system and affects the completeness of the response to antiviral therapy. Furthermore, the heterogeneity of the virus hampers the development of an effective vaccine [35–39].

Several extrahepatic diseases have been associated with chronic HCV infection. Hematologic diseases including lymphoma, cryoglobulinemia, monoclonal gammopathy, renal disease with either membranoproliferative glomerulonephritis or membranous nephropathy, ocular complications and dermatologic diseases have also been reported [40–48].

HCV has also been associated with autoimmunity. Autoantibodies are common in patients with chronic HCV infection. Antinuclear antibodies, antibodies directed against the Fc portion of immunoglobulin (Ig)G (rheumatoid factor), anticardiolipin antibodies, smooth muscle antibodies and antithyroid antibodies are detected in 40 to 65% of patients [18–20]. They are typically present in low titers and do not appear to influence the presentation

or course of the infection. In addition, they are not usually associated with extrahepatic disease [49–51]. Most patients with HCV and antiliver/kidney microsomal Type 1 (LKM-1) antibodies, as well as other types of non-organ-specific autoantibodies, appear to benefit from IFN therapy to the same extent as patients with chronic HCV without such antibodies. However, autoantibody-positive patients require careful monitoring during IFN treatment, since flares of aminotransferases without subsequent clearance of HCV RNA have been observed [49–51].

Antithyroid antibodies are present in 5 to 12% of patients with HCV infection, and thyroid disease, primarily hypothyroidism, occurs in 2 to 5% of patients [51]. Furthermore, sialoadenitis [52], autoimmune thrombocytopenic purpura [53], myasthenia gravis [54] and renal disease with membranoproliferative glomerulonephritis, usually associated with essential mixed cryoglobulinemia, have also been associated with HCV infection-related autoimmunity.

Therapeutic options for patients with hepatitis C virus infection

Given the significant morbidity and mortality associated with HCV, therapy is recommended for all patients since currently available modalities effectively ameliorate the virus in up to 50% of cases, thereby significantly decreasing the risk of cirrhosis and related complications [55,56]. Effective therapy has also been associated with resolution of systemic and local symptoms, improvement in extrahepatic manifestations and liver histology, and a moderate decrease in the rate of hepatocellular carcinoma [57–59]. However, therapeutic decisions should be individualized, with evaluation of the risks versus benefits of therapy, considering the patient's comorbidities and prognostic indicators of response to therapy.

Current therapy of chronic HCV infection involves a combination of IFN- α , preferably a longer-acting preparation (pegylated) in combination with ribavirin. The IFNs are a group of related proteins with antiviral activity, growth regulatory properties, inhibition of angiogenesis, regulation of cell differentiation, enhancement of major histocompatibility complex (MHC) antigen expression, and a wide variety of immunomodulatory activities [60]. They were originally classified according to their source and subsequently renamed as α - (leukocyte), β - (fibroblast) and γ - (immune) IFN. A total of 18 genes are known for human

IFN- α , and only one for β and one for γ . IFN- α has been extensively studied for the treatment of patients with chronic HCV infection; however, its exact mechanism of action remains largely unknown [60]. In addition to being antiviral, IFN also modulates immunostimulatory cytokines, which affect the cytokine cascade: the attachment of polyethylene glycol to IFN- α reduces its rate of absorption following subcutaneous injection, leading to reduced renal clearance and a decrease in the immunogenicity of the protein with prolonged half-life and ease of once-a-week administration [60].

Autoimmunity during IFN- α therapy: pathogenetic insights

IFNs have antiviral, cytostatic and immunomodulatory effects which are important during viral infections. However, prolonged exposure of the immune system to IFN can break tolerance and initiate an autoimmune reaction – eventually leading to autoimmune disease [61,62]. IFN increases human leukocyte antigen (HLA) Class I expression, stimulates Th1 cells and lowers the threshold of activation of β -cell responses. It causes proliferation of memory CD8⁺ T-cells, differentiation of the activity of Type 1 dendritic cells (DCs), and inhibition of Fas-ligand-mediated apoptosis [63–65], all of which may aggravate preexisting autoimmunity, unmask silent autoimmune processes, or even induce *de novo* autoimmune diseases, by acting as a signal linking innate and adaptive immunity. Enhanced humoral immunity with hyper- γ -globulinemia, lymphadenopathy and increased serum concentrations of interleukin (IL)-6 have been reported in a patient treated with IFN- α [66]. Several different signals via cell membrane molecules are required to initiate IFN- α gene expression. Its production is increased by cytokines such as IFN- γ , IL-3 and granulocyte-macrophage colony-stimulating factor [67,68].

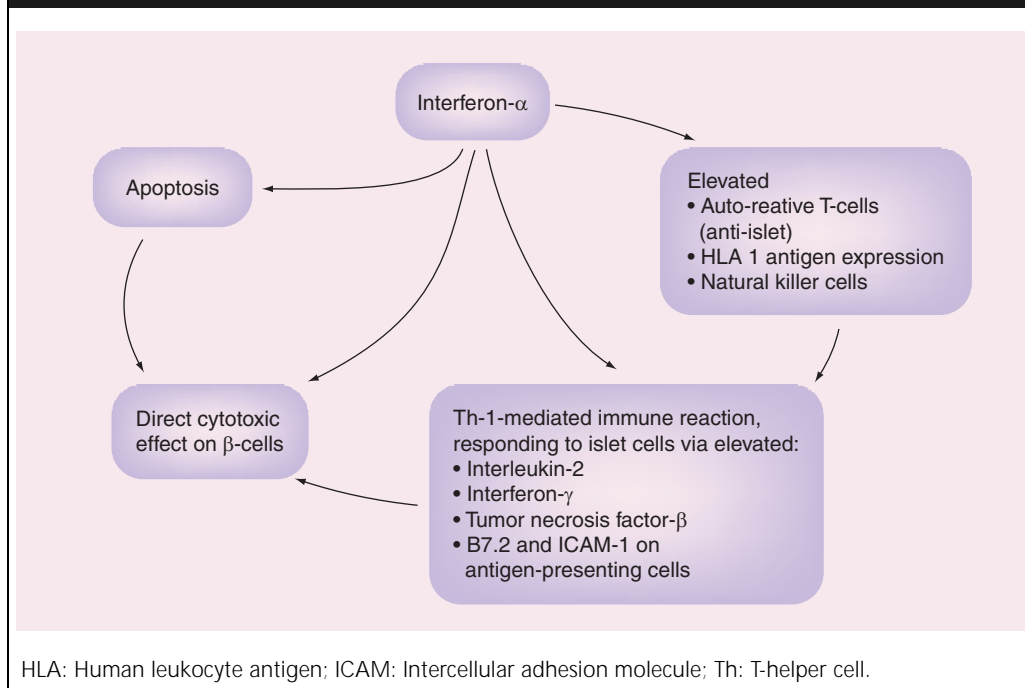
Pathophysiology of Type 1 diabetes mellitus

Type 1 DM is an autoimmune disease, characterized by a relatively rapid onset of symptoms associated with immune-mediated islet cell destruction [70]. It affects between 1 in 250 and 1 in 500 Americans [71]. It has long been known as a hereditary disease on the basis of the relatively high rate of familial transmission: the risk of becoming diabetic is approximately 7% for a sibling and 6% for a child of a diabetic [72]. The illness develops as a result of synergistic effects of

genetic, environmental and immunologic factors that ultimately destroy the pancreatic β -cells [73]. People with genetic susceptibility have normal β -cell mass at birth, with a constant β -cell loss secondary to autoimmune destruction, which occurs over a period of months to years, eventually causing hyperglycemia and diabetic ketoacidosis [74]. A genetic predisposition is necessary, but not sufficient, for the development of Type 1 DM. The concordance of Type 1 DM is approximately 40 to 50% for monozygotic twins, suggesting that environmental factors, such as virus, diet and β -cell toxins, may be involved in the initiation of the disease process [75]. The onset of Type 1 DM is typically preceded and accompanied by circulating autoantibodies, which include islet cell autoantibodies, insulin autoantibodies, GAD autoantibodies and tyrosine-like phosphatase autoantibodies (IA2A) to the endocrine pancreas. One or more of these autoantibodies is present in over 90% of patients with newly diagnosed Type 1 DM [70].

The onset of the disease is characterized by islet cell infiltration of T-lymphocytes and monocytes. However, features of DM do not become evident until more than 80% of β -cells are destroyed [76]. This disease is strongly associated with HLA DR4 and DR3 regions on chromosome 6, where Class II MHC is encoded [72].

The initial step in the pathogenesis of Type 1 DM is the presentation of β -cell-specific autoantigens by macrophages and/or DCs to CD4⁺ Th cells, in association with MHC Class II molecules. The activated macrophages secrete IL-12, which stimulates Th1-type CD4⁺ T-cells. The CD4⁺ T-cells secrete IFN- γ and IL-2. IFN- γ activates other resting macrophages, which, in turn, release cytokines such as IL-1 β , tumor necrosis factor (TNF)- α and free radicals, which are toxic to pancreatic β -cells. During this process, IL-2 and other cytokines induce the migration of CD8⁺ peripheral T-cells to the inflamed islets, perhaps by inducing the expression of a specific homing receptor. The precytotoxic CD8⁺ T-cells that bear β -cell-specific autoantigen receptors differentiate into cytotoxic effector T-cells upon recognition of the β -cell-specific peptide bound to MHC Class I molecules in the presence of β -cell-specific CD4⁺ T-helper cells. The cytotoxic CD8⁺ T-cells then affect β -cell damage by releasing perforin and granzyme, and by Fas-mediated apoptosis. In this way, macrophages, CD4⁺ T-cells, and CD8⁺ T-cells synergistically destroy β -cells, resulting in the onset of Type 1 DM [77].

Figure 1. Possible mechanism of β -cell destruction by interferon- α .

Type 1 diabetes mellitus during IFN- α therapy

In 1992, Fabris and colleagues documented the first case of Type 1 DM with IFN- α . This particular case with HCV infection had increased GAD and insulin autoantibodies with IFN- α treatment [15]. Furthermore, two large retrospective studies involving 12,000 patients, investigating the side effects of IFN- α in patients with chronic HCV infection demonstrated that the incidence of Type 1 DM was higher than the annual incidence in the general population [78,79]. The review of all the case reports published until 2003 by Fabris and colleagues demonstrated that only 3% of patients with chronic HCV infection have pancreatic autoantibodies that are not significantly different from the general population, with an increment to 7% following IFN- α treatment [80]. These data suggest that IFN- α therapy is associated with increased pancreatic autoimmunity, leading to subsequent development of Type 1 DM. Different case reports reveal both transient and permanent insulin dependency, indicating that, in some cases, the autoimmune effect is, at least partially, reversible with the interruption of IFN- α therapy [81–83]. However, the relationship between these two conditions remains controversial. Piquer and colleagues assessed the prevalence of islet cell autoantibodies 6 months before

and 12 months after 24 weeks of IFN- α treatment in 46 patients with HCV, and compared the antibody levels with 303 nonselected patients with HCV and 273 sex- and age-matched control patients. GAD was detected in four out of 277 (1.4%) HCV-infected nondiabetic patients, 0 of 26 HCV-infected diabetic patients and 1 of 273 (0.3%) control subjects. Anti-IA2 and islet cell autoantibodies were negative in all subjects. After IFN- α treatment, both GAD and anti-IA2 remained negative in all HCV-infected patients, suggesting that β -cell autoimmunity is not associated with anti-HCV therapy [84]. Meanwhile, Huang and colleagues were able to demonstrate that, only IFN- α but not the other cytokines such as IFN- γ and - β , TNF- α and IL-1 β , -2, -4 and IL-6 were significantly overexpressed in diabetic patients, by using a reverse transcriptase polymerase chain reaction in the pancreas and islets from patients with and without Type 1 DM [85]. Cytokines such as IFN- α and - γ , TNF- α and - β and IL-1 may be directly cytotoxic to β -cells by inducing nitric oxide and free radicals in the β -cells [86]. The cytokines may sensitize β -cells to T-cell-mediated cytotoxicity by upregulating MHC I expression with costimulatory ligands such as B7.2 and inducing Fas expression on the β -cells [87]. IFN- α also increases HLA Class 1 antigen expression, natural killer cell and T-cell

activity. It is an important cofactor in the development of Th-1-mediated immune reactions, which contribute to the development of autoimmune diseases, one of which is Type 1 DM, by the activation of CD4⁺ lymphocytes secreting IL-2, IFN- γ and TNF- β . These cytokines aid the generation of CD8⁺ cytotoxic cells [88]. El-Sheikh and colleagues demonstrated that islet infiltration by both CD4⁺ and CD8⁺ T-cells are required for IFN- γ and IL-10 production in islets and β -cell destruction. Depletion of either CD4⁺ or CD8⁺ T-cells may prevent β -cell destruction by decreasing IFN- γ and IL-10 production in islets and increasing systemically produced IL-4 and TNF- α [89]. A recent review by Devendra and colleagues discussed the possible mechanism of viral double-stranded RNA, which activates the production of IFN- α in various cells, causing direct cytotoxicity to the β -cells of the pancreas. IFN- α induces apoptosis, and apoptotic materials induce more IFN- α and activate the immune system [75]. Cytokines released from islet cells infiltrating mononuclear cells affect β -cells by decreasing islet insulin content, suppressing glucose-stimulated insulin secretion, generating enhanced amounts of nitric oxide and breaking the DNA strand leading to β -cell damage (Figure 1) [90].

New-onset hyperglycemia during IFN therapy should be evaluated with autoantibodies, GAD and islet cell autoantibodies, to differentiate

between Type 1 and 2 DM. Both types of DM can develop during IFN therapy, and the correct diagnosis is important for initiation of proper therapeutic interventions.

Expert opinion

IFN- α is an effective therapeutic modality in patients with chronic HCV infection, leading to remission of the disease in about 50% with significant improvement of both hepatic and extrahepatic manifestations. However, this therapy is associated with an increased risk of autoimmune diseases, including Type 1 DM. The presence of autoantibodies prior to therapy does not necessarily predict the development of Type 1 DM with IFN- α treatment. Clinicians should be aware of this serious side effect and monitor patients, especially those with a family history of DM, very carefully during IFN therapy as timely intervention can guard against serious complications of Type 1 DM such as ketoacidosis and avoid therapy discontinuations. Available evidence does not support baseline autoimmune markers and also cessation of anti-HCV therapy with the onset of Type 1 DM. Patients developing hyperglycemia during IFN therapy need to be evaluated with GAD and islet cell autoantibodies. More research is needed in this area to further explore the pathophysiology of and the predictive markers for Type 1 DM during IFN-based therapy.

Highlights

- There is a unique association between chronic hepatitis C virus (HCV) and Type 2 diabetes mellitus (DM). However, the pathophysiologic mechanisms have not been clearly established.
- Type 1 DM, on the other hand, appears to be strongly associated with interferon (IFN)-based therapy for chronic HCV infection with development of anti-islet cell antibodies.
- IFN- α can also induce or exacerbate other autoimmune disorders such as thyroiditis, hemolytic anemia and immune-mediated thrombocytopenia.
- Development of Type 1 DM is not a contraindication to treatment and does not necessitate the discontinuation of therapy.

Outlook

Chronic hepatitis C infection is likely to continue as a worldwide epidemic for the foreseeable future. IFN-based therapies will probably remain the mainstay of therapy for the next 5 to 10 years. However, physicians should be aware of the complications of therapy including Type 1 DM for timely recognition and intervention, as completion of a full course of therapy might make a significant difference in the natural course of the disease.

Bibliography

1. Aytaman A, Bahtiyar G, Arora S *et al*. Cholestatic liver enzymes as predictors of Type 2 diabetes in patients with hepatitis C infection. A cross sectional study. *69th American Association for the Study of Liver Diseases* MA, USA (2004) (Abstract).
2. Mehta SH, Brancati FL, Sulkowski MS *et al*. Prevalence of Type 2 diabetes mellitus among persons with hepatitis C virus infection in the United States. *Ann. Intern. Med.* 133, 592–599 (2000).
3. Thuluvath J, John PR. Association between hepatitis C, diabetes mellitus and race: a case control study. *Am. J. Gastroenterol.* 98(2), 438–441 (2003).
4. Bahtiyar G, Aytaman A, Arora S *et al*. Chronic hepatitis C infection and the risk of Type 2 diabetes among men of different ethnic backgrounds. A cross-sectional study. *70th American College of Gastroenterology* FL, USA (2004) (Abstract).
5. Allison ME, Wreghitt T, Palmer CR, Alexander GJ. Evidence for a link between hepatitis C virus infection and diabetes mellitus in a cirrhotic population. *J. Hepatology* 21, 1135–1139 (1994).

6. El-Zayadi AR, Selim OE, Hamdy H, Dabbous H *et al.* Association of chronic hepatitis C infection and diabetes mellitus. *Trop. Gastroenterol.* 19, 141–144 (1998).
7. Grimbert S, Valensi P, Levy-Marchal C, Perret G *et al.* High prevalence of diabetes mellitus in patients with chronic hepatitis C: a case-control study. *Gastroenterol. Clin. Biol.* 20, 544–548 (1996).
8. Ozyilkan E, Erbas T, Simsek H *et al.* Increased prevalence of hepatitis C virus antibodies in patients with diabetes mellitus. *J. Intern. Med.* 235, 283–284 (1994).
9. Simo R, Hernandez C, Genesca J, Jardi R, Mesa J. High prevalence of hepatitis C virus infection in diabetic patients. *Diabetes Care* 19, 998–1000 (1996).
10. Gray H, Wreghitt T, Stratton IM, Alexander GJ *et al.* High prevalence of hepatitis C infection in Afro-Caribbean patients with Type 2 diabetes and abnormal liver function tests. *Diabet. Med.* 12, 244–249 (1995).
11. Knobler H, Schihmanter R, Zifroni A *et al.* Increased risk of Type 2 diabetes in noncirrhotic patient with chronic hepatitis C virus infection. *Mayo Clin. Proc.* 75, 355–359 (2000).
12. Frase GM, Harman I, Porath A *et al.* Diabetes mellitus associated with chronic hepatitis C but not chronic hepatitis B infection. *Isr. J. Med. Sci.* 32, 526–30 (1996).
13. Bahtiyar G, Shin JJ, Aytaman A *et al.* Association of diabetes mellitus and chronic hepatitis C infection: epidemiologic evidence and pathophysiologic insights. *Curr. Diabet. Rep.* 4(3), 194–198 (2004).
14. DeFronzo RA. Pathogenesis of Type 2 diabetes mellitus: a balanced overview. *Diabetologia* 35, 389–397 (1992).
15. Fabris P, Betterle C, Floreani A *et al.* Development of Type 1 diabetes mellitus during interferon- α therapy for chronic HCV hepatitis. *Lancet* 340(1882), 548 (1992).
16. Guerci AP, Guerci B, Levy-Marchal C *et al.* Onset of insulin-dependent diabetes mellitus after interferon- α therapy for hairy cell leukaemia. *Lancet* 343(8906), 1167–1168 (1994).
17. Conlon KC, Urba WJ, Smith JW *et al.* Exacerbation of symptoms of autoimmune disease in patients receiving interferon- α therapy. *Cancer* 65, 2237 (1990).
18. Reddy KR, Krawitt EL, Jacobsen I *et al.* Thyroid dysfunction in chronic hepatitis C and following interferon- α 2a treatment. *Hepatology* 26, 368A (1997).
19. Silva MO, Reddy KR, Jeffers LJ *et al.* Interferon-induced chronic active hepatitis? *Gastroenterology* 101, 840–842 (1991).
20. Garcia-Buey L, Garcia-Monzon C, Rodriguez S *et al.* Latent autoimmune hepatitis-triggered during interferon therapy in patients with chronic hepatitis. *Gastroenterology* 108, 1770–1777 (1995).
21. Abi-Nassif S, Mark EJ, Fogel RB *et al.* Pegylated interferon and ribavirin induced interstitial pneumonitis with ARDS. *Chest* 124, 406–410 (2003).
22. Manesis EK, Petrou C, Brouzas D, Hadziyannis S. Optic tract neuropathy complicating low-dose interferon treatment. *J. Hepatology* 21(3), 474–477 (1994).
23. Recasens M, Aguilera E *et al.* Abrupt onset of diabetes during interferon- α therapy with chronic hepatitis C. *Diabet. Med.* 18(9), 764–767 (2001).
24. Eibl N, Gschwantlet M *et al.* Development of insulin dependent diabetes mellitus in a patient with chronic hepatitis C during therapy with interferon- α . 13(3), 295–298 (2001).
25. Bosi E, Minelli R *et al.* Fulminant autoimmune Type 1 diabetes during interferon- α therapy: a case of Th-1 mediated disease? *Diabet. Med.* 18(4), 329–332 (2001).
26. Gross U, Seifert E. Transient insulin dependent diabetes mellitus with interferon- α therapy in chronic active hepatitis. *Z. Gastroenterol.* 31(10), 609–611 (1993).
27. Williams I. Epidemiology of hepatitis C in the United States. *Am. J. Med.* 107(6B), S2–S9 (1999).
28. McQuillan G, Alter M, Moyer L *et al.* A population-based serologic study of hepatitis C virus infection in the United States. *Proceedings of the IX International Symposium on Viral Hepatitis and Liver Disease*, Rome 8A. NHANES survey (1996).
29. Alter MJ. Epidemiology of hepatitis C. *Hepatology* 26(3 Suppl. 1), S62–S65 (1997).
30. Farci P, Alter HJ, Wong D *et al.* A long-term study of hepatitis C virus replication in non-A, non-B hepatitis. *N. Engl. J. Med.* 325, 98–104 (1991).
31. Bonis PA, Tong MJ, Blatt LM *et al.* A predictive model for the development of hepatocellular carcinoma, liver failure or liver transplantation for patients presenting to clinic with chronic hepatitis C. *Am. J. Gastroenterol.* 94(6), 1605–1612 (1999).
32. Yu MW, Chen CJ. Hepatitis B and C viruses in the development of hepatocellular carcinoma. *Crit. Rev. Oncol. Hematol.* 17(2), 71–91 (1994).
33. Bruix J, Barrera JM, Calvet X, Costa J *et al.* Prevalence of antibodies to hepatitis C virus in Spanish patients with hepatocellular carcinoma and hepatic cirrhosis. *Lancet* 2, 1004–1006 (1989).
34. Colombo M, Choo QL, Del Ninno E *et al.* Prevalence of antibodies to hepatitis C virus in Italian patients with hepatocellular carcinoma. *Lancet* 2, 1006–1008 (1989).
35. Farci P, Shimoda A, Wong D *et al.* Prevention of hepatitis C virus infection in chimpanzees by hyperimmune serum against the hypervariable region 1 of the envelope 2 protein. *Proc. Natl Acad. Sci. USA* 93, 15394–15399 (1996).
36. González-Peralta RP, Qian K, She JY *et al.* Clinical implications of viral quasispecies in chronic hepatitis C. *J. Med. Virol.* 49, 242–247 (1996).
37. Chemello L, Alberti A, Rose K, Simmonds P. Hepatitis C serotype and response to interferon therapy. *N. Engl. J. Med.* 330(2), 143 (1994).
38. Davis GL, Lau JY. Factors predictive of a beneficial response to therapy of hepatitis C. *Hepatology* 26(Suppl. 1), S122 (1997).
39. Martinot-Peignoux M, Marcellin P, Pouteau M *et al.* Pretreatment serum hepatitis C virus RNA levels and hepatitis C virus genotype are the main and independent prognostic factors of sustained response to interferon- α therapy in chronic hepatitis C. *Hepatology* 22, 1050–1056 (1995).
40. Gisbert JP, Garca-Buey L, Pajares JM, Moreno-Otero R. Prevalence of hepatitis C virus infection in porphyria cutanea tarda: systematic review and meta-analysis *Hepatology* 39(4), 620–627 (2003).
41. Lunel F, Musset L, Cacoub P *et al.* Cryoglobulinemia in chronic liver diseases: Role of hepatitis C virus and liver damage. *Gastroenterology* 106, 1291–300 (1994).
42. Andreone P, Zignego AL, Cursaro C *et al.* Prevalence of monoclonal gammopathies in patients with hepatitis C virus infection. *Ann. Intern. Med.* 129, 294–298 (1998).
43. Johnson RJ, Gretch DR, Yamabe H *et al.* Membranoproliferative glomerulonephritis associated with hepatitis C virus infection. *N. Engl. J. Med.* 328, 465–470 (1993).
44. Daghestani L, Pomeroy C. Renal manifestations of hepatitis C infection. *Am. J. Med.* 106, 347–354 (1999).
45. Wilson SE, Lee WM, Murakami C *et al.* Mooren's corneal ulcers and hepatitis C virus infection. *N. Engl. J. Med.* 329, 62–63 (1993).
46. Ali Y, Ghafouri M, Weitzman M *et al.* Refractory scleritis in a patient with

- cryoglobulinemia and hepatitis C. *J. Clin. Rheumatol.* 5, 371–372 (1999).
47. Daoud MS, Gibson LE, Daoud S, El-Azhary RA. Chronic hepatitis C and skin diseases: A review. *Mayo Clin. Proc.* 70, 559–564 (1995).
 48. Pilli M, Penna A, Zerbini A, Vescovi P. Oral lichen planus pathogenesis: a role for the HCV-specific cellular immune response. *Hepatology* 36, 1446–1452 (2002).
 49. Clifford BD, Donahue D, Smith L *et al.* High prevalence of serological markers of autoimmunity in patients with chronic hepatitis C. *Hepatology* 21, 613–619 (1995).
 50. Cacoub P, Musset L, Amoura Z *et al.* Anticardiolipin, anti- β 2-Glycoprotein I, and antinucleosome antibodies in hepatitis C virus infection and mixed cryoglobulinemia. *J. Rheumatol.* 24, 2139–2144 (1997).
 51. Tran A, Quaranta JF, Benzaken S *et al.* High prevalence of thyroid autoantibodies in a prospective series of patients with chronic hepatitis C before interferon therapy. *Hepatology* 18, 253–257 (1993).
 52. Haddad J, Deny P, Munz-Gothel C *et al.* Lymphocytic sialadenitis of Sjögren's syndrome associated with chronic hepatitis C virus liver disease. *Lancet* 339, 321–323 (1992).
 53. Pawlowsky JM, Bouvier M, Fromont P *et al.* Hepatitis C virus infection and autoimmune thrombocytopenia purpura. *J. Hepatology* 23, 635–639 (1995).
 54. Eddy S, Wim R, Peter VE *et al.* Myasthenia gravis: Another autoimmune disease associated with hepatitis C virus infection. *Dig. Dis. Sci.* 44, 186–189 (1999).
 55. Hadziyannis SJ, Sette H Jr, Morgan TR *et al.* Peginterferon- α 2a and ribavirin combination therapy in chronic hepatitis C: a randomized study of treatment duration and ribavirin dose. *Ann. Intern. Med.* 140(5), 346–355 (2004).
 56. Manns MP, McHutchison JG, Gordon SC *et al.* Peginterferon- α 2b plus ribavirin compared with interferon- α 2b plus ribavirin for initial treatment of chronic hepatitis C: a randomised trial. *Lancet* 358(9286), 958–965 (2001).
 57. Nishiguchi S, Kuroki T, Nakatani S *et al.* Randomised trial of effects of interferon- α on incidence of hepatocellular carcinoma in chronic active hepatitis C with cirrhosis. *Lancet* 346(8982), 1051–1055 (1995).
 58. Tiribelli C, Melato M, Croce LS *et al.* Prevalence of hepatocellular carcinoma and relation to cirrhosis: comparison of two different cities of the world – Trieste, Italy, and Chiba, Japan. *Hepatology* 10(6), 998–1002 (1989).
 59. Papatheodoridis GV, Papadimitropoulos VC, Hadziyannis SJ. Effect of interferon therapy on the development of hepatocellular carcinoma in patients with hepatitis C virus-related cirrhosis: a meta-analysis. *Ali. Pharmacol. Ther.* 15(5), 689–698 (2001).
 60. Reddy KR, Modi MW, Pedder S. Use of peginterferon alfa-2a (40KD) for the treatment of hepatitis C. *Adv. Drug Deliv. Rev.* 54, 571–586 (2002).
 61. Akbar AN, Lord JM *et al.* IFN- α and IFN- β : a link between immune memory and chronic inflammation. *Immunol. Today* 21, 337–342 (2000).
 62. Biron CA. Interferons α and β as immune regulators – a new look. *Immunity* 14, 661–664 (2001).
 63. Ronnblom L, Alm GV. Systemic lupus erythematosus and type I interferon system. *Arthritis Res. Ther.* 5(2), 68–75 (2003).
 64. Kirou KA, Vakkalanka RK *et al.* Induction of FAS ligand-mediated apoptosis by interferon- α . *Clin. Immunol.* 95, 218–226 (2000).
 65. Ruuth K, Carlsson L *et al.* Interferon- α promotes survival of human primary B-lymphocytes via phosphatidylinositol 3-kinase. *Biochem. Biophys. Res. Commun.* 284, 583–586 (2001).
 66. Lapinski TW. The levels of IL-1 ν - β , IL-2, IL-4, IL-6 and IFN- γ among patients with chronic hepatitis type C treated with IFN- α . *Rocz. Akad. Med. Białymst.* 45, 211–227 (2000).
 67. Cederbald B, Alm GV. Interferons and the colony stimulating factors IL-3 and GM-CSF enhance the IFN- α response in human blood leukocytes induced by herpes simplex virus. *Scand. J. Immunol.* 34, 549–555 (1991).
 68. Båve U, Vallin H *et al.* Activation of natural interferon- α producing cells by apoptotic U 937 cells combined with lupus IgG and its regulation by cytokines. *J. Autoimmun.* 17, 71–80 (2001).
 69. Bosi E, Todd I, Pujol-Borrell R, Bottazzo GF. Mechanisms of autoimmunity: relevance to the pathogenesis of Type I (insulin-dependent) diabetes mellitus. *Diabet. Metab. Rev.* 3, 893–923 (1987).
 70. Winter WE. Type I insulin-dependent diabetes mellitus: a model for autoimmune polygenic disorders. *Adv. Dent. Res.* 10(1), 81–87 (1996).
 71. Bach JF. Insulin-dependent diabetes mellitus as an autoimmune disease. *Endocr. Rev.* 15(4), 516–542 (1994).
 72. Scherbaum WA, Seissler J. Cellular and humoral autoimmunity in insulin-dependent diabetes mellitus. *Exp. Clin. Endocrinol. Diabet.* 103(Suppl. 2), 88–94 (1995).
 73. Foulis AK. The pathology of the endocrine pancreas in Type 1 (insulin-dependent) diabetes mellitus. *Acta Pathol. Microbiol. Immunol. Scand.* 104(3), 161–167 (1996).
 74. Devendra D, Eisenbarth GS. Interferon- α – a potential link in the pathogenesis of viral-induced Type 1 diabetes and autoimmunity. *Clin. Immunol.* 111(3), 225–233 (2004).
 75. Atkinson MA, Eisenbarth GS. Type 1 diabetes: new perspectives on disease pathogenesis and treatment. *Lancet* 358, 221–229 (2001).
 76. Yoon JW, Jun HS. Cellular and molecular pathogenic mechanisms of insulin-dependent diabetes mellitus. *Ann. NY Acad. Sci.* 928, 200–211 (2001).
 77. Fattovich G, Giustina G, Favarato S, Ruol A. A survey of adverse events in 11,241 patients with chronic viral hepatitis treated with alpha interferon. *J. Hepatology* 24(1), 38–47 (1996).
 78. Okanoue T, Sakamoto S, Itoh Y *et al.* Side effects of high-dose interferon therapy for chronic hepatitis C. *J. Hepatology* 25(3), 283–291 (1996).
 79. Fabris P, Floreani A, Tositti G *et al.* Type 1 diabetes mellitus in patients with chronic hepatitis C before and after interferon therapy. *Ali. Pharmacol. Ther.* 18(6), 549–558 (2003).
 80. Waguri M, Hanafusa T, Itoh N *et al.* Occurrence of IDDM during interferon therapy for chronic viral hepatitis. *Diabet. Res. Clin. Pract.* 23(1), 33–36 (1994).
 81. Bosi E, Minelli R, Bazzigaluppi E, Salvi M. Fulminant autoimmune Type 1 diabetes during interferon- α therapy: a case of Th1-mediated disease? *Diabet. Med.* 18(4), 329–332 (2001).
 82. Eibl N, Gschwantler M, Ferenci P *et al.* Development of insulin-dependent diabetes mellitus in a patient with chronic hepatitis C during therapy with interferon- α . *Eur. J. Gastroenterol. Hepatol.* 13(3), 295–298 (2001).
 83. Piquer S, Hernandez C, Enriquez J *et al.* Islet cell and thyroid antibody prevalence in patients with hepatitis C virus infection: effect of treatment with interferon. *J. Lab. Clin. Med.* 137(1), 38–42 (2001).
 84. Huang X, Yuang J, Goddard A *et al.* Interferon expression in the pancreases of patients with Type I diabetes. *Diabetes* 44(6), 658–664 (1995).
 85. Rabinovitch A. An update on cytokines in the pathogenesis of insulin dependent diabetes mellitus. *Diabet. Metab. Rev.* 14(2), 129–151 (1998).

86. Alba A, Puertas MC, Carillo J *et al.* IFN- β accelerates autoimmune Type 1 diabetes in nonobese diabetic mice and breaks the tolerance to β -cells in nondiabetes-prone mice. *J. Immunol.* 173(11), 6667–6675 (2004).
87. Chakrabarti D, Hultgren B, Stewart TA. IFN- α induces autoimmune T cells through the induction of intracellular adhesion molecule-1 and B7.2. *J. Immunol.* 157(2), 522–528 (1996).
88. El-Sheikh A, Suarez-Pinzon WL *et al.* Both CD4(+) and CD8(+) T cells are required for IFN- γ gene expression in pancreatic islets and autoimmune diabetes development in biobreeding rats. *J. Autoimmun.* 12(2), 109–119 (1999).
89. Wachlin G, Augstein P, Schroder D *et al.* IL-1 β , IFN- γ and TNF- α increase vulnerability of pancreatic- β cells to autoimmune destruction. *J. Autoimmun.* 20(4), 303–312 (2003).

Affiliations

Ayşe Aytaman, MD
Division of Gastroenterology
VA New York Harbor Healthcare Center
Brooklyn Campus, NY, USA
ayse.aytaman@med.va.gov

Gül Bahtiyar, MD
Health Science Center at Brooklyn,
Division of Endocrinology and Diabetes at
State University of New York, NY, USA
Samy I McFarlane, MD, MPH, FACP
State University of New York,
Kings County Hospital Center,
450 Clarkson Avenue, Brooklyn, NY, USA
Tel.: +1 718 270 3711
Fax: +1 718 270 6358
smcfarlane@downstate.edu