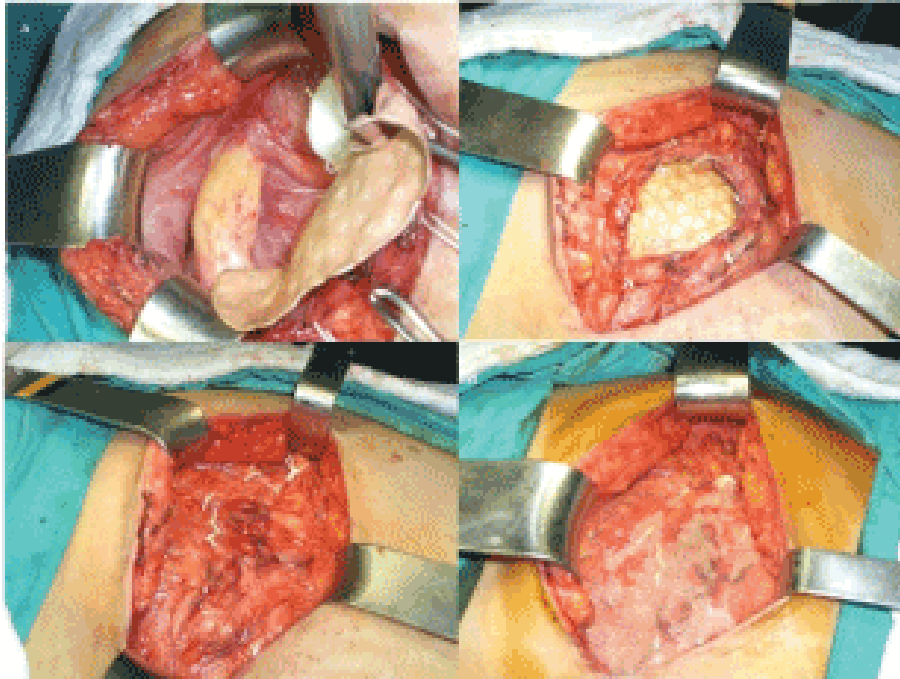


# Hernia because of iliac peak bone collecting-An image article



**FIGURE 1.** The deformity was fixed utilizing an e-PTFE work estimating roughly  $15 \times 15$  cm along these lines, the musculoaponeurotic tissue was re-approximated over the work.

## Description

Hernia improvement after iliac bone collecting was first depicted by Oldfield in 1945. The pace of lumbar hernia advancement after iliac peak bone collecting is 5%-9%. A hernia can happen between 24 days and 15 years after a bone gather.

Manifestations happened following 2 years postoperatively in our patient. Certain hazard factors are characterized, for example age, female sexual orientation, high BMI, frail abs, a full thickness bone unite gather, a deficiency of more than  $4 \text{ cm}^2$ , and ceaseless obstructive pneumonic malady.

**Elizabeth Swan\***

Open Access Publishers, 40 Bloomsbury Way, Lower Ground Floor, United Kingdom

---

## References

Willemot LB, Eby SF, Thoreson AR, et al. Iliac bone grafting of the intact glenoid improves shoulder stability with optimal graft positioning. *J Shoulder*

*Elbow Surg.* 24, 533-540 (2015).

Chappard D, Mabilieu G, Masson C, et al. Metaplastic woven bone in bone metastases: A Fourier-transform infrared analysis and imaging of bone quality (FTIR). *Morphologie.* 102, 69-77 (2018).

Ghodadra N, Gupta A, Romeo AA, Bach BR, et al. Normalization of glenohumeral articular contact pressures after Latarjet or iliac crest bone-grafting. *J Bone Joint Surg Am.* 92, 1478-1489 (2010).