

Dupuytren's disease: overview of a common connective tissue disease with a focus on emerging treatment options

Dupuytren's disease (DD) is a common, fibroproliferative disease of the palmar fascia of unknown pathology. DD blights the hand function of many individuals and yet it remains an unsolved conundrum. Despite clear knowledge of the anatomy of this aggressive disease and an ever-increasing understanding of the underlying pathophysiology, cellular mechanisms and genetic basis for the disease, curative treatment remains elusive. Described in the 18th century, some of the early surgical treatments remain central to management today, with the gold standard treatment continuing to be surgical removal of the diseased tissues. A plethora of nonsurgical and minimally invasive treatments have been tried with variable success; the efficacy and safety profiles of radiotherapy, steroid injection and injectable collagenase *Clostridium histolyticum* are explored in this article. There is also a broad range of surgical options, including percutaneous needle fasciotomy, limited or extensive fasciectomy, dermofasciectomy, salvage procedures and a variety of techniques to close the skin wound. Additionally, the role of skin grafting and the application of fat injection in DD will be discussed, with explanation of the comparative utility of each. Although a cure remains elusive, modern nonoperative management options are gaining increasing popularity. This review gives a detailed, comparative overview of each of the nonoperative and surgical treatments available to today's clinician and suggests a treatment algorithm to aid in management and decision-making in DD.

KEYWORDS: CCH • collagenase • Dupuytren • Dupuytren's disease • etiology • fasciectomy • fasciotomy • minimally invasive • nonoperative • PNF • radiotherapy • treatment

History

Felix Platter of Switzerland appears to have been the first to document what later came to be called Dupuytren's disease (DD) in his case report published in 1614 of a stonemason with digital contractures of his ring and little fingers. Unfortunately, he misattributed the deformity to contracture of the flexor tendons so was superseded by later anatomists who correctly delineated the fascial rather than tendinous nature of the contractions [1]. The medical literature has credited the first description of DD to the French military surgeon and anatomist Baron Guillaume Dupuytren (1777–1885) who published an account of his surgery on his coachman in *the Lancet* in 1834 [2]. However, it was actually the Englishman Henry Cline who, in the year of Dupuytren's birth, dissected two hands with palmar fascial contractures and first correctly described DD as a disorder of the palmar fascia rather than of the flexor tendons as previously thought [3]. Later, in one of his lectures, Cline suggested DD should be treated by open palmar fasciotomy and, in 1822, one of his eminent students, Sir Astley Cooper, demonstrated that percutaneous aponeurotomy (using a Cooper knife)

was also a successful treatment [3]. Dupuytren is known to have visited Cooper in 1826 but did not perform his first operative release of a fascial contracture until 1831 – he published a description of this in 1834 [4]. Irrespective of which of these early surgeons gains credit for discovering the disease, they all (Platter excluded) correctly noted the underlying anatomy of the disease and suggested treatments that are still used today.

DD is a benign but progressive fibroproliferative disease of the palmar fascia that often starts with development of fascial nodules, which may progress to the formation of cords along lines of tension within the volar surface of the hand. It may progress distally into affected digits (often entwining the digital neurovascular bundles within spiral fascial cord extensions) and can result in severe, irreversible digital contractures and considerable limitation of hand function [5]. It may present in one or both hands (although not always with symmetrical disease progression) and, although often not thought of as a systemic complaint, is commonly associated with several other fibroproliferative disorders (Garrod's knuckle pads [6], Peyronie's disease of the penis [7] and Ledderhose's disease of the plantar fascia) [1].

David Warwick^{*1},
Alexis Thomas²
& Ardeshtir Bayat^{*2,3}

¹Department of Orthopaedics,
University of Southampton, UK

²Plastic & Reconstructive Surgery
Research, School of Translational
Medicine, University of Manchester,
Manchester Interdisciplinary
Biocenter, 131 Princess Street,
Manchester, UK

³Manchester Academic Health Science
Centre, Department of Plastic &
Reconstructive Surgery, University
Hospital of South Manchester NHS
Foundation Trust, Wythenshawe
Hospital, Southmoor Road,
Manchester, UK

*Authors for correspondence:
davidwarwick@handsurgery.co.uk
and
ardeshirbayat@manchester.ac.uk

Strangely, despite often being in direct continuity with diseased fascia, it is thought not to affect the transverse palmar fascial fibers or Skoog's fascial fibers, which lie beneath the spreading plane of the disease [8], but affects all other palmar fascial structures, often sending contractile fibers into the skin (causing localized dermal pitting). The palmar pretendinous fascial band, extending from the mid-palmar crease to the digital base, becomes the pretendinous cord; the transverse fascial natatory ligament passing at the base of the digits and connecting the pretendinous bands becomes the natatory cord; the fascia passing from the base of the digit distally to cross the proximal interphalangeal joint (PIPJ) becomes the central cord; and, the spiral fibers that pass from the metacarpophalangeal joint (MCPJ) distally and dorsally to insert into the lateral digital sheets become the spiral cords (with the lateral sheets becoming lateral cords, which markedly contribute to the PIPJ contractures) [9]. All of these contractile cords envelop the digit and can be adherent around the MCPJ, PIPJ and distal interphalangeal (DIPJ) joint capsules, further limiting full joint mobility. These cords cause progressive fixed flexion contractures across the involved joints and increasingly limited joint mobility. Longstanding flexion deformities will lead to secondary contracture of the joint, especially the PIPJ.

Epidemiology & risk factors

The prevalence of DD varies by age, gender, geographical origin and ethnicity [10]. Primarily, it is a disease that presents from the fifth decade onwards but has been noted in a child as young as 9 years old [11]. It is also a predominantly male disease, with male:female incidence ratios ranging between 15:1 and 5:1 depending on the age of compared populations (the incidence in women increases significantly with age) [4]. Primarily a disease of Northern European Caucasians (its genetic preponderance in Scandinavia and people of the British Isles has been postulated to stem from early Germanic and Celtic tribal migration and resettlement) [9], its prevalence decreases as one examines ever more southerly European populations, presenting only sporadically in black African individuals [10,12]. It is also commonly found in white populations in North America, Australasia and Japan (interestingly, it appears rarely in China, perhaps due to Japan's historical comparative openness to foreigners and hence interracial genetic mixing) [13].

There is an obvious genetic component, as observed by twin concordance studies, ethnic and familial clustering [14]; however, the mode of

inheritance is variable: it presents as Mendelian autosomal dominance with incomplete penetrance and has also been described as showing complex trait with oligogenic inheritance [15]. DD also appears in individuals without a known family history of DD, so-called sporadic cases [16]. In families with a strong expression of the disease, DD tends to present earlier and progress faster (often termed the Dupuytren's diathesis, first described by Hueston) – unfortunately, these groups also tend to develop aggressive rapid recurrence postintervention [17]. Specific causative genetic linkage is slowly becoming clearer: the 6cM region on chromosome 16q has been positively linked with DD [16] and a gene, *IRX6*, found within the same region has been noted to be upregulated in DD [18,19]. Studies at the chromosomal level are also starting to pay dividends: several cell culture studies have shown chromosomal aberrations (trisomy of 7 and 8, loss of Y chromosome [20]) although there have also been suggestions that these findings may be due to culture amplification of non-DD cells [18].

The etiology of DD remains complex and without an overarching patho-etiological model to tie all the contributing factors together (FIGURE 1). It has been linked with varying degrees of significance to diabetes mellitus [21], smoking [22], excessive consumption of alcohol [23], elevated serum lipid levels [24], exposure to anti-epileptic medications (previously it was causally linked with epilepsy but this appears to have been disproven) [25], local traumatic injury (leading to algodystrophy) [26] and occupational exposure [27,28]. It has been suggested that some of these apparent semi-causal associations are closely linked with recurrent microangiopathic ischemia, causing production of free radicals, which in turn stimulate cytokine release and fibroblast proliferation [29]. This free radical theory is supported by a finding of sixfold higher hypoxanthine levels (involved in the production of oxygen free radicals) in DD tissues when compared with healthy palmar fascia [30]. Others have suggested that DD pathogenic pathways may involve aberrant immune response mechanisms and altered wound healing [18]. Immunological alterations associated with DD include higher autoantibodies against collagen I–IV in DD patients, which drop several months after surgical resection of the diseased tissues [31,32]; and alterations in HLA antigen distribution – a 2.3-fold increased risk of DD has been noted in those with the HLA-DRB1*15 genotype [33], although the statistical significance of other HLA alterations remains unclear [18]. The altered wound healing hypothesis is based on the fact

that both wound healing and DD share similar changes in biochemistry (altered extracellular matrix protein and proteinase metabolism) and collagen metabolism, coupled with the prevalence in DD of contractile fibroblasts also found in active stages of contractile wound healing, termed the myofibroblast [18].

Cell biology

Similar to the physiological processes involved in wound healing, DD tissues have demonstrated increased fibroblast numbers [34], differentiation of fibroblasts into contractile myofibroblasts [35] and upregulated deposition of extracellular matrix proteins (especially collagen III) [36]. Luck was the first to describe the three distinct histological stages of DD [34]. Firstly, within

the cellular, maximally biologically active proliferative stage, there is local fascial fibroplasia secondary to increased fibroblast production, these cluster into characteristic nodules but are not affected by any linear tissue stresses. Next, in the involutional stage, the fibroblasts differentiate into myofibroblasts, which form along the palmar axes of mechanical tension: the intracellular actin microfilaments are acted upon by a variety of cytokines coupled with the external mechanical tension triggering progressive contractile behavior and the formation of DD cords. Finally, in the residual phase, the cellular elements regress leaving the inelastic, relatively acellular, tendon-like collagen structures that cross the small hand/digital joints causing the pathognomonic fixed flexion cord contractures [34].

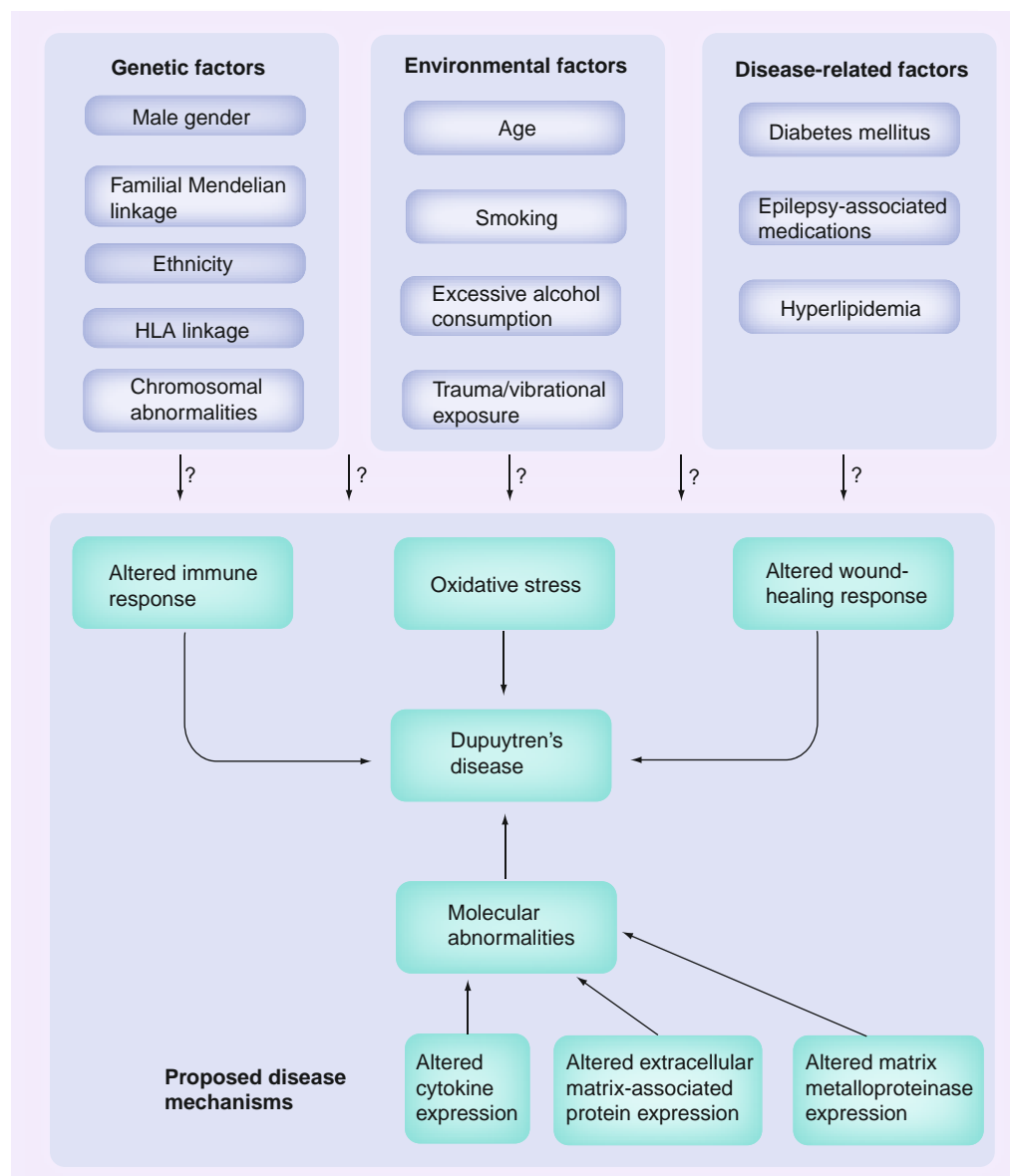


Figure 1. Overview of our current understanding of Dupuytren's disease etiopathogenesis.

Grading

■ Range of movement

A quick, simple assessment of disease severity is provided by Hueston's tabletop test, where the patient is asked to place the affected palm flat on a tabletop; those able to do so still retain enough palmar flexibility to allow adequate hand function and are deemed to have early DD not meriting intervention. More extensive DD can be measured simply, objectively and reproducibly with a goniometer, allowing accurate assessment of disease progress or treatment effect. The loss of extension in each joint is measured, following which the total loss (MCPJ + PIPJ + DIPJ) is summated. Tubiana suggested four categories of deformity – (stage I: 0–45°; stage II: 45–90°; stage III: 90–135° and stage IV: 135–180°) [37]. Patients with a severe PIPJ contracture often demonstrate associated hyperextension of the DIPJ (the boutonniere deformity) in which the summative total extension loss is not valid. Despite this, goniometer measurements remain useful as they are objective and thus minimize interobserver variability of assessment of disease progression. However, total extension loss is not a patient-related measure and the correlation between deformity and function is weak [38,39]. Objectively measured deformity does not appear to capture the multifactorial nature of patient-experienced disability. The involvement of multiple digits, which is common in DD, can also confound the correlation between deformity and function [40].

■ Generic hand function scores

The relevance of patient-related outcome measures is now broadly accepted. They provide a quantitative measurement of disease impact on hand function and patient quality of life and guide the appropriate timing of interventions. There are several scoring schemes available for measuring hand function, such as the Disability Assessment of Shoulder and Hand (DASH) questionnaire [41], QuickDASH [42], Michigan Hand Score [43] and the Patient Evaluation Measure [44]. However, these are generic, pan-disease measures without a specific focus on the changes found in DD and hence they are not specific enough for the functional difficulties posed by the contracture. DD may cause only one or two functional issues in an individual; the scoring schemes include too many other factors so that even a large change in the DD-related hand function will not influence or alter the overall score. The creation of a validated DD-specific patient-reported quantitative scoring system

would be of considerable use in the clinical assessment of DD in the future.

Indications for treatment

There are no clear guidelines for treatment as the disease progresses at a different rate (which remains unquantifiable in the absence of an objective staging system) in every individual. This also reflects on the variable experience of each individual when affected by the disease. The so-called 'tabletop test', when the patient cannot flatten the down-faced hand on the table, is too basic an indicator prior to embarking upon treatment. The test depends upon hyperextensibility of the MCPJ because even a severe contracture can be compensated in this way. Additionally, the test does not measure the patient's functional difficulties despite a positive tabletop test. As a result, it is considered inappropriate to recommend treatment that may have adverse events and a potential risk of deteriorating the patient's condition, outweighing the benefits of any treatment option. Of note, is cost implications for the private patient or the healthcare provider, unless there is a clear benefit from undertaking a treatment that is shown to objectively improve the degree of functional impairment caused by the disease.

The indications for treatment may also be influenced by the rate of progression; a 90° PIPJ contracture is technically difficult to correct surgically. Therefore surgery, if contemplated, should be undertaken while the disease is at an earlier stage and surgically simpler to undertake. Conversely, a 90° MCPJ contracture is much earlier to correct so delay is not such a concern. The risks and benefits of each treatment option should be considered as part of the process when deciding on the most appropriate treatment modality and surgical indications in an individual patient.

Treatment overview

It should be recognized that DD cannot be cured. Current treatment options merely manage the consequences of the disease – the development of a contracture. The disease etiopathogenesis is unknown and we remain unaware of the reasons behind initiation and provocation of contracture of the fascial bands affected by the disease. Better understanding of the disease mechanism and the variability in pattern and progression of DD may provide an opportunity for development of a cure. The management of DD, however, remains controversial, with a broad range of treatments available: from the purely observational ('watch-and-wait') approach in those with

disease not currently causing notable impairment of their hand function to the nonoperative (e.g., radiotherapy, steroids, injectable collagenase *Clostridium histolyticum*), through to surgical incision (percutaneous aponeurotomy) or excision of DD contracture cords (fasciectomy, dermofasciectomy) and finally to surgical salvage operations (e.g., digital amputation).

No method is curative; all aim to palliate the effects of DD on hand function. In addition, to date, there has been no consensus on the precise objective definition of recurrence, hampering the direct comparison of the available treatment modalities. A recent systematic review of 2155 references showed 69 papers that met inclusion criteria, only three of which provided level I evidence. The review authors concluded that there was no compelling evidence to support one treatment over another, but did note a particularly high recurrence rate after needle fasciotomy [45]. FIGURE 2 suggests a treatment algorithm for selecting the most appropriate treatment modality and TABLE 1 gives a comparative relative value assessment of each management option.

Nonoperative treatment

■ Observation

DD has an uncertain prognosis. In some individuals it progresses rapidly over a period of months, while in others it takes years for a small degree of progression or remains clinically static. None of the currently available treatments can guarantee prevention of disease progression, nor disease recurrence. In addition, following treatment, the disease may develop *de novo* beyond the treatment field or recur within the treatment field itself. As all available treatments carry some degree of risk, it remains sensible to observe the disease until there is an identifiable functional problem that outweighs the risks of intervention.

■ Splinting

There is no evidence that the use of a splint (either static or dynamic) alters the rate of progression or reverses the contracture. Furthermore, postoperative splinting has been shown in randomized comparisons to make no difference to outcome [46,47].

■ Radiotherapy

External beam radiotherapy is applied over several days until the planned dose has been administered (usually approximately 15 Gy in five fractions) [201]. The mechanism of action of radiotherapy is not well understood [48], but is thought to be effective only in the early cellular

stage of the disease when the fibroblasts are actively proliferating, the expression of certain growth factors, such as TGF- β are upregulated and the monocyte-macrophage system (involved in myofibroblast proliferation) is activated [49]. The NICE commented in its guidance that there is limited evidence for radiotherapy and that further studies are needed into the short- and long-term efficacy and safety of the treatment [201].

The evidence for radiotherapy is mainly derived from the German literature. Betz *et al.* retrospectively reported the long-term outcome of radiotherapy in 135 patients over a follow-up period of 13 years, finding 59% had stable disease, 10% showed disease regression and 31% had progressive disease (with the primary end point being Tubiana's measurement of disease stage) [48]. Of the 87 patients experiencing local symptoms (paraesthesia, itching, tension/pressure sensation) pretreatment; 16% showed complete relief, 18% good relief, 32% minor relief and 14% had no change. However, 32% showed minor long-term radiogenic skin changes with 23% showing dry skin and grade I-II desquamation, 7% demonstrating skin atrophy with grade II telangiectasia and 2% showing local erythema lasting up to a year post-treatment. Approximately 20% required secondary surgical management, with 5% of these cases undergoing delayed wound healing. There was no secondary malignancy noted. In a randomized trial by Seegenschmiedt *et al.*, 129 patients were given either 30 Gy or 21 Gy and were followed up for 1 year. Again, the primary end point was improvement in Tubiana classification. Both groups demonstrated significant improvement in scoring: 56% (30 Gy) and 53% (21 Gy) showed disease stage regression; 37% (30 Gy) and 38% (21 Gy) showed stable disease; 7% (30 Gy) and 9% (21 Gy) had progressive disease. Both groups (44%) had mild acute skin effects and 5% showed chronic skin effects (dryness, desquamation, skin atrophy and sensory alteration) [49].

Pohl *et al.* reported on 110 patients randomized to receive two different radiation doses, finding no difference in side effects of acute or chronic skin changes (~15% for each). There were no efficacy end points or clear dosage data [50].

Finally, a smaller, early series of 25 patients by Fenney reported that 75% showed some improvement at 2–10-year follow-up and, of these, 25% showed full recovery, 25% partial recovery and 25% showed only slight improvement (recovery was not clearly defined) [51]. Peak improvement

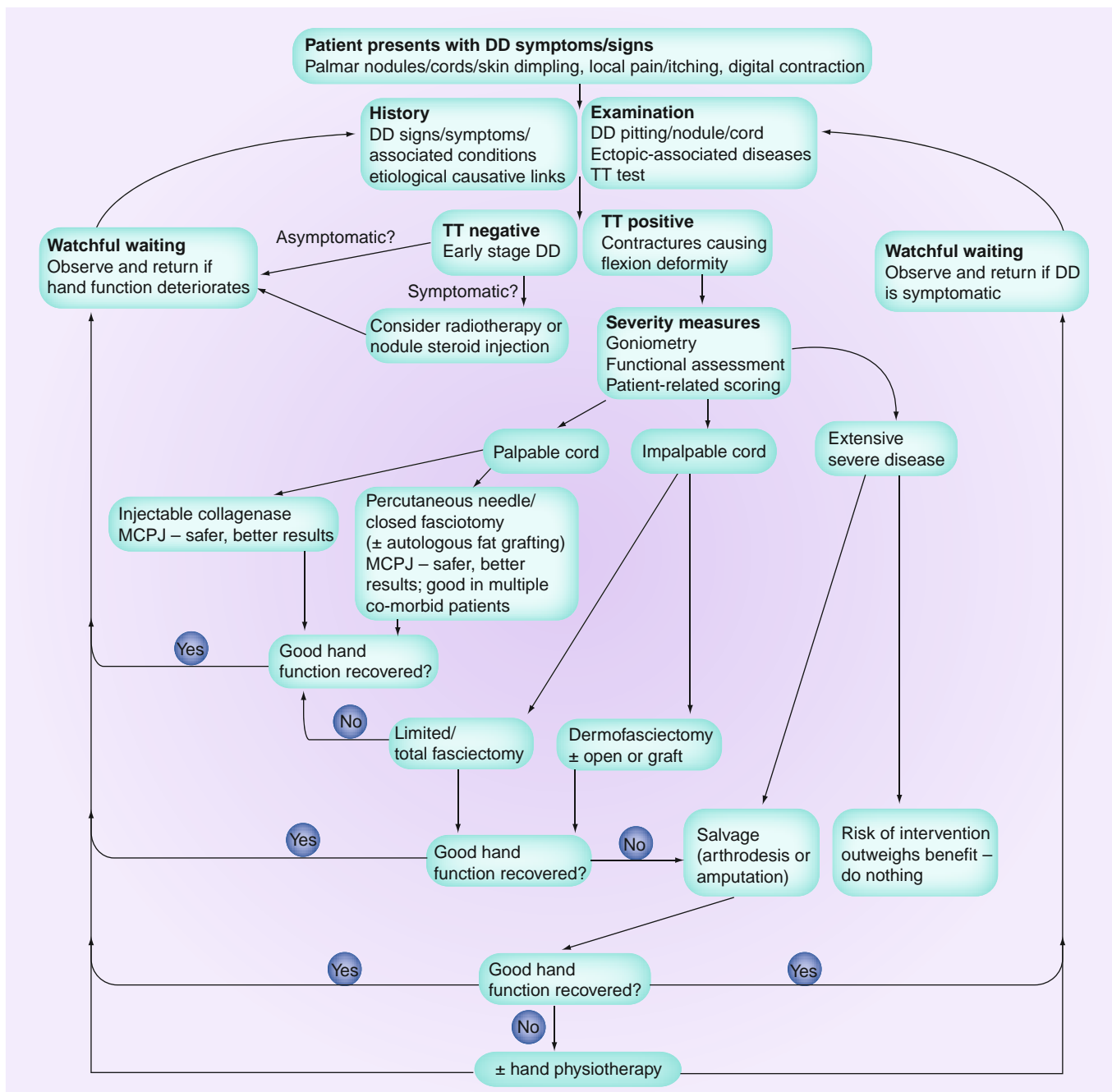


Figure 2. Suggested treatment algorithm for easy selection of the appropriate management modality for patients with Dupuytren's disease.

DD: Dupuytren's disease; MCPJ: Metacarpophalangeal joint; TT: Tabletop.

occurred by 6 months and the side effects of skin dryness or erythema were noted (with no reference to how many subjects were affected).

■ Other methods

Various agents have been tried without significant improvement in DD digital contracture. These include IFN- γ [52], dimethyl sulfoxide [53], vitamin E [54], methylhydrazine [55], allopurinol [56], ultrasonic therapy [57], physical therapy [58] and calcium channel

blockers [59]. Steroid injection has shown some success to date on nodule resolution [60,61] and injectable collagenase *C. histolyticum* on cord dissolution.

■ Steroid Injection

Steroid injections reduce fibroblast proliferation and increase apoptosis in both fibroblasts and inflammatory cells in DD [62]. There is some evidence that treatment may be of clinical benefit although steroid injections are not commonly

considered. Ketchum and Donohue reported 63 patients who had an average of 3.2 injections; 97% regressed (defined by softening and flattening of the injected nodules) by 60–80% but complete resolution was rare and there was 50% recurrence within 1–3 years of the primary injection. Complications included skin atrophy and depigmentation in approximately 50% of patients, resolving within 6 months of final injection [60].

Injectable collagenase

C. histolyticum

The section on the cell biology of DD describes the dominant role of abnormal collagen production in DD. Therefore, direct dissolution of the abnormal collagen is a logical and enticing treatment option. It is this premise which led to the development of a specific collagenase.

■ Structure & activity

Xiapex®/Xiaflex® (the UK and US trade name respectively, hereafter referred to as Xiapex) is a combination of two classes of purified collagenase *C. histolyticum* (CCH) that are derived from the fermentation of the bacterium *C. histolyticum*. These collagenases (AUX-1 and -2) hydrolyse the triple helical collagen into small peptide chains. According to the manufacturer's account, endogenous human collagenase then acts to further lyse the collagen. Xiapex is least active against type IV collagen, which is contained in vascular basement membranes and the perineurium. These structures are therefore relatively safe; the type II collagen contained in DD is also densely represented in tendon, tendon sheath and ligament. These structures are therefore vulnerable to inaccurate injection.

This risk should be mitigated by experience in injection procedures in the hand, in the surgical management of DD and specific training in the use of Xiapex.

■ Development

Very early work with less specific clostridial collagenase in Peyronie's disease led to more specific collagenase development [63]. Initial Phase II trials by Badalamente, Hurst and Hentz [64] showed clinical potential, which then led to Phase III randomized efficacy studies [65,66]. These studies supported successful US FDA and EMA approvals in 2010 and 2011, respectively and this CCH is now commercially available.

■ Data

CORD I study

The CORD I study [65] involved 16 centers in the USA in a double-blind, randomized control multicenter Phase III study with 308 patients receiving 741 injections (444 collagenase; 297 placebo). Approximately 64% of the collagenase group and 6.8% of the placebo group had a correction to within 5° of neutral ($p > 0.001$). The overall range of movement improved from 43.9° to 80.7° (CCH) and 45.3–49.5° (placebo). 96.6% had an adverse event (CCH) versus 12.2% (placebo), although most were trivial and transient (swelling, bruising, injection-site pain, axillary tenderness) there were three major adverse events: two flexor tendon ruptures and one case of complex regional pain syndrome (CRPS).

CORD II

The CORD II was a double-blind, randomized control trial of 66 patients from five Australian

Table 1. Relative value of each treatment technique for the management of Dupuytren's disease.

Method	Ease Difficult + Easy +++++	Evidence Weak + Strong +++++	Efficacy High + Low +++++	Safety Hazardous + Safe +++++	Cost Expensive + Cheap +++++	Efficacy Ineffective + Effective +++++	Efficacy Low + High +++++
Steroid	+++++	+	Unknown	+++	++++	Unknown	Unknown
PNF	++++	+++	+	++	+++	++	++++
Radiotherapy	+	+	Unknown	Unknown	+	Unknown	Unknown
Fasciotomy	+++	++	++	+++	+++	++	+++
Fasciectomy	++	+++	++	++	++	+++	++
Skin graft	+	+++	++++	++	+	++++	+
Collagenase	+++	++++	+++	+++	+	++++	++

The technique should be tailored to the individual's functional demands and specific nature of the disease as different patients and different cords require different treatments.

PNF: Percutaneous needle fasciotomy.

Indications and precautions

Indicated in adults with palpable DD cord(s)

Use with caution and only if clearly indicated in pregnancy; no data available for use in breastfeeding women or pediatric patients

Use with caution in patients with clotting disorders or in those who have taken anticoagulants (except low-dose aspirin) in last 7 days

Use careful, joint-specific injection technique (as per below)

MCP joint contractures

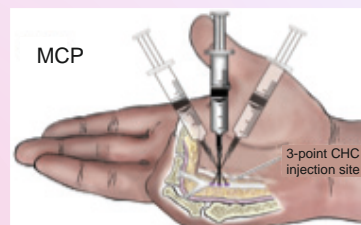
Insert needle at point of maximum bowstringing of palpable cord

NB. Skin to flexor tendon distance = average 7 mm

0.25 ml sterile reconstituted CHC solution

Vertical needle insertion

3-point distribution of each total injection volume



PIP joint contractures

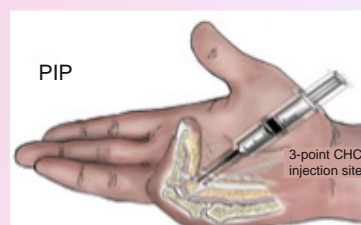
Insert needle not more than 4 mm distal to palmar digital crease to 2–3 mm depth (NB bevel = 1.25 mm)

NB. Skin to flexor tendon distance = average 4 mm

0.20 ml reconstituted CHC solution

Needle insertion – horizontal to cord

3-point distribution of each total injection volume



Post-injection aftercare

Post-injection, wrap hand in bulky gauze dressing and elevate for the rest of day

24 h post-injection, patient returns for passive digital extension to rupture cord - use moderate pressure for 10-20 s;

if cord does not rupture, passive extension can be repeated up to three-times at 5-10 min intervals

If cord rupture is not achieved, the procedure may be repeated up to three-times at 4-weekly intervals

Following cord rupture, patients should use a night splint and perform digital flexion/extension exercises several times per day for 4 months

Figure 3. Overview of Xiapex® administration technique.

CHC: *Clostridium histolyticum* collagenase; DD: Dupuytren's disease; MCP: Metacarpophalangeal; PIP: Proximal interphalangeal.

Reproduced with permission from [4].

centers [66]. There was a 70.5% decrease in joint contracture to within 5° of neutral (CCH) compared with 13.6% (placebo; $p \leq 0.001$). The mean increase in movement was greater in the CCH group (35.4°) than in the placebo group (7.6°; $p \leq 0.001$), with only one major adverse event of a flexor tendon pulley rupture (no flexor tendon ruptures or allergic reactions were noted).

Administration

Experience in the surgical management of DD and formal training in the administration of collagenase is mandatory. A technical overview is provided in Figure 3. The drug is provided in two vials, one containing CCH as a lyophilized powder and the other containing a sterile diluent. The contents of the vials are mixed and the reconstituted drug is administered by careful injection into the palpable cord. The injected volume is small (0.2 ml into PIPJ contractures to 0.25 ml into MCPJ contractures) and accurate injection is essential. After administration,

the cord may passively rupture overnight prior to any manipulation. More commonly, the following day the digit is passively extended, the enzymatically weakened cord contracture generally ruptures on digital extension, however, a second or third injection, given at least 30 days apart, is sometimes required. At present, the manufacturer suggests only one cord to be injected at each clinic visit. Also, their protocol suggests a night splint to be worn and daily prescribed hand exercises to be undertaken for 4 months following successful treatment.

Recurrence

Watt, Curtin and Hentz followed up eight patients for 8 years post-Xiaflex injection (however, not all cases had received the same CCH dose) [67]. Two patients (with MCPJ contractures) had no recurrence. Of those with recurrence, four MCPJ contractures worsened from 9° from full extension at 1-week postinjection to 23° at 8 years and two PIPJ contractures worsened

from 8° from full extension at 1 week to 60° at 8 years.

The latest unpublished data presented at the American Society for Surgery of the Hand [68] showed a recurrence rate at 2–5 years post-CCH injection of approximately 13% for MCPJ and 34% of PIPJ contractures.

Side effects & complications

Combined results of the CORD I and II studies found that bruising occurred in 70% and hemorrhage in 38% of the injection sites. Skin tears occurred in at least 5%. A rare but important complication was flexor tendon rupture, occurring three times across Phase I, II and III studies in 1082 patients (0.3%). This was due to the similar collagen types in both tendons and DD, with presumed inadvertent injection too deeply, directly into the flexor tendon. These ruptures all occurred when injecting within the proximal phalanx for PIPJ contractures. It is now recommended that the injection be given no more than 4 mm distal to the proximal flexion crease of the finger to avoid this complication.

Other rare complications included a single presentation of CRPS (0.1%) and one digital nerve injury (0.1%) in the 1082 patients in the two Phase III trials.

Immunogenicity

At 30 days after the first injection of Xiapex, antibodies against AUX-1 (92%) and AUX-2 (86% of patients) were detectable. After four injections, all patients had high antibody titers against both AUX-I and -II. Neutralizing antibodies to either AUX-I or -II were detected in 10 and 21%, respectively. However, these immunogenic responses did not appear to correlate with clinically important side effects. Mild pruritis occurred in 15% and at least 5% demonstrated injection-site edema, local pain, localized erythema, peripheral swelling, upper limb and axillary pain, lymphadenopathy and associated nodal tenderness. All side effects were deemed to be mild and transient. Despite the lack of anaphylaxis so far (in any trials to date and since the increasingly widespread commercial usage of the drug), severe allergic reaction remains a possibility (and thus countermeasures should be available prior to its administration).

Surgical management

■ Percutaneous needle fasciotomy

This procedure involves the physical disruption of a discrete DD cord via multiple needle passes through the cord fibers [69]. The skin is

anesthetized with ethyl chloride or with a small bleb of intradermal lignocaine; however, the digit itself should not be anesthetized to enable sensation of proximity to the digital nerve. A fine needle is passed through the skin and into the cord, with the patient being asked to gently flex and extend the digit prior to cutting with the needle to ensure there is not over-penetration into the underlying flexor tendon. The cord is 'peppered' repeatedly with the needle (i.e., pierced multiple times around the puncture-site region), the finger being held passively in extension to maintain tension within the fascial cord. The tension reduces risk to the underlying digital nerve and flexor tendon whilst inducing rupture when enough collagen fibers have been disrupted. Several digits can be treated at the same time [70].

The advantage of percutaneous needle fasciotomy (PNF) is rapid recovery and the low cost of a simple office-based intervention. In the only randomized study (n = 166), van Rijssen *et al.* compared PNF to open fasciectomy, finding a 63% improvement in the total passive extension deficit with PNF and a 79% improvement with open fasciectomy; the complication rate for PNF was 0% compared with 5% for surgery [71]. Recovery of function was quicker for PNF, with full hand use at 1 week post-PNF versus 27–56 days post-limited fasciectomy [71]. In other studies, a 72% early 'improvement' in 171 patients was reported [72], and Badois *et al.* reported an 81% improvement in 138 patients [73].

Digital nerve & tendon damage

The risk varies between studies from 0% [71,72,74] to 2% [73]. The injuries were, with one exception, from digital rather than palmar needling. This higher risk with digital PNF and the consistently better results in the literature for MCPJ versus PIPJ contracture release suggest that the technique is best reserved for MCPJ contractures [75,76].

Skin tears

Badois *et al.* reported skin tears in 16% of 138 patients [73]; van Rijssen and Werker reported tears in 46% of 60 patients [76].

Recurrence

As the cord is only ruptured rather than fully removed, the recurrence rate is substantially higher than other modalities. Prospective studies report a recurrence requiring surgery of 20% at 2 years [74], 65% at 33 months [76], 58% at 3.2 years [77], 41% at 5 years [72], and 50% at 5 years [73].

The NICE [202] and recent authors [74] support the use of this technique as it is simple and safe, particularly for older patients unsuitable for more major surgery.

■ Closed fasciotomy

This is a very similar technique to PNF, using small single-scalpel stab incisions rather than multiple needles passing through a discrete DD cord under local anaesthetic. Unsurprisingly, again this is more suitable for the MCPJ rather than PIPJ contracture, with approximately 43% recurrence of MCPJ contractures at 5 years [75,78].

■ Fat grafting

Hovius *et al.* recently described an extensive percutaneous aponeurotomy coupled with filling of the resultant defect with autologous fat aspirate. The rationale behind this method was the known positive regenerative fat stem cell effect in softening scars, the possible 'fire break' effect of a fat graft between the ruptured DD cord fibers and the provision of replacement subcutaneous fat bulk to the deficient DD-affected areas [79]. In 99 patients, flexion contracture improved from 37 to -5° from neutral at the MCPJ and from 61 to 27° from neutral at the PIPJ. Around 95% of patients were satisfied and normal hand use resumed within 2–4 weeks. Complications included one digital nerve injury, one postoperative wound infection and four cases of CRPS. Follow-up in this study was only 44 weeks, so longer term durability and its role compared with other techniques needs further study [79].

■ Limited fasciectomy, dermofasciectomy & grafting

These open techniques involve variable removal of the macroscopically involved fascia; in limited fasciectomy only apparently diseased fascia is resected; whereas in dermofasciectomy all diseased palmar fascia is excised along with any overlying involved skin. It is postulated that the potential for recurrence in limited fasciectomy is harbored in residual fascial connections to the skin and within the lateral digital sheets, to which access is restricted. The extent of limited fasciectomy resection is variable, depending on the preference of the surgeon and the distribution or severity of the disease. One or several small segments can be removed through small incisions, breaking the continuity of the cord [80]. Alternatively, the entire macroscopically visible cord is removed. The degree of correction

correlates with the preoperative deformity [81]. Some surgeons also utilize adjunctive release of the contracted PIPJ capsule. However, whilst increasing correction perioperatively, this may cause pain, stiffness and joint instability, with no strong evidence of durable postoperative correction [82].

Dermofasciectomy was first recommended by Hueston in 1984. Excision of the skin as well as the underlying diseased fascia allows removal of all the DD collagen filaments extending between the DD fascia and skin, minimizing the risk of recurrence [83]. The resultant skin defects can be primarily closed, partially left open to close by secondary intention, such as the McCash technique or grafted with either autologous skin or with a growing number of biosynthetic or biological skin substitute grafts. The literature demonstrates low recurrence rates following dermofasciectomy with skin grafting. Tonkin *et al.* reported no appreciable recurrence over 9–90 month follow-up in 35 patients [84]. Armstrong *et al.* reported a recurrence rate of 11.6% out of 103 sampled patients at mean follow-up of 5.8 years [85]. Brotherston *et al.* reported 0% recurrence in 34 patients at mean follow-up of 100 months [86]. While there are no randomized studies (to remove case selection or technical skill bias), these results suggest a reduced recurrence compared with any other needle or surgical intervention.

Skin closure

The palm can be primarily closed or left partially open to heal by secondary intention [87]. Clinical experience shows that small defects in the digits will also heal uneventfully when left open. There are several ways to close the skin, including Z-plasty [88], broad laterally based V incisions [89], V-Y advancement flaps [90] and local rotation flaps [91]. A randomized comparison of longitudinal incision closed with Z-plasties or a modified Bruner incision closed by V-Y plasties in 79 patients found a nonsignificant difference in recurrence rates at 2-year follow-up (33% with modified Bruner; 18% with Z-plasty) [92]. In another comparison of closure technique, 79 patients were randomized to either open fasciectomy with primary Z-plasty closure or dermofasciectomy with insertion of a 'firebreak' graft (a full thickness skin graft that is postulated to break the line of DD recurrence via excision of overlying presumed-diseased skin and interposition of healthy skin graft that blocks disease spread) [83]. No significant improvement was noted in recurrence rates at 3 years

with fire-break grafts over Z-plasty closure [93]. In another randomized comparison of direct closure of a transverse palmar wound versus full thickness hypothenar skin graft insertion in 27 patients, a significantly improved recurrence rate at a mean of 2.2 years was noted (50% recurrence in primary closure group vs 15% in the grafted group) [94]. Finally, as an alternative to skin grafting in advanced DD with postfasciectomy digital skin defects, simple local transposition flaps, such as the Jacobsen flap, have been found to be very effective [91].

Recovery rates

Return to work is important, particularly when comparing treatments. Percutaneous techniques are likely to have an important clinical advantage in this regard. Tonkin *et al.* reported a return to manual work at 8.5 weeks for fasciectomy (compared with 8.9 weeks for skin grafts) and 3.8 weeks for clerical work (compared with 5.7 weeks for skin grafts) [84].

Complications

Commonly noted surgical complications include pain, infection, scarring, bleeding, hematoma formation, damage to nerves or blood vessels and CRPS. The digital nerves are vulnerable in DD surgery: authors have reported nerve injury in 1.9% [95], 5% [71] and 7.7%, respectively [96]. In a study of 253 patients, Bulstrode *et al.* reported six nerve injuries, one arterial injury, 24 infections, six cases of CRPS and five hematomata; the complication rate appeared to correlate with deformity [97]. Denkler reviewed the English literature and found that arterial injury is ten-times more likely, and nerve injury five-times more likely, with surgery for recurrent disease than for primary disease [98].

Recurrence

The reporting of recurrence is confounded by the absence of a clear definition of recurrence. Furthermore, it can be difficult to distinguish between recurrence (return of disease in a previously treated site) or extension beyond previously treated margins (appearance of disease in a new site). Some might regard recurrence as the mere appearance of another nodule in the treated site; others might expect further treatment before defining recurrence. Standard literature definitions, and more randomized trials with prolonged follow-up, would help compare recurrence rates between treatments. It is generally held that recurrence increases with time; a systematic review by Becker and Davis reported

recurrence rates of 0–71% [45]. Bulstrode, Jemec and Smith reported recurrence in 33% of patients followed up for 9.4 years [97]; and, Tonkin reported 46.5% recurrence at a mean follow-up of 38.8 months [84].

■ Postoperative splinting

There is no clear evidence that splinting is needed after surgery. Identification of which patients may benefit from splinting and the duration of any such treatment is arbitrary and is a matter of clinical judgment by the surgeon and hand therapist.

■ Salvage procedures

Severe contractures that have failed to respond to surgery, or those which have recurred despite skin grafting, may be considered for a salvage procedure: either joint arthrodesis or digital amputation. The goal of arthrodesis is to fuse the affected joint, usually the PIPJ, into a better functional position [99]. Without gaining such a position, the patient hand function and thus quality of life, is greatly impaired and amputation must be considered [38]. Once all other DD management options have failed, partial or complete digital amputation can be a positive step, allowing the unaffected fingers to be freed for use in daily activities such as writing, personal hygiene activities and sports, reinvigorating patient quality of life. However, the side effects of amputation, which include cold intolerance, phantom pain, terminal neuroma, grip weakness and the psychological reaction, should not be underestimated.

■ PIP contracture

Prolonged deformity of the PIP joint because of a cord passing in front of it can lead to secondary contracture of the PIP joint. The PIP joint may still not straighten following thorough surgical removal of the DD tissues. The management of this is controversial. The PIP can be released but that may lead to pain, recurrence, slower rehabilitation and, on occasions, hyperextension laxity. Although there is no consensus, many surgeons will accept the correction achieved by removal of the Dupuytren's cord without need for further surgical attention to the PIP joint, whereas others will release the joint [100].

An external fixator is a technique that has been proposed as a potential method of correcting PIP flexion contractures and can be used either before or after the formal Dupuytren's surgery [101].

Conclusion & future perspective

Our understanding of the complex basic science and new management options of this prolific, fibroproliferative disorder have increased dramatically over recent years. Despite this, the gold standard treatment remains the same as that previously suggested when the disease was first discovered (surgical excision of the diseased palmar fascial cords). New nonsurgical options, such as injectable collagenase, give hope that the management of this disorder will show increased ease of treatment administration and extension of disease-free remission periods prior to the often inevitable disease recurrence and may also provide decreased treatment-associated morbidity and healthcare costs.

The disease still remains incurable and this will continue to be the focus for future

research. Despite important recent progress in coalescing the ever-growing basic scientific understanding of the mechanisms underlying DD into a cohesive pathophysiological disease model, there are still questions that need answering: What actually causes DD? Can we design a DD-specific measure that correlates objective deformity with patient-perceived hand function? What is the most cost-effective management option in the current treatment armory? Can we create a drug that inhibits the contractile actions of myofibroblasts? Could we use our understanding of the genetic basis of the disease to prevent disease onset in those with familial Dupuytren's diathesis? Could the creation of an overarching patho-etio-physiological model allow us to develop a disease cure?

Executive summary

History

- Dupuytren's disease was first described by Platter in 1614, then in 1822 by Cooper.
- It was popularized by Dupuytren in 1834.
- Benign progressive disease of the palmar fascia.
- Associated with fascial disease in the foot (Ledderhose's) and penis (Peyronie's).

Epidemiology & risk factors

- Male predominance in younger patients.
- More prevalent in northern European caucasians.
- Variable genetic penetrance, worse in those with Dupuytren's disease diathesis (originally described by Hueston).
- Complex etiology, associated with diabetes, anti-epileptic medications, trauma, alcohol consumption and hyperlipidemia.

Cell biology

- Increased fibroblast numbers and activity.
- Three stages of disease formation (Luck's hypothesis): local fascial hyperplasia, differentiation into myofibroblasts and finally developing into hypocellular collagen cords.

Grading

- Tabletop test (originally described by Hueston).
- Total loss of extension measured with goniometer (advocated by Tubiana).
- Hand function scores.

Nonoperative treatment

- If no functional problems, perform regular observation rather than treatment.
- Steroid injection can reduce nodules.
- Radiotherapy may reduce progression but evidence is weak.
- Collagenase *Clostridium histolyticum* (Xiapex®):
 - Temporary side effects common but important effects rare
 - 20–30% recurrence at 3 years
 - Lyses collagen in Dupuytren's tissue
 - 65–70% have a full correction; highest success in cords across metacarpophalangeal joints

Surgical management

- Percutaneous needle fasciotomy: high early success rate and complications rare; but high recurrence rate; particularly suitable for tight cords across metacarpophalangeal joints in lower-demand patients.
- Closed fasciotomy: simple but high recurrence.
- Fasciectomy: varying amounts of tissue can be removed; surgical complications may occur; different techniques available for skin closure.
- Dermofasciectomy and skin grafting: lowest recurrence rate but complex surgery.

Until these questions are answered, the clinician is left with a broad range of effective extemporizing treatments to choose from, which can allow a patient-centered approach to the successful management of DD.

Financial & competing interests disclosure

D Warwick has received consultancy fees from Pfizer in consideration of provision of training material and

academic/marketing advice, and honoraria for lectures on Dupuytren's disease. A Bayat has received an investigator award from Pfizer. The authors have no other relevant affiliations or financial involvement with any organization or entity with a financial interest in or financial conflict with the subject matter or materials discussed in the manuscript apart from those disclosed.

No writing assistance was utilized in the production of this manuscript.

References

- Caufield RJ, Edwards SG. Dupuytren disease: an update on recent literature. *Curr. Orthop. Pract.* 19, 499–502 (2008).
- Dupuytren G. Permanent retraction of the fingers, produced by an affection of the palmar fascia. *Lancet* 2, 222–225 (1834).
- Hutchison RL, Rayan GM, Astley Cooper. His life and surgical contributions. *J. Hand Surg.* 36, 316–320 (2011).
- Thomas A, Bayat A. The emerging role of *Clostridium histolyticum* collagenase in the treatment of Dupuytren disease. *Ther. Clin. Risk Manag.* 6, 557–572 (2010).
- Bayat A, McGrouther DA. Management of Dupuytren's disease – clear advice for an elusive condition. *Ann. R. Coll. Surg. Engl.* 88, 3–8 (2006).
- Sinha A. Dupuytren's disease may extend beyond the wrist crease in continuity. *J. Bone Joint Surg. Br.* 79, 211–212 (1997).
- Gholami SS, Gonzalez-Cadavid NF, Lin CS *et al.* Peyronie's disease: a review. *J. Urol.* 169, 1234–1241 (2003).
- Bisson MA, Beckett KS, McGrouther DA *et al.* Transforming growth factor- β 1 stimulation enhances Dupuytren's fibroblast contraction in response to uniaxial mechanical load within a 3-dimensional collagen gel. *J. Hand Surg.* 34, 1102–1110 (2009).
- Swartz WM, Lalonde DH. MOC-PS(SM) CME article: Dupuytren's disease. *Plast. Reconstr. Surg.* 121, 1–10 (2008).
- Hindocha S, McGrouther DA, Bayat A. Epidemiological evaluation of Dupuytren's disease incidence and prevalence rates in relation to etiology. *Hand* 4, 256–269 (2009).
- Urban M, Feldberg L, Janssen A, Elliot D. Dupuytren's disease in children. *J. Hand Surg. Br.* 21, 112–116 (1996).
- Murrell GAC, Hueston JT. Review article: aetiology of Dupuytren's contracture. *ANZ J. Surg.* 60, 247–252 (1990).
- Thurston AJ. Dupuytren's disease. *J. Bone Joint Surg. B* 85, 469–477 (2003).
- Hindocha S, John S, Stanley JK *et al.* The heritability of Dupuytren's disease: familial aggregation and its clinical significance. *J. Hand Surg.* 31, 204–210 (2006).
- Burge P. Genetics of Dupuytren's disease. *Hand Clin.* 15, 63–71 (1999).
- Hu FZ, Nystrom A, Ahmed A *et al.* Mapping of an autosomal dominant gene for Dupuytren's contracture to chromosome 16q in a Swedish family. *Clin. Genet.* 68, 424–429 (2005).
- Hindocha S, Stanley JK, Watson S *et al.* Dupuytren's diathesis revisited: evaluation of prognostic indicators for risk of disease recurrence. *J. Hand Surg.* 31, 1626–1634 (2006).
- Shih B, Bayat A. Scientific understanding and clinical management of Dupuytren disease. *Nat. Rev. Rheumatol.* 6, 715–726 (2010).
- Shih B, Brown JJ, Armstrong DJ *et al.* Differential gene expression analysis of subcutaneous fat, fascia, and skin overlying a Dupuytren's disease nodule in comparison to control tissue. *Hand* 4, 294–301 (2009).
- Dal Cin P, De Smet L, Sciort R *et al.* Trisomy 7 and trisomy 8 in dividing and non-dividing tumor cells in Dupuytren's disease. *Cancer Genet. Cytogenet.* 108, 137–140 (1999).
- Gudmundsson KG, Arngrímsson R, Sigfússon N *et al.* Epidemiology of Dupuytren's disease: clinical, serological, and social assessment. The Reykjavik Study. *J. Clin. Epidemiol.* 53, 291–296 (2000).
- An HS, Southworth SR, Jackson WT *et al.* Cigarette smoking and Dupuytren's contracture of the hand. *J. Hand Surg.* 13, 872–874 (1988).
- Attali P, Ink O, Pelletier G *et al.* Dupuytren's contracture, alcohol consumption, and chronic liver disease. *Arch. Intern. Med.* 147, 1065–1067 (1987).
- Sanderson PL, Morris MA, Stanley JK *et al.* Lipids and Dupuytren's disease. *J. Bone Joint Surg. Br.* 74, 923–927 (1992).
- Hart MG, Hooper G. Clinical associations of Dupuytren's disease. *Postgrad. Med. J.* 81, 425–428 (2005).
- Livingstone JA, Field J. Algodystrophy and its association with Dupuytren's disease. *J. Hand Surg.* 24B, 199–202 (1999).
- Bovenzi M. Hand-arm vibration syndrome and dose-response relation for vibration induced white finger among quarry drillers and stonecarvers. *Occupat. Environ. Med.* 51, 603–611 (1994).
- Descatha A, Jauffret P, Chastang JF *et al.* Should we consider Dupuytren's contracture as work-related? A review and meta-analysis of an old debate. *BMC Musculoskel. Dis.* 12 (2011).
- Al-Qattan MM. Factors in the pathogenesis of Dupuytren's contracture. *J. Hand Surg. Am.* 31, 1527–1534 (2006).
- Murrell GAC, Francis MJO, Bromley L. Free radicals and Dupuytren's contracture. *Br. Med. J.* 295, 1373–1375 (1987).
- Pereira RS, Black CM, Turner SM *et al.* Antibodies to collagen types I-VI in Dupuytren's contracture. *J. Hand Surg.* 11, 58–60 (1986).
- Neumuller J, Menzel J, Millesi H. Prevalence of HLA-DR3 and autoantibodies to connective tissue components in Dupuytren's contracture. *Clin. Immunol. Immunopathol.* 71, 142–148 (1994).
- Brown JJ, Ollier W, Thomson W *et al.* Positive association of HLA-DRB1*15 with Dupuytren's disease in Caucasians. *Tissue Antigens* 72, 166–170 (2008).
- Luck JV. Dupuytren's contracture; a new concept of the pathogenesis correlated with surgical management. *J. Bone Joint Surg. Am.* 41A, 635–664 (1959).
- Tomasek JJ, Gabbiani G, Hinz B *et al.* Myofibroblasts and mechano-regulation of connective tissue remodelling. *Nat. Rev. Mol. Cell Biol.* 3, 349–363 (2002).
- Brickley-Parsons D, Glimcher MJ, Smith RJ. Biochemical changes in the collagen of the palmar fascia in patients with Dupuytren's disease. *J. Bone Joint Surg. A* 63, 787–797 (1981).
- Tubiana R. Evaluation of deformities in Dupuytren's disease. *Ann. Chir. Main.* 5, 5–11 (1986).

- 38 Degreef I, Vererfve PB, De Smet L. Effect of severity of Dupuytren contracture on disability. *Scand. J. Plast. Reconstr. Surg. Hand Surg.* 43, 41–42 (2009).
- 39 Zyluk A, Jagielski W. The effect of the severity of the Dupuytren's contracture on the function of the hand before and after surgery. *J. Hand Surg. Eur.* 32, 326–329 (2007).
- 40 Draviraj KP, Chakrabarti I. Functional outcome after surgery for Dupuytren's contracture: a prospective study. *J. Hand Surg. Am.* 29, 804–808 (2004).
- 41 Hudak PL, Amadio PC, Bombardier C. Development of an upper extremity outcome measure: the DASH (disabilities of the arm, shoulder and hand) [corrected]. The Upper Extremity Collaborative Group (UECG). *Am. J. Ind. Med.* 29, 602–608 (1996).
- 42 Beaton DE, Wright JG, Katz JN. Development of the QuickDASH: comparison of three item-reduction approaches. *J. Bone Joint Surg. Am.* 87, 1038–1046 (2005).
- 43 Chung KC, Pillsbury MS, Walters MR *et al.* Reliability and validity testing of the Michigan Hand Outcomes Questionnaire. *J. Hand Surg. Am.* 23, 575–587 (1998).
- 44 Macey AC, Burke FD, Abbott K *et al.* Outcomes of hand surgery. British Society for Surgery of the Hand. *J. Hand Surg. Br.* 20, 841–855 (1995).
- 45 Becker GW, Davis TR. The outcome of surgical treatments for primary Dupuytren's disease – a systematic review. *J. Hand Surg. Eur.* 35, 623–626 (2010).
- 46 Larson D, Jerosch-Herold C. Clinical effectiveness of post-operative splinting after surgical release of Dupuytren's contracture: a systematic review. *BMC Musculoskel. Dis.* 9, 104 (2008).
- 47 Jerosch-Herold C, Shepstone L, Chojnowski AJ *et al.* Night-time splinting after fasciectomy or dermo-fasciectomy for Dupuytren's contracture: a pragmatic, multi-centre, randomised controlled trial. *BMC Musculoskel. Disord.* 12, 136 (2011).
- 48 Betz N, Ott OJ, Adamietz B *et al.* Radiotherapy in early-stage Dupuytren's contracture. Long-term results after 13 years. *Strahlenther. Onkol.* 186, 82–90 (2010).
- 49 Seegenschmiedt MH, Olschewski T, Guntrum F. Radiotherapy optimization in early-stage Dupuytren's contracture: first results of a randomized clinical study. *Int. J. Radiat. Oncol. Biol. Physics* 49, 785–798 (2001).
- 50 Pohl S, Hinke A, Attassi M *et al.* Prophylactic radiotherapy in Dupuytren's contracture: three years outcome. *Int. J. Radiat. Oncol. Biol. Physics* 54, 23 (2002).
- 51 Fenney R. Dupuytren's contracture a radiotherapeutic approach. *Lancet* 265(6795), 1064–1066 (1953).
- 52 Pittet B, Rubbia-Brandt L, Desmouliere A *et al.* Effect of gamma-interferon on the clinical and biologic evolution of hypertrophic scars and Dupuytren's disease: an open pilot study. *Plast. Reconstr. Surg.* 93, 1224–1235 (1994).
- 53 Vuopala U, Kaipainen WJ. DMOS in the treatment of Dupuytren's contracture. A therapeutic experiment. *Acta Rheumatol. Scand.* 17, 61–62 (1971).
- 54 Kirk JE, Chieffi M. Tocopherol administration to patients with Dupuytren's contracture; effect on plasma tocopherol levels and degree of contracture. *Proc. Soc. Exp. Biol. Med.* 80, 565–568 (1952).
- 55 Duperrat B, Colliard H. [Hypertrophic aponeurosis, peculiar variation of Dupuytren's disease? Excellent therapeutic result with a cytostatic agent (methylhydrazine)]. *Bull. Soc. Fr. Dermatol. Syphiligr.* 76, 14–15 (1969).
- 56 Murrell GAC, Pilowsky E, Murrell TGC. A hypothesis for the resolution of Dupuytren's contracture with allopurinol. *Specul. Sci. Technol.* 10, 107–112 (1987).
- 57 Stiles PJ. Ultrasonic therapy in Dupuytren's contracture. *J. Bone Joint Surg. B* 48, 452–454 (1966).
- 58 Engstrand C, Boren L, Liedberg GM. Evaluation of activity limitation and digital extension in Dupuytren's contracture three months after fasciectomy and hand therapy interventions. *J. Hand Ther.* 22, 21–27 (2009).
- 59 Rayan GM. Nonoperative treatment of Dupuytren's disease. *J. Hand Surg.* 33, 1208–1210 (2008).
- 60 Ketchum LD, Donahue TK. The injection of nodules of Dupuytren's disease with triamcinolone acetonide. *J. Hand Surg.* 25, 1157–1162 (2000).
- 61 Al-Qattan MM, Ketchum LD. The injection of nodules of Dupuytren's disease with triamcinalone acetonide. *J. Hand Surg.* 26, 560–561 (2001).
- 62 Meek RM, McLellan S, Reilly J *et al.* The effect of steroids on Dupuytren's disease: role of programmed cell death. *J. Hand Surg. Br.* 27, 270–273 (2002).
- 63 Gelbard MK, Walsh R, Kaufman JJ. Collagenase for Peyronie's disease experimental studies. *Urolog. Res.* 10, 135–140 (1982).
- 64 Badalamente MA, Hurst LC, Hentz VR. Collagen as a clinical target: nonoperative treatment of Dupuytren's disease. *J. Hand Surg.* 27, 788–798 (2002).
- 65 Hurst LC, Badalamente MA, Hentz VR *et al.* Injectable collagenase clostridium histolyticum for Dupuytren's contracture. *N. Engl. J. Med.* 361, 968–979 (2009).
- 66 Gilpin D, Coleman S, Hall S *et al.* Injectable collagenase *Clostridium histolyticum*: a new nonsurgical treatment for Dupuytren's disease. *J. Hand Surg. Am.* 35, 2027–2038 e2021 (2010).
- 67 Watt AJ, Curtin CM, Hentz VR. Collagenase injection as nonsurgical treatment of Dupuytren's disease: 8-year follow-up. *J. Hand Surg.* 35 (2010).
- 68 Badalamente MA, Hurst L. Longer term follow up of recurrence after collagenase injection for Dupuytren's contracture. Abstract 18, American Society for diseases of the Hand Annual Meeting 2011.
- 69 Eaton C. Percutaneous fasciotomy for Dupuytren's contracture. *J. Hand Surg. Am.* 36, 910–915 (2011).
- 70 Beaudreuil J, Lermusiaux JL, Teyssedou JP *et al.* Multi-needle aponeurotomy for advanced Dupuytren's disease: preliminary results of safety and efficacy (MNA 1 Study). *Joint Bone Spine* 78, 625–628 (2011).
- 71 van Rijssen AL, Gerbrandy FSJ, Linden HT *et al.* A Comparison of the direct outcomes of percutaneous needle fasciotomy and limited fasciectomy for Dupuytren's disease: a 6-week follow-up study. *J. Hand Surg.* 31, 717–725 (2006).
- 72 Foucher G, Lallemand S, Pajardi G. [What's new in the treatment of Dupuytren's contracture?] *Ann. Chir. Plast. Esthet.* 43, 593–599 (1998).
- 73 Badois FJ, Lermusiaux JL, Masse C *et al.* Non-surgical treatment of Dupuytren disease using needle fasciotomy. *Rev. Rhum. Ed. Fr.* 60, 808–813 (1993).
- 74 Rahr L, Sondergaard P, Bisgaard T *et al.* Percutaneous needle fasciotomy for primary Dupuytren's contracture. *J. Hand Surg. Eur.* 36, 548–552 (2011).
- 75 Rowley DI, Couch M, Chesney RB *et al.* Assessment of percutaneous fasciotomy in the management of Dupuytren's contracture. *Br. J. Oral Maxillofacial Surg.* 9, 163–164 (1984).
- 76 van Rijssen AL, Werker PM. Percutaneous needle fasciotomy in Dupuytren's disease. *J. Hand Surg. Br.* 31, 498–501 (2006).
- 77 Foucher G, Medina J, Navarro R. Percutaneous needle aponeurotomy: complications and results. *J. Hand Surg.* 28B, 427–431 (2003).
- 78 Bryan AS, Ghorbal MS. The long-term results of closed palmar fasciotomy in the management of Dupuytren's contracture. *J. Hand Surg. Br.* 13, 254–256 (1988).
- 79 Hovius SE, Kan HJ, Smit X *et al.* Extensive percutaneous aponeurotomy and

- lipografting: a new treatment for Dupuytren disease. *Plast. Reconstr. Surg.* 128, 221–228 (2011).
- 80 Moermans JP. Long-term results after segmental aponeurectomy for Dupuytren's disease. *J. Hand Surg.* 21B, 797–800 (1996).
 - 81 Donaldson OW, Pearson D, Reynolds R *et al.* The association between intraoperative correction of Dupuytren's disease and residual postoperative contracture. *J. Hand Surg. Eur.* 35, 220–223 (2010).
 - 82 Shaw RB Jr, Chong AK, Zhang A *et al.* Dupuytren's disease: history, diagnosis, and treatment. *Plast. Reconstr. Surg.* 120, e44–e54 (2007).
 - 83 Hueston JT. Dermofasciectomy for Dupuytren's disease. *Bull. Hosp. Jt Dis. Orthop. Inst.* 44, 224–232 (1984).
 - 84 Tonkin MA, Burke FD, Varian JPW. Dupuytren's contracture: a comparative study of fasciectomy and dermofasciectomy in one hundred patients. *J. Hand Surg. Eur.* 9, 156 (1984).
 - 85 Armstrong JR, Hurren JS, Logan AM. Dermofasciectomy in the management of Dupuytren's disease. *J. Bone Joint Surg. B* 82, 90–94 (2000).
 - 86 Brotherston TM, Balakrishnan C, Milner RH *et al.* Long term follow-up of dermofasciectomy for Dupuytren's contracture. *Br. J. Plast. Surg.* 47, 440–443 (1994).
 - 87 McCash CR. The open palm technique in Dupuytren's contracture. *Br. J. Plast. Surg.* 17, 271–280 (1964).
 - 88 McGregor IA. The Z-plasty in hand surgery. *J. Bone Joint Surg. Br.* 49, 448–457 (1967).
 - 89 Bruner JM. The zig-zag volar-digital incision for flexor-tendon surgery. *Plast. Reconstr. Surg.* 40, 571–574 (1967).
 - 90 Edmunds I, Chien C. A new surgical approach to Dupuytren's disease. *J. Hand Surg. Eur.* 36, 485–489 (2011).
 - 91 Tripoli M, Merle M. The 'Jacobsen Flap' for the treatment of stages III-IV Dupuytren's disease: a review of 98 cases. *J. Hand Surg. Eur.* 33, 779–782 (2008).
 - 92 Citron ND, Nunez V. Recurrence after surgery for Dupuytren's disease: a randomized trial of two skin incisions. *J. Hand Surg. Br.* 30, 563–566 (2005).
 - 93 Ullah AS, Dias JJ, Bhowal B. Does a 'firebreak' full-thickness skin graft prevent recurrence after surgery for Dupuytren's contracture?: a prospective, randomised trial. *J. Bone Joint Surg. Br.* 91, 374–378 (2009).
 - 94 Citron N, Hearnden A. Skin tension in the aetiology of Dupuytren's disease; a prospective trial. *J. Hand Surg. Br.* 28, 528–530 (2003).
 - 95 Coert JH, Nerin JPB, Meek MF. Results of partial fasciectomy for Dupuytren disease in 261 consecutive patients. *Ann. Plast. Surg.* 57, 13–17 (2006).
 - 96 Foucher G, Cornil C, Lenoble E *et al.* A modified open palm technique for Dupuytren's disease. Short and long term results in 54 patients. *Int. Orthop.* 19, 285–288 (1995).
 - 97 Bulstrode NW, Jemec B, Smith PJ. The complications of Dupuytren's contracture surgery. *J. Hand Surg.* 30, 1021–1025 (2005).
 - 98 Denkler K. Surgical complications associated with fasciectomy for Dupuytren's disease: a 20-year review of the English literature. *Eplasty* 10, e15 (2010).
 - 99 Watson HK, Lovullo JL. Salvage of severe recurrent Dupuytren's contracture of the ring and small fingers. *J. Hand Surg. Am.* 12, 287–289 (1987).
 - 100 Ritchie JFS, Venu KM, Pillai K *et al.* Proximal interphalangeal joint release in Dupuytren's of the little finger. *J. Hand Surg.* 29B, 15–17 (2004).
 - 101 White JW, Kang SN, Nancoo T *et al.* Management of severe Dupuytren's contracture of the proximal interphalangeal joint with use of a central slip facilitation device. *J. Hand Surg. Eur.* doi:10.1177/1753193412439673 (2012) (Epub ahead of print).

■ Websites

- 201 NICE. Radiation therapy for early Dupuytren's disease. Interventional procedure guidance 368 (2010). <http://guidance.nice.org.uk/IPG368>
- 202 NICE. Needle fasciotomy for Dupuytren's contracture. Interventional procedure guidance 43 (2004). <http://guidance.nice.org.uk/IPG43>