

# Urachal mucinous cystadenoma, an extremely uncommon urachal amiable tumor-An image article

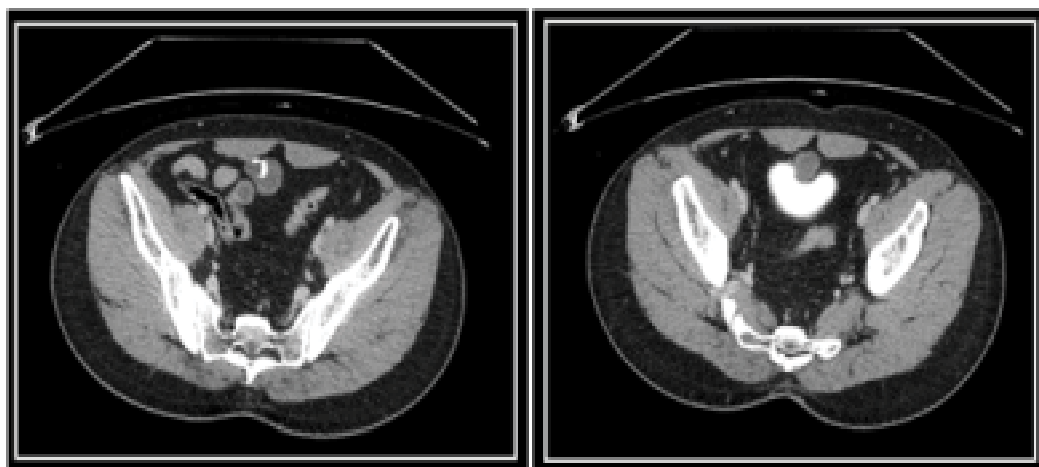
## Description

Mucinous cystadenoma is an uncommon urachal pathology that could be indicative or by chance found while researching for other clinical conditions, on CT and MR imaging, non-upgrading mass with painting calcification was a typical finding in the announced cases [1]. Mucinous cystadenoma is a kind condition that has no harmful change potential as observed in revealed cases, we accept that resection of

the urachal blister with halfway cystectomy if necessary, is the most suitable administration as positive determination by histopathological assessment is required [2]. In any case, care ought to be taken while respecting he mass not to disregard the sore divider as the tumor conduct is obscure now, and Pseudomyxoma peritonei was accounted for after tumor spillage if there should be an occurrence of harmful cystadenocarcinoma

**Elizabeth Swan**

Open Access Publishers, 40 Bloomsbury Way, Lower Ground Floor, United Kingdom



**FIGURE 1. Abdomen and pelvis CT scan with contrast.**

---

**References**

- Lendon AA. A clinical lecture on extroversion of the bladder. *Br Med J.* 1, 961-964 (1906).
- Wang D, Sule N. Mucinous cystadenoma of the urachus and review of current classification of urachal mucinous cystic neoplasms. *Arch Pathol Lab Med.* 143, 258-263 (2019).