

Balloon aortic valvuloplasty: review of the evidence and current indications

Balloon aortic valvuloplasty was introduced over two decades ago as an alternative to aortic valve replacement in elderly patients deemed unsuitable for surgery. Due to high early restenosis rates and no effect on long-term mortality, the procedure's development stalled. However, with recent technological advances, in particular the advent of the transcatheter aortic valve implantation, there has been a resurgence of this technique. The goal of this article is to review the literature and current issues of balloon aortic valvuloplasty.

KEYWORDS: aortic balloon valvuloplasty ■ aortic stenosis ■ BAV

Calcific degenerative aortic valve stenosis (AS) is now the most common acquired valvular disorder in the developed world [1,2]. Once symptomatic it is associated with considerable morbidity and mortality; the mean survival is 3 years after the onset of angina or syncope, and 2 years after the onset of heart failure [3,4]. Furthermore, there is a high risk of sudden cardiac death [5]. There is a clear increase in prevalence with advancing years: one study found a sharp increase in the prevalence of aortic stenosis after the age of 65 years [6]. With the lengthening of life expectancy of our population, the prevalence of this condition is expected to grow.

Pathophysiology

The exact causative mechanisms of AS are still unclear. However, solid calcific particle deposition, which occurs within the valve cusps, leads to leaflet restriction thus causing a functional stenosis of the valve [7]. The decreasing valve area results in progressively greater left ventricular (LV) pressure overload. The pressure overload causes LV remodeling, then hypertrophy (with decreased coronary microvascular blood flow) and ultimately cavity dilatation occurs with failure of contractile performance [8–10]. This can lead to a dilated LV with systolic dysfunction as energy is being used to overcome the resistance of the stenosed valve (the afterload) rather than eject normal blood volumes. Yet, if the stenosis is corrected (i.e., by aortic valve replacement [AVR]) then the LV would be expected to return to normal. Echocardiographic criteria for aortic stenosis severity with normal LV systolic function are shown in TABLE 1.

The difficult condition of 'low-flow' aortic stenosis exists if the gradient is low (i.e., <30 mmHg) with a LV ejection fraction under 40% and aortic valve area (AVA) under 1 cm². Dobutamine stress echo is necessary to determine whether there is genuinely severe AS and whether there is contractile reserve implying a reasonable chance of LV recovery once the stenosis is corrected [11]. There is some evidence that even patients without contractile reserve should undergo AVR as the prognosis is abysmal for severe AS patients who are not operated on [12].

Until recently calcific AS was described by the misnomer 'degenerative' but now a better understanding of the pathophysiology of the disease exists, as it is now understood that an active subendothelial valvular inflammatory process exists, similar to that of atherosclerosis [7,13]. Risk factors for atherosclerosis (e.g., male sex, increasing age and hypercholesterolemia) are common to both disorders [8,14]. Indeed this may explain the high rate of comorbidities in these patients (cardiovascular, cerebrovascular, renovascular and peripheral vascular disease).

Surgical aortic valve replacement

In severe symptomatic AS, surgical AVR provides symptom relief, regression of LV hypertrophy, improved LV function and ultimately a survival benefit [15]. AVR is recommended in all symptomatic AS patients, yet many do not undergo surgery for various reasons [16,17]. These include not being referred by their physician or being turned down by the surgeon due to frailty or comorbidities. In the Euro Heart Survey on valvular heart disease, 31.8% of patients who had severe symptomatic single valve disease did not undergo intervention [2].

Miles W Behan¹,
Imad Nadra¹,
Martyn Thomas¹
& Simon Redwood¹

¹Department of Cardiology, 6th Floor, East Wing, St Thomas' Hospital, Westminster Bridge Road, London SE1 7EH, UK

[†]Author for correspondence:
Tel.: +44 207 188 0955
milesbehan@hotmail.com

future
medicine part of fsg

Table 1. Classification of aortic stenosis severity with normal left ventricular systolic function.

Severity	Aortic velocity (m/s)	Mean gradient (mmHg)	Aortic valve area (cm ²)
Normal	<2.5	–	3.0–4.0
Mild	<3.0	<15	<1.4
Moderate	3.0–4.0	15–40	1.0–1.4
Severe	>4.0	>40	<1.0

Data taken from [11].

The mortality risk from an isolated surgical AVR can be as low as 1% in certain patients, however this can rise to between 10 and 40% for AVR in high-risk patients with comorbidities such as previous bypass, impaired LV function or pulmonary disease [18,19]. The prevalence of associated comorbidities increase in an elderly population: operative mortality and morbidity is higher in older than younger patients [15]. Some elderly patients refuse surgery even when the risks and benefits have been explained. Despite successful AVR, more than 50% of octogenarians and nonagenarian patients are discharged to nursing home facilities for rehabilitation [20]. Therefore, these elderly patients, in whom AVR may not be appropriate, require an intervention that may not increase longevity, but will lead to an improvement in quality of life with a reduction in symptoms, or act as a bridge until clinical improvement allows progression to AVR.

Balloon aortic valvuloplasty

Balloon aortic valvuloplasty (BAV) was originally described over two decades ago as an alternative to surgical AVR in high-risk elderly patients [21]. BAV results in significant and immediate decreases in aortic valve gradient and increases in AVA, with an immediate symptomatic improvement [22,23]. The actual mechanism

of BAV is uncertain but is likely to involve fracturing of calcium deposits to form 'hinge-points' in cusps. Other possible mechanisms include the formation of cleavage planes along collagenized stroma and scattered leaflet microfractures, or separation of fused leaflets [24]. Overall its effect on tight stenosis is to leave a final AVA between 0.7–1.2 cm² [25–29]. This is clearly inferior to the valve area obtained by an AVR prosthesis, which usually provides a valve area over 1.5 cm².

Balloon aortic valvuloplasty may be performed effectively by either an arterial (retrograde) vascular approach or by a transvenous transeptal (anterograde approach). The retrograde approach is the most common approach: a 9–12 F sheath is inserted into the femoral artery, allowing a balloon catheter to be retrogradely passed over a stiff guide wire across the stenosed aortic valve. A 20–24-mm balloon is then inflated to relieve the AS (FIGURES 1–3) [30,31].

The anterograde approach is technically more challenging as it involves a transeptal puncture. From a femoral venous puncture, via a transeptal puncture, the guide wire is passed from the left atrium across the mitral valve, looped in the LV apex and through the aortic valve. A balloon is then advanced over a wire from the femoral vein across the aortic valve, which it then dilates [32,33].

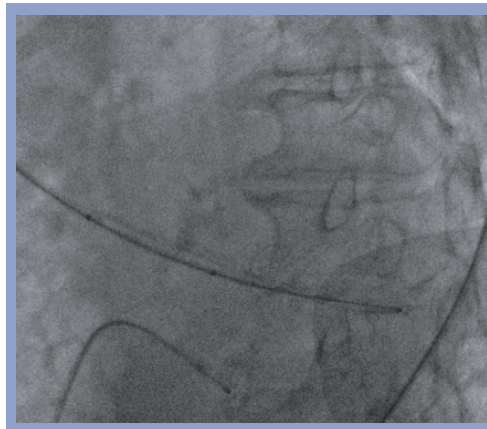

Figure 1. Balloon positioning. Using fluoroscopy the balloon is positioned across the valve. Note the temporary pacing wire and the calcification of the aortic valve.

Studies

There have been no randomized studies comparing BAV with surgical AVR, or indeed medical therapy, and interpretation of the results must take this into account. However, there have been numerous registries and case series: we have summarized a randomly selected group of the major ones over the last two decades in TABLE 2, and discuss a few in detail. In 1991 the National Heart, Lung and Blood Institute (NHLBI) Balloon Valvuloplasty Registry reported 674 patients with severe AS undergoing BAV during a 24-month period [22]. The patients had a mean age of 78 years and were frail: 76% had New York Heart Association (NYHA) class III/IV and 80% had been turned down for AVR by a cardiothoracic surgeon. Following BAV there

were significant decreases in mean and peak aortic gradients (55 ± 21 to 29 ± 13 , and 65 ± 28 to 31 ± 18 mmHg, respectively) and an increase in AVA (0.5 ± 0.2 to 0.8 ± 0.3 cm²). There was a high in-hospital complication rate of 31% (the commonest complication was the need for transfusion as a result of vascular access trauma). The procedural and 30-day mortality rate were 3% and 14%, respectively. Long-term survival was poor: 55% at 1 year, 35% at 2 years and 23% at 3 years. The rate of recurrent hospitalizations was high, and nearly a third of survivors underwent repeat valvuloplasty or subsequent AVR for persistent severe symptomatic AS [34].

Concurrently, another group reported their results from 165 patients and demonstrated that post-BAV long-term event-free (freedom from death, repeat BAV or AVR) and actuarial survival was poor and resembled the actual natural history of untreated AS (actuarial survival of 64, 48 and 37% at 1, 2 and 3 years, respectively post-BAV in comparison with 57, 37 and 25% in untreated elderly patients with symptomatic AS) [25].

The most important predictor of event-free survival was LV ejection fraction at baseline, a finding confirmed in other studies [35]. Other predictors of mortality after BAV include: older age, renal failure and the presence of coronary artery disease [25,29,35].

There are several reasons why BAV has no effect on long-term outcome: first, the patients are frail and in poor condition. Second, there is a high proportion (up to 50%) of concomitant significant coronary disease. Third, the average post-BAV AVA remains 0.7–1.2 cm², meaning the stenosis is still relatively severe. Finally, BAV works to fracture the calcium nodules on the valve and does not have any effect on the underlying process of atherosclerosis and degeneration.

By the mid-1990s, as it had been widely demonstrated that BAV was dogged by high rates of restenosis and complications, and had no effect on long-term outcome, enthusiasm for the procedure waned. Indeed, by 2001, the Euro Heart Survey on Valvular Heart Disease confirmed that BAV had virtually disappeared from practice, without a single BAV procedure carried out during a 4-month period [2].

Resurgence in BAV activity

Over the last 4 years, there has been a worldwide increase in BAV activity. This has been due to both technical advances, that have decreased complications and made the procedure more effective, and the development of transcatheter aortic valve implantation (TAVI).

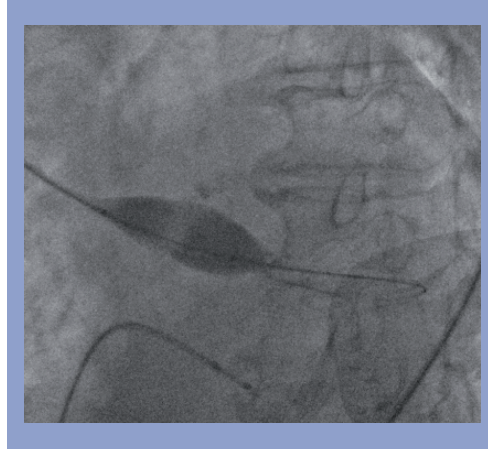


Figure 2. Initial balloon inflation under burst pacing valve. With rapid burst pacing (note right ventricle pacing lead) the balloon is inflated. The indentation of the restricted valve is seen on the balloon.

Severe AS patients are particularly prone to vascular complications: they are often elderly, large caliber sheaths are used, they may have peripheral vascular disease, and they have an acquired coagulopathy (von Willebrand Syndrome type 2A) [36]. In addition, the required postprocedure immobility can be difficult due to orthopnoea, confusion or arthritis. Percutaneous arterial suture closure devices can now be used to close femoral arteriotomies post BAV, achieving rapid hemostasis and shorter bed rest times [37]. Recent trials using these techniques have reported decreased vascular complications: out of 75 BAV patients, using arterial closure devices in 71% of them, vascular bleeding occurred in only 1.3% of patients and urgent vascular surgery was required in only 4% [29].

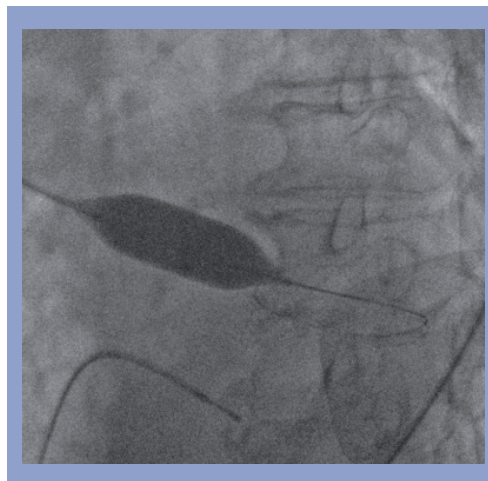

Figure 3. Complete balloon inflation. The balloon is completely inflated with resultant dilatation of the valve.

Table 2. Summary table of selected balloon aortic valvuloplasty series over the last two decades.

Series	NHLBI [22]	Mansfield [23]	Agarwal [26]	Klein [27]	Shareghi [28]	Sack [29]
Recruitment	1987–1989	1986–1987	1994–2002	1989–2005	2000–2006	2005–2007
Number	674	492	212	78	80	75
Mean age	78	79	82	78.4	81	78
Presentation (%)						
New York Heart Association III/IV	76	81	60	90	95	–
Angina	23	31	22	20	25	–
Syncope	34	22	13	22	21	–
Shock	–	–	5	–	20	–
Mean gradient pre/post (mmHg)	55/29	60/30	44/18	50/29	51/23	51/27
Valve area pre/post (cm ²)	0.5/0.8	0.5/0.8	0.61/1.15	0.63/1.01	0.49/0.9	0.84/1.25
Mortality (%)						
Procedural	3	–	1.1	1	–	1.3
In hospital	8	7.5	8	–	6	–
30-day	14	14	10	–	12	–
6-month	–	–	–	–	–	30
1-year	45	36	36	62	44	40
3-year	77	77	72	80	71	–
Complications (%)						
Transfusion	23	11	7.8	–	3	–
Vascular surgery	7	5	2.8	7	1	4
CVA	3	2	0.4	1	1	1.3
Severe AR	–	1	1.1	0	0	0

AR: Aortic regurgitation; CVA: Cerebrovascular accident.
Data taken from [22,23,26–29].

Balloon aortic valvuloplasty performed via the antegrade approach is also associated with less vascular complications as it negates the requirement for a large bore arterial puncture (transvenous instead) [32].

Rapid right ventricular burst pacing (150–220 beats/min) produces a transient reduction in cardiac motion, transvalvular flow, and cardiac output. This allows the precise inflation of a shorter balloon for less duration than was previously possible [38]. BAV has been carried out in 31 high-risk nonagenarian patients with an acceptable complication rate, low perioperative mortality and early improvement in NYHA class. The authors felt that their favorable results in this frail group were due, in part, to using burst pacing and careful femoral arteriotomy site management with manual compression [39].

In addition to burst pacing, improved profile balloons (allowing smaller arteriotomies) have been associated with improved outcomes and lower complications [40].

Coronary disease often coexists with severe AS. Such patients who have coexistent significant coronary disease who are felt not to be suitable for a surgical AVR along with coronary

bypass graft surgery may require both percutaneous coronary intervention (PCI) along with a BAV. Theoretically PCI pre-BAV may prevent critical myocardial ischemia secondary to hypotension during burst pacing and balloon inflation. PCI and BAV can be carried out together safely in a combined procedure in appropriate patients [41].

Transcatheter aortic valve implantation

The main reason for the recent renewed interest in BAV is the development of transcatheter aortic valve implantation technology. This promising therapy is currently being embraced in high-risk patients deemed unsuitable for surgical AVR [42]. The BAV technique is a fundamental part of this procedure, in the predilatation and preparation of the valve in order to receive the prosthesis. Therefore familiarity with BAV is essential. Furthermore, BAV is used for symptom palliation and to improve clinical and hemodynamic condition of patients awaiting TAVI therapy. This has been successfully demonstrated in a study; 43 out of 83 patients awaiting TAVI, were felt to be at high risk of developing TAVI-related periprocedural complications in comparison to

the remaining 40 lower-risk patients. In order to improve the clinical and hemodynamic condition of the 'higher-risk' patients, they underwent BAV prior to the transcatheter valve procedure [43]. BAV was carried out at a mean of 59 days before the TAVI procedures. There were significant improvements in mean pressure gradients, AVAs and NYHA functional status (maintained in 92% of patients till the TAVI procedure). Following the BAV in the 'higher-risk' group, there were no differences in NYHA functional status, echocardiographic or hemodynamic data in comparison to the 'lower-risk' group (who did not undergo BAV). This observation supports the use of BAV to stabilize and improve the clinical and hemodynamic data of patients at 'higher-risk' of TAVI related periprocedural complications.

Balloon aortic valvuloplasty has been used to improve LV function in patients with 'low-flow' aortic stenosis, demonstrating whether a candidate should go on to be treated with TAVI in the hope of long-term LV recovery [44]. In addition it has been shown to improve the safety and efficacy of TAVI therapy when used to size the aortic annulus [45].

Treatment of restenosis

One of the major disadvantages of BAV is the high restenosis rate. The immediate hemodynamic and symptomatic benefits may be short lived as restenosis rates of more than 80% at 1 year are expected. Repeat BAV can be performed safely and with low-risk in symptomatic patients who have developed restenosis maintaining symptomatic improvement. A survival benefit has been proposed from repeat BAV procedures: patients who underwent repeat BAV had higher 3-year survival rates than those who underwent only one BAV [26].

Radiation therapy post-BAV has been suggested as a means of preventing restenosis. It is thought that the radiation halts scar tissue formation and heterotopic ossification on restenosed

aortic valves. A low 1-year restenosis rate of 21% has been described in a pilot study of 20 patients undergoing external beam radiation therapy post-BAV [46].

Current guidelines

The lack of long-term benefit from BAV is reflected in its current accepted indications. The American College of Cardiology/American Heart Association Guidelines on valvular heart disease state that BAV has an important role in the treatment of AS in adolescents and young adults but only a limited role in older adults (TABLE 3) [15]. BAV can have a temporary role for the management of some symptomatic patients who are not initially candidates for AVR (as a 'bridge' to the definitive surgery). They also declare that BAV can reasonably be used as a palliative procedure in patients in whom AVR is not feasible due to serious comorbidity.

They specifically state that BAV should not be recommended as an alternative to AVR. In addition, according to the guidelines, BAV does not have a role in the management of asymptomatic patients with severe AS who require urgent noncardiac surgery.

Our experience

In keeping with other centers, there has been a dramatic increase in our BAV activity recently at our hospital. For the 7-year period (January 2000–December 2007), only six BAV procedures were carried out, whilst for the 2-year period (January 2008–January 2010), over 80 BAV procedures have been performed. The majority of these were as a 'bridge' to TAVI therapy.

Conclusion & future perspective

Balloon aortic valvuloplasty was introduced over two decades ago as an alternative to AVR in elderly patients deemed unsuitable for surgery. It is an effective treatment with early hemodynamic and symptomatic benefits but a significant restenosis rate and no effect on long-term mortality.

Table 3. Current American College of Cardiology/American Heart Association guideline indications for balloon aortic valvotomy.

Level of evidence	Indication	Guideline
Class IIb	1	Aortic balloon valvotomy might be reasonable as a bridge to surgery in hemodynamically unstable adult patients who are at high risk for AVR (level of evidence C)
	2	Aortic balloon valvotomy might be reasonable for palliation in adult patients with AS in whom AVR cannot be performed because of serious comorbid conditions (level of evidence C)
Class III	1	Aortic balloon valvotomy is not recommended as an alternative to AVR in adult patients with AS; certain younger adults without valve calcification might be an exception (level of evidence B)

AS: Aortic valve stenosis; AVR: Aortic valve replacement.
Data taken from [15].

Recent technological advances have improved the procedure and decreased the complication rate. In the future, the procedure's popularity will increase: percutaneous valves require familiarity with the BAV technique as it forms a fundamental part of the TAVI procedure. The major roles of BAV remain as a bridge to AVR (either surgical or percutaneous) and as an important palliative therapy for patients deemed unsuitable for formal valve replacement.

Financial & competing interests disclosure

The authors have no relevant affiliations or financial involvement with any organization or entity with a financial interest in or financial conflict with the subject matter or materials discussed in the manuscript. This includes employment, consultancies, honoraria, stock ownership or options, expert testimony, grants or patents received or pending, or royalties.

No writing assistance was utilized in the production of this manuscript.

Executive summary

Calcific aortic stenosis

- Calcific aortic stenosis (AS) is the most common valvular disorder in the developed world and the prevalence increases in the elderly.
- Once symptomatic, AS is associated with considerable morbidity and mortality.
- Aortic valve replacement (AVR) is recommended in all symptomatic AS patients.
- However, not all AS patients are suitable for AVR owing to comorbidity.

Balloon aortic valvuloplasty

- Balloon aortic valvuloplasty (BAV) was initially described as an alternative to AVR in high-risk elderly patients.
- The procedure results in immediate hemodynamic and symptomatic improvement but is associated with high levels of restenosis.
- Valvuloplasty has been shown to have no long-term effect on survival and to have high complication rates.
- There have been no randomized studies of BAV in comparison with surgical AVR, or indeed medical therapy.

Recent increases in BAV activity

- Technical improvements in the procedure (e.g., burst pacing, arterial suture closure devices, antegrade technique and improved profile balloons) and the development of the transcatheter aortic valve implantation technology.

BAV indications

- BAV is indicated as a 'bridge' to surgical AVR or transcatheter aortic valve implantation (by improving the clinical and hemodynamic condition of patients).
- As a palliative procedure to relieve symptoms in patients deemed unsuitable for formal valve replacement.

Bibliography

Papers of special note have been highlighted as:
▪ of interest

- 1 Carabello BA, Paulus WJ: Aortic stenosis. *Lancet* 373, 956–966 (2009).
- **Excellent overview of aortic stenosis.**
- 2 Iung B, Baron G, Butchart EG *et al.*: A prospective survey of patients with valvular heart disease in Europe: the Euro Heart Survey on Valvular Heart Disease. *Eur. Heart J.* 24, 1231–1243 (2003).
- 3 Ross J Jr, Braunwald E: Aortic stenosis. *Circulation* (Suppl. 1), 61–67 (1968).
- 4 Varadarajan P, Kapoor N, Bansal RC, Pai RG: Clinical profile and natural history of 453 nonsurgically managed patients with severe aortic stenosis. *Ann. Thorac. Surg.* 82, 2111–2115 (2006).
- 5 Otto CM: Aortic stenosis: even mild disease is significant. *Eur. Heart J.* 25, 185–187 (2004).
- 6 Nkomo VT, Gardin JM, Skelton TN *et al.*: Burden of valvular heart diseases: a population based study. *Lancet* 368, 1005–1011 (2006).
- 7 Rajamannan NM: Calcific aortic stenosis: lessons learned from experimental and clinical studies. *Arterioscler. Thromb. Vasc. Biol.* 29, 162–168 (2009).
- 8 Rajappan K, Rimoldi OE, Camici PG *et al.*: Functional changes in coronary microcirculation after valve replacement in patients with aortic stenosis. *Circulation* 107, 3170–3175 (2003).
- 9 Otto CM, Bonow RO: Valvular heart disease. In: *Braunwald's Heart Disease: A Textbook of Cardiovascular Medicine. 8th Edition.* Zipes DP, Libby P, Bobow RW, Braunwald E (Eds), WB Saunders, MO, USA, Chapter 62, 1625–1634 (2007).
- 10 Chambers JB: Aortic stenosis. *Eur. J. Echocardiogr.* 10, 111–119 (2009).
- **Thorough description of echocardiographic assessment of aortic stenosis.**
- 11 Chambers JB: Low 'gradient', low flow aortic stenosis. *Heart* 92, 554–558 (2006).
- 12 Tribouilly C, Levy F, Rusinaru D *et al.*: Outcome after aortic valve replacement for low-flow/low-gradient aortic stenosis without contractile reserve on dobutamine stress echocardiography. *J. Am. Coll. Cardiol.* 53, 1865–1873 (2009).
- 13 Otto CM, Kuusisto J, Reichenbach DD, Gown AM, O'Brien KD: Characterization of the early lesion of 'degenerative' valvular aortic stenosis: histological and immunohistochemical studies. *Circulation* 90, 844–853 (1994).
- 14 Aronow WS, Ahn C, Kronzon I, Goldman ME: Association of coronary risk factors and the use of statins with progression of mild valvular aortic stenosis in older persons. *Am. J. Cardiol.* 88, 693–695 (2001).
- 15 Bonow RO, Carabello BA, Chatterjee K *et al.*: 2008 Focused update incorporated into the ACC/AHA 2006 guidelines for the management of patients with valvular heart disease: a report of the American College of Cardiology/American Heart Association Task Force on Practice Guidelines (writing committee to develop guidelines for the management of patients with valvular heart disease). *J. Am. Coll. Cardiol.* 52, E1–E142 (2008).
- **Current guidelines for the management of valvular heart disease.**
- 16 Iung B, Cachier A, Baron G *et al.*: Decision making in elderly patients with severe aortic stenosis: why are so many denied surgery? *Eur. Heart J.* 26, 2714–2720 (2005).
- 17 Iung B: Management of the elderly patient with aortic stenosis. *Heart* 94, 519–524 (2008).
- 18 Ambler G, Omar RZ, Royston P *et al.*: Generic, simple risk stratification model for heart valve surgery. *Circulation* 112, 224–231 (2005).

- 19 Kapadia SR, Goel SS, Svensson L *et al.*: Characterization and outcome of patients with severe symptomatic aortic stenosis referred for percutaneous aortic valve replacement. *J. Thorac. Cardiovasc. Surg.* 137, 1430–1435 (2009).
- 20 Sharony R, Grossi EA, Saunders PC *et al.*: Minimally invasive aortic valve surgery in the elderly: a case control study. *Circulation* 108, II43–II47 (2003).
- 21 Cribier A, Savin T, Berland T *et al.*: Percutaneous transluminal valvuloplasty in acquired aortic stenosis in elderly patients: an alternative to valve replacement? *Lancet* 1, 63–67 (1986).
- **Original article describing balloon aortic valvuloplasty (BAV).**
- 22 Registry NHLBI: Percutaneous balloon aortic valvuloplasty. Acute and 30-day follow up results in 674 patients from the NHLBI Balloon Valvuloplasty Registry. *Circulation* 84, 2383–2397 (1991).
- **Large registry data for early BAV results.**
- 23 McKay RG: The Mansfield Scientific Aortic Valvuloplasty Registry: overview of acute haemodynamic results and procedural complications. *J. Am. Coll. Cardiol.* 17, 485–491 (1991).
- 24 Hara H, Pederson WR, Ladich E *et al.*: Percutaneous balloon aortic valvuloplasty revisited: time for a renaissance? *Circulation* 115, e334–e338 (2007).
- 25 Lieberman EB, Bashore TM, Hermiller JB *et al.*: Balloon aortic valvuloplasty in adults: failure of procedure to improve long-term survival. *J. Am. Coll. Cardiol.* 26, 1522–1528 (1995).
- 26 Agarwal A, Kini AS, Attani S *et al.*: Results of repeat balloon valvuloplasty for treatment of aortic stenosis in patients aged 59–104 years. *Am. J. Cardiol.* 95, 43–47 (2005).
- 27 Klein A, Lee K, Gera A *et al.*: Long-term mortality, cause of death, and temporal trends in complications after percutaneous aortic balloon valvuloplasty for calcific aortic stenosis. *J. Interv. Cardiol.* 19, 269–275 (2006).
- 28 Shareghi S, Rasouli L, Shavelle DM *et al.*: Current results of balloon aortic valvuloplasty in high-risk patients. *J. Invasive Cardiol.* 19, 1–5 (2007).
- 29 Sack S, Kahlert P, Khandanpour *et al.*: Revival of an old method with new techniques: balloon aortic valvuloplasty of the calcified aortic stenosis in the elderly. *Clin. Res. Cardiol.* 97, 288–297 (2008).
- 30 Jabbour RJ, Dick R, Walton AS: Aortic balloon valvuloplasty – review and case series. *Heart Lung Circ.* 17S, S73–S81 (2008).
- 31 Feldman T: Proceedings of the TCT: Balloon aortic valvuloplasty appropriate for elderly valve patients. *J. Interv. Cardiol.* 19, 276–279 (2006).
- 32 Cubbedu RJ, Jneid J, Don CW *et al.*: Retrograde versus antegrade percutaneous aortic balloon valvuloplasty: immediate, short- and long-term outcomes at 2 years. *Catheter Cardiovasc. Interv.* 74, 225–231 (2009).
- 33 Sakata Y, Syed Z, Saliger MH, Feldman T: Percutaneous balloon aortic valvuloplasty: antegrade transseptal vs. conventional retrograde transarterial approach. *Catheter Cardiovasc. Interv.* 64, 314–321 (2005).
- 34 Otto CM, Mickel MC, Kennedy JW *et al.*: Three-year outcome after balloon aortic valvuloplasty. Insights into prognosis of valvular aortic stenosis. *Circulation* 89, 642–650 (1994).
- 35 Kuntz RE, Tosteson AN, Berman AD *et al.*: Predictors of event free survival after balloon aortic valvuloplasty. *N. Engl. J. Med.* 325, 17–23 (1991).
- 36 Massyn MW, Khan SA: Heyde syndrome: a common diagnosis in older patients with severe aortic stenosis. *Age Ageing* 38, 267–270 (2009).
- 37 Solomon LW, Fusman B, Jolly N *et al.*: Percutaneous suture closure for management of large French size arterial puncture in aortic valvuloplasty. *J. Invasive Cardiol.* 13, 592–596 (2001).
- 38 Witzke C, Don CW, Cubeddu RJ *et al.*: Impact of rapid ventricular pacing during percutaneous balloon aortic valvuloplasty in patients with critical aortic stenosis: should we be using it? *Catheter Cardiovasc. Interv.* 75, 444–452 (2010).
- 39 Pederson WR, Klaassen PJ, Boisjolie CR *et al.*: Feasibility of transcatheter intervention for severe aortic stenosis in patients ≥90 years of age: aortic valvuloplasty revisited. *Catheter Cardiovasc. Interv.* 70, 149–154 (2007).
- 40 Yamen E, Daniels DV, HoHai V *et al.*: Use of a low-profile, compliant balloon for percutaneous aortic valvuloplasty. *Catheter Cardiovasc. Interv.* 75, 794–798 (2010).
- 41 Pederson WR, Klaassen PJ, Pedersen CW *et al.*: Comparison of outcomes in high-risk patients >70 years of age with aortic valvuloplasty and percutaneous coronary intervention versus aortic valvuloplasty alone. *Am. J. Cardiol.* 101, 1309–1314 (2008).
- 42 Thomas M, Schymik G, Walther T *et al.*: Thirty day results of the SAPIEN Aortic Bioprosthesis European Outcome (SOURCE) Registry. A European registry of transcatheter aortic valve implantation using the Edwards SAPIEN valve. *Circulation* 122, 62–69 (2010).
- 43 Ussia GP, Capodanno D, Barbanti M *et al.*: Balloon aortic valvuloplasty for severe aortic stenosis as a bridge to high-risk transcatheter aortic valve implantation. *J. Invasive Cardiol.* 22, 161–166 (2010).
- **Paper highlighting new BAV role as a bridge to transcatheter aortic valve implantation.**
- 44 Block PC: Much ado, but not what to do. *J. Invasive Cardiol.* 22, 167 (2010).
- 45 Babaliaros VC, Junagadhwala Z, Lerakis S *et al.*: Use of balloon aortic valvuloplasty to size the aortic annulus before implantation of a balloon-expandable transcatheter heart valve. *J. Am. Coll. Cardiol. Interv.* 3, 114–118 (2010).
- 46 Pederson WR, Van Tassel RA, Pierce TA *et al.*: Radiation following percutaneous balloon aortic valvuloplasty to prevent restenosis (RADAR Pilot Trial). *Catheter Cardiovasc. Interv.* 68, 183–192 (2006).