

Anterograde techniques for percutaneous revascularization of chronic total coronary occlusions

Percutaneous coronary intervention for chronic total occlusions remains one of the major challenges in interventional cardiology. To improve results in term of angiographic success from the historically quoted rates of 50–60% to the levels now routinely quoted by expert operators, skill, experience and also a complete knowledge of the wide array of techniques and tools armamentarium available are needed. The anterograde approach is the most frequent technique chosen in percutaneous coronary intervention chronic total occlusions, but it requires a great understanding of the different guidewires and specific materials available that is separate from the understanding of the type of lesion being faced. In this article, we sought to list and describe the anterograde techniques available to perform chronic total occlusion percutaneous coronary intervention and also to deal with the most common procedural complications. A complete understanding of all techniques is needed for the operators to choose the most appropriate technique in relation to the lesion characteristics, and enables the operator to switch during the procedure from one technique to another in case of technical failure.

KEYWORDS: anterograde technique • chronic total occlusion • percutaneous coronary intervention

Percutaneous coronary intervention (PCI) for chronic total occlusions (CTOs) remains one of the major challenges in interventional cardiology. Successful recanalization of a CTO can reduce anginal symptoms, reduce the need for coronary artery bypass surgery and increase long-term survival [1–3]. Approximately 30–40% of patients with coronary artery disease are shown at angiography to have at least one occluded artery, but only 7–15% of CTO are treated percutaneously [4,5]. This fact might be explained by the low rate of angiographic success obtained for these lesions in comparison with nonoccluded lesions. Although the most important factor for procedural failure is the inability to cross the occlusion with the guidewire, other factors may prevent balloon crossing and final recanalization [6,7]. Improving results from the historically quoted success rates of 50–60% to the levels now routinely quoted by experienced operators (80–90%) requires not just skill and training, but also a complete knowledge of the wide array of techniques. The anterograde approach is chosen in the vast majority of PCI CTOs but it requires a great understanding of the different guidewire characteristics and specific materials available. The operator should always keep in mind that when advancing the guidewire, it is recommended to monitor the wire's progress, mentally tracing where the wire is supposed to follow from the proximal cap to

the distal lumen through the entire length of the occlusion, selecting different orthogonal views during the procedure.

Single wire technique

When microchannels are clearly visible it is advisable to use a soft plastic guidewire. These wires are generally used to make a small 45° bend at 1 mm from the tip of the wire in order to go through the microchannel. However, if the vessel is tortuous and calcified, when using plastic wires such as Fielder™ FC or XT (Asahi Intecc Co., Japan), a secondary 15–20° curve at 3–4 mm proximal to the distal tip may be performed in addition. In order to prevent the rupture of a microchannel soft plastic wire, manipulation should be as gentle as possible. When a CTO is characterized by microchannels and tortuous calcified vessels, the operator may wonder whether to use soft or stiff plastic wires and may choose to use more aggressive plastic wires such as Pilot™ 50 or 150 (Abbott Vascular, IL, USA), or even choose a subintimal tracking and re-entry (STAR) technique [8] or microchannel technique (see later) [9]. In such conditions, the distal lumen may be reached by these techniques due to tortuosity of the vessel and the presence of calcifications that may prevent parallel wires from working effectively, with both soft plastic and stiff spring wires, by lengthening the procedure quite substantially.

Alfredo R Galassi¹,
Salvatore D Tomasello¹,
Luca Costanzo¹
& Corrado Tamburino¹

¹Department of Internal Medicine & Systemic Disease, Clinical Division of Cardiology, Ferrarotto Hospital, University of Catania, Italy
¹Author for correspondence:
Via Antonello da Messina 75,
Acicastello, 95021 Catania, Italy
Tel.: +39 095 7436 210
Fax: +39 095 362 429
argalassi@virgilio.it

future
medicine part of fsg

In CTO without the microchannels, floppy wires are very unlikely to cross the lesion. However, a stiff wire may not be the right choice when the vessel is tortuous in the proximal section, owing to the risk of damaging the arterial wall. In such situations, a floppy wire appears to be the best choice to position an over-the-wire (OTW) catheter until CTO entry point, without injuring the intact proximal arterial wall. At this stage, the floppy wire can be exchanged with a dedicated stiffer one. The optimal tip shape for a stiff wire for most lesions is an obtuse angle; a distal 40–50° bend at 1–2 mm from the tip of the wire and a secondary 15–20° curve 3–5 mm proximal to the distal curve of the wire is generally given. In this case, the secondary curve may also be hidden after the microcatheter advancement, but meticulous attention should be paid not to advance the wire by straightening it so as to avoid coronary perforation. Stiff wires can be manipulated according to two different techniques: the drilling and the penetrating techniques.

The drilling technique consists of pushing movements associated with clockwise and counter-clockwise oscillations. This is usually accomplished by the set of Miracle series (Asahi Intecc Co.). It is possible to start with Miracle 3 gr or directly choose a 4.5 or 6 gr. A stepwise guidewire to increasing stiffness is suggested if the wire is not able to penetrate the proximal or distal cap.

The penetrating technique is the strategy used when encountering very fibrocalcific, old CTO, especially if no stump is seen. In this situation, it is best to use the stiff tapered tip guidewire types, such as Conquest (Asahi Intecc Co.) although some Japanese operators consider that Miracle 6 gr may be alternatively used when a small stump is seen. However, we need to keep in mind that the penetrating technique has been designed for tapered guidewires, especially if they are hydrophilic, such as the Conquest Pro (Asahi Intecc Co.) [10]. Indeed, this wire has an effective hydrophilic coating on the spring coil shaft, but not on the ball tip, which facilitates capturing the small dimple at the entry point and helps to prevent the guidewire tip from slipping into the subintimal space. Unlike the drilling technique, when using the penetrating strategy, directional control of the guidewire is more precise with very small movements while pushing in the direction of the lumen through the occlusion.

This stiff, tapered guidewire has a greater ability to penetrate through the dense connective tissues into the distal true lumen. Moreover, as the wire stiffness increases, the risk of creating

a large dissection and advancing the wire into a subintimal channel, or even perforating the vessel, is higher. Careful monitoring of the wire's advancement should be carried out by using at least two orthogonal projections with a good distal lumen visualization using a careful injection from the same guiding catheter or from the contralateral one [11].

On the basis of the presence of 160–230 µm microchannels in the majority of CTO, the introduction of the new soft hydrophilic tapered guidewire, such as Fielder XT (Asahi Intecc Co.), or 0.010" soft hydrophilic guidewires has improved the rate of procedural success, reducing the time of procedure and fluoroscopy (see later) [12].

After reaching the distal true lumen, a good lesion predilatation is essential. Generally, using low crossing profile OTW balloons allows a high likelihood of lesion crossing. Moreover, it is recommended that the operator starts with a smaller diameter balloon (1–1.25 mm) and continues the dilations, gradually increasing the diameter to approximately 0.5–0.75 mm. TABLE 1 shows a selection of the small OTW balloons available on the market along with their characteristics.

Parallel wire technique

The parallel wire technique is employed in the majority of cases with a high success rate [11,13]. When the operator senses and observes that the wire is in subintimal space, they could leave the first wire in place and start proceeding with the parallel wire technique, inserting another wire. The second wire should follow an appropriate course according to the lessons learned from the first wire failure. When a parallel approach is required, it is generally better to use a larger guiding catheter (7 or 8 Fr) so that any kind of wiring techniques can be used, besides gaining enhanced backup support. When the first wire is left in place, it keeps the dissection channel closed and serves as a marker for the advancing second wire, which may easily identify a different pathway (FIGURE 1). The second wire may be either the same or different to the previous wire. It is also worth noting that the guidewire tip curve shape might be wider to better fit into the dissection. The idea of the parallel wire technique also includes saving multiple anterograde contrast injections since the first wire serves as a marker. To be sure that one of the two wires is distally in the true lumen, it is recommended that contrast is injected through either the guiding catheter or contralaterally. Different angiographic views are mandatory in order to check the position and to make sure that the wire is

Table 1. Over-the-wire balloons up to 1.5 mm in diameter size.

Manufacturer	Balloon	Shaft length & diameter	Balloon size (diameter × length)	Entry tip profile	Balloon crossing profile
Abbott	Voyager	135 cm, 2.7–3.3 Fr	1.5 × 12–15 mm	0.017"	0.023"
Boston	Apex	140 cm, 2.3–2.4 Fr	1.5 × 8–12–15–20 mm	0.017"	0.023"
Clearstream	Ezecto	140 cm	1.25–1.5 × 15 mm	0.017"	0.022"
CID Acrostak	Across CTO	150 cm, 2.5–2.8 Fr	1.1–1.5 × 10–15–20 mm	0.015"	0.021"
Invatec	Falcon Piccolo	145 cm, 2.2–2.7 Fr	1.25 × 10–15–20 mm	0.0168"	0.022"
	Falcon CTO	145 or 160 cm, 2.2–2.7 Fr	1.0–1.25–1.5 × 10–14–20 mm	0.016"	0.021"
	Falcon Bravo	145 cm, 2.5–3.0 Fr	1.5 × 10–14–20 mm	0.016"	0.023"
Medtronic	Sprinter	138 cm, 2.5–2.7 Fr	1.5 × 6–12–15–20 mm	0.017"	0.021"
SIS Medical AG	NIC nano	160 cm	0.85 × 10–15 mm	0.017"	0.0195"
	NIC 1.1 OTW	160 cm	1.1 × 10–12–15–17–20 mm	0.017"	0.0205"
Terumo	Rujin OTW	135 or 148 cm, 2.5–2.7 Fr	1.25–1.5 × 10–15–20 mm	0.0165"	0.023"

CTO: Chronic total occlusion; OTW: Over-the-wire.

in the true lumen. If the second wire follows the previous subintimal track or a different one, a third wire may be inserted in a 7-Fr guiding catheter, keeping in mind that three OTW support catheters cannot be accommodated into it. Generally, the third wire follows the previous two easily in the first part of the coronary artery, even without a microcatheter. Owing to the risk of dissecting the coronary artery before the occluded segment, one should pay attention. Indeed with experience, the operator will learn not to inject contrast, but actually measure the wire progression into the vessel by wire handling feeling. Furthermore, it is not generally recommended to inject contrast into the microcatheter owing to the high risk of enlarging the false lumen and the possible consequence of compressing the true lumen. However, this controversial recommendation may not be followed if the operator considers applying ‘the microchannel technique’ recently described by Carlino *et al.* [9]. Following up this kind of approach, the contrast should be injected by OTW catheter immediately after the proximal fibrous CTO cap, identifying and enlarging the intraocclusion microvessel, providing a pathway for the guidewire crossing the CTO. In doing this, the contrast delineates a roadmap of the occlusion as well as a new passage across the occlusion that could be crossed by using a floppy wire.

See-saw technique

When a parallel wire technique is performed using two full sets of OTW microcatheters with a guidewire inside each, an alternative parallel wire technique termed the ‘see-saw technique’ could be adopted. Basically, when the second wire also slips into the subintimal space it is used

as a new indicator. The first wire changes its role to penetrate the true lumen while utilizing the second wire as a marker, and their roles could also be alternated.

Compared with the basic parallel wire technique, this technique has a high risk of enlarging the subintimal space with further compression of the true lumen. Therefore, this technique should not be recommended routinely and more careful handling is mandatory.

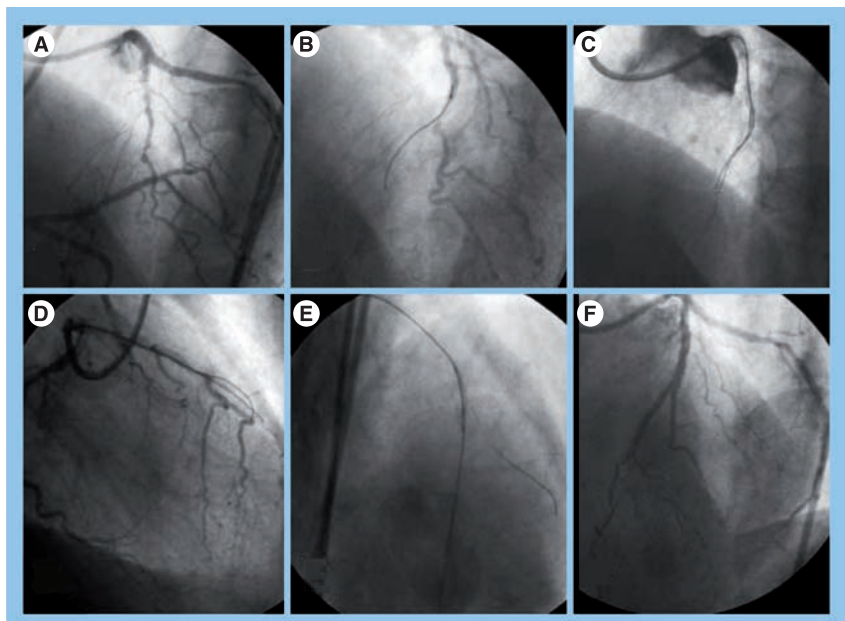


Figure 1. Parallel wire technique. (A) Chronic total occlusion of left anterior descending artery. **(B)** Engagement of lesion with Intermediate guidewire and Echelon microcatheter (guide in a false lumen). **(C)** Parallel wire technique with Conquest PRO 9, Intermediate and two Echelon microcatheters. **(D)** A different projection shows one guide in the false lumen and the other one in the true lumen. **(E)** The true distal lumen was reached with Conquest PRO 9 and a subsequent dilatation was performed with balloon. **(F)** Final result after drug-eluting stent implantation.

Side-branch technique & the open sesame technique

This technique is generally applied when a side branch arises to the occlusion level of the main branch. If the operator chooses this approach, he may introduce the first guidewire into the side branch and then a balloon is inflated at the corresponding origin of the occlusion in the main branch. After the inflation of the balloon, generally a soft plastic guidewire is generally able to reach the distal true lumen. Using a small balloon may be successful, although there is always a risk of dissection by balloon dilatation leading to procedure failure (FIGURE 2).

Alternatively, in the presence of a proximal side branch the guidewire may slip easily into the side branch in front of the hard plaque of occlusion. In these cases, the insertion of stiff guidewires and/or balloon inflation in the side branch may induce a geometrical shift of the hard plaque. This, in turn, enables the entry of a guidewire into the CTO lesion. This procedure has been termed the 'open sesame' technique [14].

Subintimal tracking & re-entry technique

When performing CTO recanalization, the guidewire crossing the occlusion may create a subintimal passage. This should be as short as possible. However, in particular, when the subintimal tracking reaches a remote site from the occlusion and there is clear evidence that dissection might extend distally, the operator could use the STAR technique. This uses a dissection plane as a route to gain distal vessel course [8]. This technique was originally developed by Bolia *et al.* in peripheral vessels [15]. The initial expectation was that a subintimal wire passage throughout the occlusion segment could offer better results after percutaneous transluminal angioplasty than could long stents, as they are prone to restenosis and thrombosis, or intraluminal percutaneous transluminal angioplasty limited by severe recoil and incomplete expansion [16,17]. The grounds for this approach

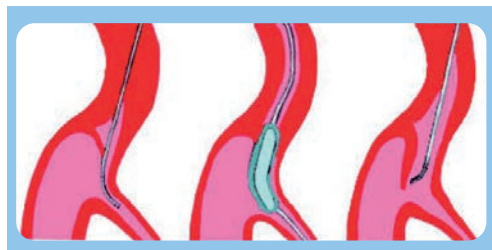

Figure 2. The side-branch technique.

come from surgeon observations when performing endoarterectomy. Indeed, in the case of an occluded lumen, the blood supply to the vessel wall decreases, creating a vulnerable zone at the media level prone to dissection. However, with this approach the atheroma remains *in situ* and a new channel is created around this core, which is theoretically free from endothelium and atheroma.

To perform the STAR technique, after a subintimal dissection creation by using a stiff wire such as Intermediate (Asahi Intecc Co.), Miracle or Conquest, a microcatheter or a OTW balloon is advanced in such a track and the stiff spring wire is exchanged with hydrophilic ones such as Whisper™ (Abbott Vascular) or Pilot 50 or 150. A pronounced J-tip shape 'umbrella handle' must be made at the tip of the hydrophilic wire, in order to prevent trauma when advancing inside the vessel and avoid coronary perforation. At this stage the operator needs to push very hard. This is why he needs to get a good backup from the guiding catheter system. The loops turn around the occluded lumen in a spiral fashion, with a characteristic 'wide loop' configuration guided by the softest areas in the subintimal space. Finally, it is distally advanced into the true lumen (FIGURE 3). Usually, re-entry occurs at a distal level and often at a bifurcation site, where the wire goes into one of the two side branches. The reason for this is that the intima in nondiseased segment is thinner, therefore there is lower resistance towards the true lumen than towards the adventitia. Generally, re-entry into the true lumen is almost an automatic phenomenon. Advancing the wire is not dangerous with such wires because they generally keep their 'distal small loop formation'. The operator may use a stiff hydrophilic wire such as a Pilot 150–200 (Abbott Vascular) instead or a softer one such as Whisper and Pilot 50 when progressing more distally. The perforation risk, although very small, should always be taken into account, especially in the presence of hard and calcified occlusion where pushing is necessary to perform this technique. Having good visualization from contralateral collaterals is important for this maneuver, but sometimes it is not clearly shown whether the wire has gained access to the true lumen due to competitive flow and dissections.

As a general rule, the operator should try to re-enter in as proximal a position as possible in order to obtain the patency of the distal branches. Therefore, an extremely distal re-entry into the true lumen should be avoided.

Microchannel technique

As already mentioned, intra-occlusion microvessels may provide a pathway for a guidewire to cross the CTO. Strauss and colleagues histologically identified the presence of intraluminal microvessels of 100–500 μm in size that run within the occlusion parallel to the major axis of the vessel. These microchannels must be differentiated from vasa vasorum, which are a network of microvessels in the adventitia and outer media running in a radial direction [18]. However, severe calcification, longer occlusions and an unfavorable angle of take-off of the occlusion may limit the value of soft hydrophilic plastic wires, decreasing their success to cross. Carlino and colleagues have recently postulated that using small contrast injections immediately after the proximal fibrous CTO cap, it is possible to identify and potentially dilate these channels facilitating wire crossing [19]. In doing this, the contrast not only delineates a roadmap of the occlusion but also provides a new passage across the occlusion that could be crossed by a conventional floppy wire, such as BMW Universal (Abbott Vascular), or plastic soft hydrophilic wires such as Whisper, Fielder FC and Fielder XT. In the series reported by Carlino *et al.*, despite a lower success rate (63%), the remaining 22% of recanalizations were obtained using other techniques. No complications were observed [19].

Intravascular ultrasound guidance

Intravascular ultrasound (IVUS) is a complementary technique to angiography that is able to provide additional diagnostic information, although this procedure has a limited risk of complications [20].

■ Identification of coronary plaque & re-entry from the subintimal space

The formation of a false channel owing to a subintimal wire position is a frequent phenomenon, even when using the parallel wire technique. This may lead to abandoning of the procedure when the true lumen cannot be found by attempting to reposition the wire. IVUS has the potential to identify the true and false lumen in coronary dissection [21]. Owing to its ability to identify luminal borders, dissection flaps and its own bright guidewire artifact, this imaging technique is well suited to detect the consequences of aberrant wire placement during CTO angioplasty. The operator might redirect another wire either from an antero-grad approach or from a retrograde approach

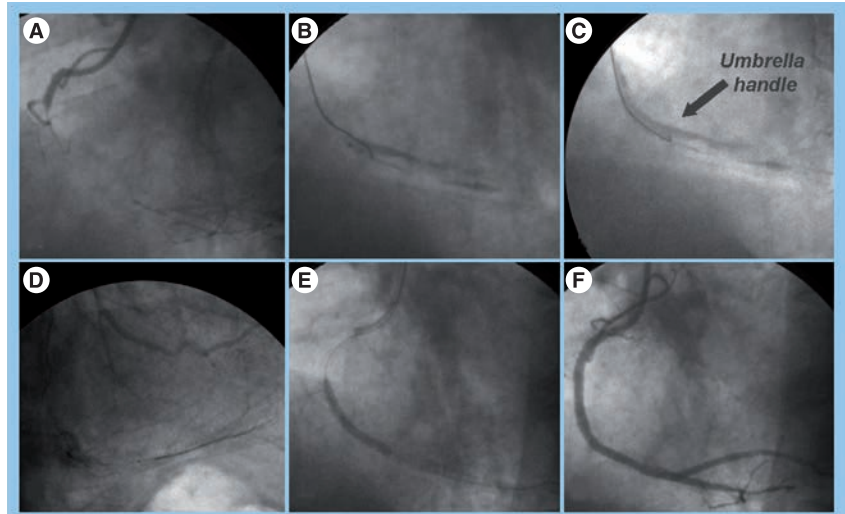


Figure 3. Subintimal tracking and re-entry technique. (A) Proximal chronic total occlusion of the right coronary artery. (B) Dissection owing to guidewire advancement. (C) Pilot 150 guidewire modified with umbrella handle at the tip to execute the subintimal tracking and re-entry (STAR) technique. (D) After executing STAR and exchanging of a softer guidewire (Prowater flex) into the microcatheter. (E) Multiple stent implantations. (F) Final result after drug-eluting stent implantation.

into the true channel using IVUS guidance. Indeed, IVUS is able to show the right pathway and the re-entry point from the subintimal space into the true lumen. However, this technique should definitely be considered the last bail-out procedure, as some drawbacks should be considered; predilatation with a small balloon is essential in advancing the IVUS catheter and may enlarge the dissection even further, long dissection may extend up to a bifurcation causing occlusion of side branch, there might be some risk of perforation and multiple stenting is necessary to fully cover the dissected plane.

■ Identification of the entry site

Some angiographic features have predicted PCI CTO failure, including a blunt stump, with a side branch at the occlusion site. In these cases, the operator has no knowledge of the proper CTO entry point site. IVUS may be an important tool to detect the correct entry point, if at a CTO proximal cap there is a side branch big enough to insert an IVUS catheter. Moreover, it is possible to evaluate the wire position with IVUS, making it easier to choose the best position for the guidewire tip (FIGURE 4).

Anchor balloon technique

The anchor balloon technique might be used to enhance the backup support [22,23]. During CTO procedures the operator may realize that guiding catheter backup is poor and the

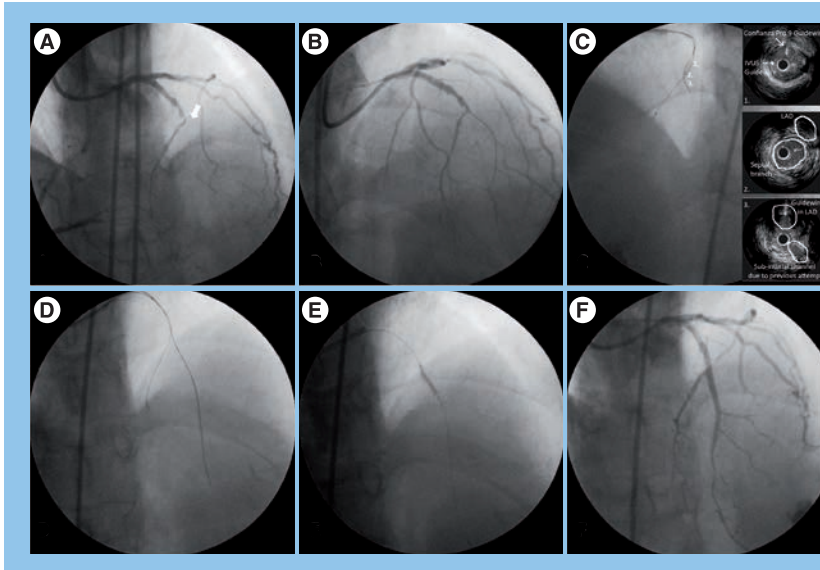


Figure 4. Intravascular ultrasound to detect the correct entry site for the guidewire tip. (A) Left anterior descending chronic total occlusion (CTO) with blunt stump (arrow) and side branch at the proximal cap. (B) Anterograde approach using a stiff guidewire (Confianza Pro 9) into a low profile over-the-wire balloon (Falcon 1.0 × 10 mm) was performed; however, the guidewire penetrated in a false lumen. (C) An intravascular ultrasound (IVUS) probe was advanced into the septal branch in order to orientate the anterograde guidewire through the CTO entry site; the IVUS frames show the correct entry site of CTO (middle panel), the position of IVUS-guided wire and the previous guidewire induced dissection (bottom panel). (D) The stiff anterograde guidewire reached the distal true lumen and dilatations with low profile over-the-wire balloon (Falcon 1.0 × 10 mm) was performed. (E) Multiple dilatations with bigger balloons were then started. (F) The final result after two drug-eluting stent implantations.

catheter tip is moving away from the coronary artery ostium while trying to advance guidewires or a balloon. At any time during the procedure the operator can decide to apply the anchor side-branch balloon technique. When employing the anchor side-branch balloon technique, a lumen guiding catheter larger than at least 6 Fr is generally required. A floppy wire is inserted into a proximal side branch where a small-sized balloon 1.5 mm in diameter is generally advanced and inflated to 4–8 atm. As the entire system becomes stable, an extremely strong support can be gained, making it easy to achieve balloon and wire maneuvers in the main branch.

The anchor balloon technique advantages are as follows: providing the guiding catheter with coaxial placement in the coronary artery; holding the shaft with backward force; and keeping the shaft tight, which allows the operator to keep the guiding catheter tip in the best position for superior backup support in crossing the balloon or the stent.

The child-in-mother system represents, as previously shown, a further method to improve backup force [24].

Technical options for uncrossable lesions

■ Venture microcatheter

Significant vessel tortuosity and artery angulations are predictors of procedural failure. The Venture™ catheter (Velocimed, MN, USA) is an OTW, low-profile support catheter that is 6 Fr compatible, flexible and torqueable, with a radiopaque atraumatic tip. This device has been designed to help the wire to find its way. Moreover, it provides strong support especially in occlusive lesions [25,26]. The 142-cm long OTW catheter is currently available and is compatible with all approved 0.014" guidewires. The distal tip of the Venture can be gradually bent more than 90° in a clockwise rotation using the thumb wheel on the external handle. Noncompressibility throughout all but the last few millimetres of the catheter limits flexion to only the catheter tip. Rotating the catheter tip in a circumferential plane is accomplished by turning the entire external handle. These two individual functions allow delicate control of the guidewires direction. It is possible to have further control by advancing and retracting the entire assembly within the vasculature.

■ Tornus crossing catheter

Even when a guidewire successfully crosses through the lesion, a tough CTO may block the balloon or the microcatheter. Although ablation with rotational atherectomy is effective for this sort of lesion [27,28] the guidewire should be exchanged with the Rota® wire (Boston Scientific, MA, USA), which is not possible when an OTW catheter does not cross the lesion.

The Tornus® (Asahi Intecc Co.) crossing microcatheter has been developed to penetrate the severe and hard lesions with greater flexibility and torquability [29]. Unlike the Rotablator® (Boston Scientific), it is not supposed to ablate; instead, it penetrates and dilates in a slightly larger channel [30]. The Tornus catheter consists of four parts: the tapered tip, the main shaft with surface coating, the polymer sleeve and the hub connector. The tip is blunt (1 mm) and mainly composed of platinum. The main shaft (135 cm length) is coreless with eight stainless wires, which are stranded in the coil and tapered 150 mm from the tip and has a right-handed lay (clockwise). The polymer sleeve prevents blood leakage. The hub connector may allow saline flushing, although this comes out at the end of the sleeve because the main shaft is coreless and has clearance gaps between each single wire. It is produced in two different sizes – the outside diameter is

2.1 Fr (0.71 mm; stainless steel wire diameter: 0.12 mm; screw pitch: 1.1 mm) or 2.6 Fr (0.88 mm; stainless steel wire diameter: 0.18 mm; screw pitch: 1.7 mm). The 2.6 Fr Tornus shows superior torque transmission and can be advanced more easily through a lesion to create a larger lumen. However, the 2.1 Fr Tornus is slightly better in following curved vessels, although its strength is weaker and it may reduce progression in hard calcified lesions. The Tornus design uses the stainless steel wires similar to screws against the vessel wall, with a manual counter-clockwise rotational burrowing movement. There are two advantages that make the devices very useful: it has a very strong driving force generated by counter-clockwise rotation against the vascular wall and it will not bend as it is made of stainless steel, unlike a polyamide balloon.

Anterograde devices for CTO revascularization

■ CROSSER system

The CROSSER® (FlowCardia, Inc., CA, USA) device represents an evolution of prior systems, which utilized vibrational energy to recanalize total occlusions [31,32].

Recanalization operated by the CROSSER works through two different active mechanisms:

- The mechanical impact: the tip of the CROSSER catheter mechanically vibrates against the CTO proximal cup. This high frequency, low amplitude longitudinal stroke pulverizes the CTO, creating a small channel through the CTO;
- The cavitation: the high-frequency vibration of the CROSSER produces vapor-filled microbubbles with the tip in the blood and saline. These microbubbles expand and implode, breaking the molecular bonds and eroding the solid surface of the CTO.

Generally, the approach is as follows: an Intermediate or a Balance Middle Weight™ (Abbott, CA, USA) guidewire is used to reach the occlusion site. The CROSSER is then advanced over the wire, as the catheter is a monorail catheter (FIGURE 5), until it reaches the fibrous occlusion cap. Then, the wire is redrawn in the CROSSER body and the device is then activated (FIGURE 6). To advance the catheter while it is activated, it is recommended that the operator uses gentle, forward pressure. When the catheter eventually crosses the occlusion and its position in the true lumen is confirmed with ipsilateral or contralateral injections, readvancement of the guidewire and removal of the CROSSER is performed.

According to all studies carried out, the device is well tolerated and very safe. No perforations have been described in any patient. This appears to be connected to the characteristics of the device. Indeed, when vibrating energy is applied, a certain amount of energy causes more deformation and a greater disintegrative effect on the less elastic atherosclerotic plaque, as it is opposed to the more elastic arterial wall.

Using this device, Grube *et al.* reported in an European CROSSER study 55 CTOs that comprised two clinical phases [33]: Phase I feasibility on device safety (30 CTOs; success rate: 47%), Phase II pivotal study (25 CTOs; success rate: 76%) using an improved version with a smaller tip (1.1 vs 1.3 mm) and a hydrophilic coating. Tiroch *et al.* reported on the US Flowcardia Approach to Chronic Total Occlusion Recanalization (FACTOR) trial, a prospective, nonrandomized trial, which was completed at 19 clinical centers in the USA and evaluated feasibility and safety of the CROSSER catheter (125 CTOs, success rate 61%) [34]. Out of 150 CTOs refractory to conventional guidewires attempts with a 14 CROSSER catheter (1.1 mm diameter tip), recanalization was successful in 92 CTOs (61%). The 30-day major adverse cardiac events (MACEs) were only 8.8%, mainly related to non-Q-wave myocardial infarction and elective repeat revascularization but no device-related perforation, abrupt closure, coronary artery spasm, side branch loss, distal embolization, no reflow, bradycardia and hypotension were observed. On 30 CTOs, Melzi *et al.* reported a 63% success rate with 7.1% 30-day MACEs [35].

In a recent study, the advantage of the CROSSER catheter as front-line strategy in complex CTO lesions, was assessed. Applying this

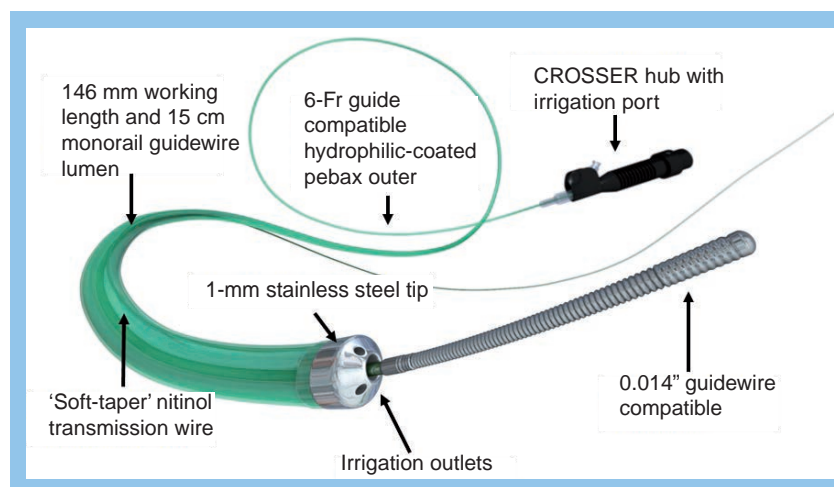


Figure 5. CROSSER catheter.

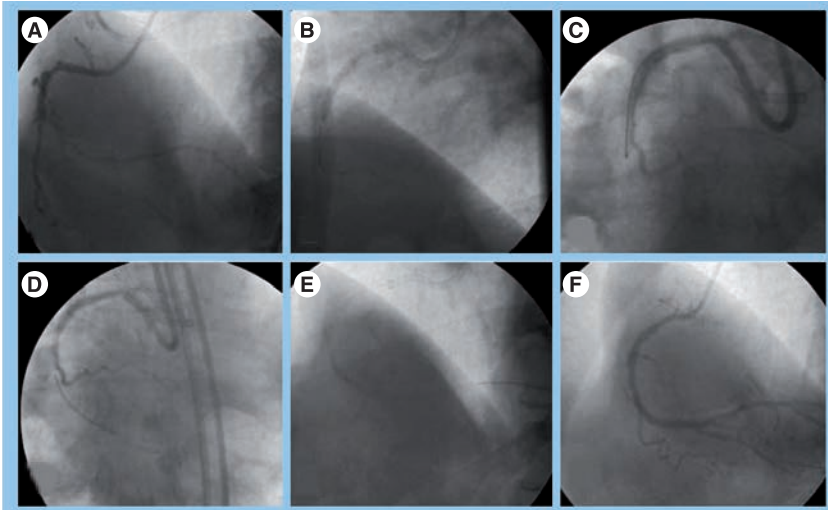


Figure 6. Anterograde CROSSER system for chronic total occlusion revascularization. (A) Chronic total occlusion (CTO) of the right coronary artery. (B) Implantation of drug-eluting stent (DES) proximal to the occlusion. (C) Setting of CROSSER system. (D) Successful CTO crossing by the CROSSER® system. (E) Dilatation with balloon. (F) Final result after DES implantation.

device in 46 consecutively complex CTO lesions a clinical success rate of 85% was obtained, without any incidences of coronary perforation and MACEs at 30-days of follow-up [36].

■ Safe-Cross radiofrequency total occlusion crossing system

The Safe-Cross® radiofrequency guidewire (Intraluminal Therapeutics Inc., CA, USA) combines the steerability of a conventional 0.014" intermediate guidewire, which can deliver radiofrequency energy for the CTO, with a new guidance system known as optical coherence reflectometry [37,38].

After initial favorable pilot experiences conducted in selected centers [29,30], the device's usefulness was tested in the Guided Radio Frequency Ablation of Total Occlusions (GREAT) Registry [39]. This included 116 CTOs refractory to 10-min attempts with conventional guidewires. Unfavorable anatomical features were frequently present. Recanalization success was obtained in 54% of the CTO attempts. The 30-day MACEs were observed in 6.7% of the patients predominantly related to non-Q-wave myocardial infarction and perforations without further complications. Although it was considered that this device could have been an interesting addition to the CTO armamentarium owing to its unique features, no further studies have been advanced during the last few years.

■ ExPander™ coronary guidewire

The ExPander™ 0.014" coronary guidewire (Ovalum Vascular, Israel; CE approved) combines

high-end guidewire characteristics with tip dilation capabilities specifically designed for coronary CTO recanalization. The guidewire has a patented microtip mechanism, which utilizes a wave-like motion to expand the microchannels of the occlusion within the lumen of the artery. The guidewire design and handling control provide the physician with tip control, steer ability and torqueability, which enables the safe advancement of the wire through the occlusion.

A preliminary study to evaluate the safety and efficacy of the ExPander guidewire for crossing CTOs in coronary arteries has been completed. The ExPander guidewire was found to be efficacious and safe for use in recanalization of chronically occluded coronary arteries in this initial experience [40,41].

■ Stingray CTO re-entry system

This device is designed to use subintimal guidewire placement and confidently place a wire in the distal true lumen. The system consists of the novel Stingray™ CTO orienting catheter and Stingray CTO re-entry guidewire (BridgePoint Medical, MN, USA) (FIGURE 7). In a failsafe fashion, the Stingray balloon catheter uses a proprietary mechanical trick to direct the Stingray guidewire towards the true lumen. The Stingray balloon catheters inflatable wings automatically align with the distal portion of the catheter along the dissection planes within the subintimal space. Using the Stingray catheter wings as radiographic beacons, the interventionalist can advance the Stingray guidewire out of either of the lateral ports within the Stingray catheter. The correct lateral port cannulation directs the Stingray guidewire on a course towards the true lumen and crosses successfully. The Stingray guidewire includes a 'hair-like' probe on its distal tip designed to catch and hold the guidewires tip against the intimal surface. Re-entry into the true lumen is carried out by advancing the Stingray guidewire until the operator gains tactile and radiographic re-entry evidence. The CTO revascularization is completed using conventional techniques such as balloon angioplasty and stenting. To date, the company has completed a 29-patient US pilot clinical trial achieving over 85% technical crossing success in this all-comers real world study. No data have been published yet.

■ Frontrunner catheter

The Frontrunner® catheter (Lu Mend Inc., Cordis Corp., J&J, FL, USA) was originally designed to open CTOs refractory for guidewires recanalization. This device is an intraluminal

blunt microdissector that takes advantage of the differential elasticity between intraluminal plaque and the adventitia. After initial favorable pilot experiences in patients with CTO or in-stent occlusions [42,43] who had failed the previous recanalization attempt with conventional guidewires, a multicenter registry was reported more than 6 years ago at the American College of Cardiology [44]. The authors demonstrated that in 107 patients who entered the trial after undergoing failing guidewire techniques, 60 patients (56.1%) were successfully recanalized. However, six patients (5.6%) had perforations and two (1.9%) patients required pericardiocentesis for impending cardiac tamponade. In another study by Orlic and colleagues, revascularization was attempted by Frontrunner in 50 consecutive patients who were very challenging or unsuitable for the conventional technique. This approach was successful in only 50% of the cases and the rate of coronary perforation was very high [45]. For these reasons, this device appears to be unavailable at the moment.

How to select the most appropriate treatment strategy: a case-oriented approach

Many factors are involved in the choice of the treatment strategy. Nevertheless, the operators should plan every step of the procedure and possible bail-out techniques that could be employed in case of failure.

First, the operator skill and the expertise should guide the selection of technique. Therefore, an inexperienced interventionalist could select the easiest approach, avoiding complex procedures. Second, a careful analysis of the angiograms is needed to select the appropriate technique. TABLE 2 reports angiographic criteria to guide the choice of revascularization technique. Finally, a patient's condition and comorbidities may be evaluated. In case of chronic kidney disease, the operator should choose an approach requiring less contrast agent administration, such as the use of anterograde devices.

Procedural complications & their management

Complications directly related to a CTO procedure might be summarized in coronary perforation or rupture, coronary ostium dissection, coronary thrombosis and device entrapment in a lesion. Among these complications, coronary perforation is associated with different adverse cardiac events such as myocardial infarction and cardiac tamponade. Although coronary

perforations account for 10% of the total referrals to emergent cardiac surgery, it is mainly managed in the catheterization laboratory with different approaches depending on the different conditions. First of all, perforation type needs to be recognized according to the Ellis classification [46]:

- Type I, perforation with extraluminal crater without extravasations;
- Type II, pericardial or myocardial blush without contrast jet extravasations;
- Type III, extravasations through frank (≥ 1 mm) perforation;
- Type IV (cavity spilling), perforation into anatomic cavity chamber, coronary sinus, etc.

In the case of type I perforations, the retrieval of the guidewire is sufficient to cope with the complication. In other cases, prolonged proximal balloon inflation (3–5 min) or stent implantation might help to solve the problem. However, careful observation for 15–30 min and frequently injecting contrast mean is highly recommended. If the extravasations enlarge, intravenous administration of protamine sulfate is advised in order to neutralize the anticoagulant effect. The dose in milligrams of protamine sulfate needs to be two-thirds of the heparin dose (in units) administered during the coronary intervention divided by 100. For example, a patient who is administered 8000–10,000 units of heparin must be given 50–65 mg of protamine sulfate. Following protamine administration the activated clotting time (ACT) is measured and, if it is more than 150 s, an additional 10 mg dose is given.

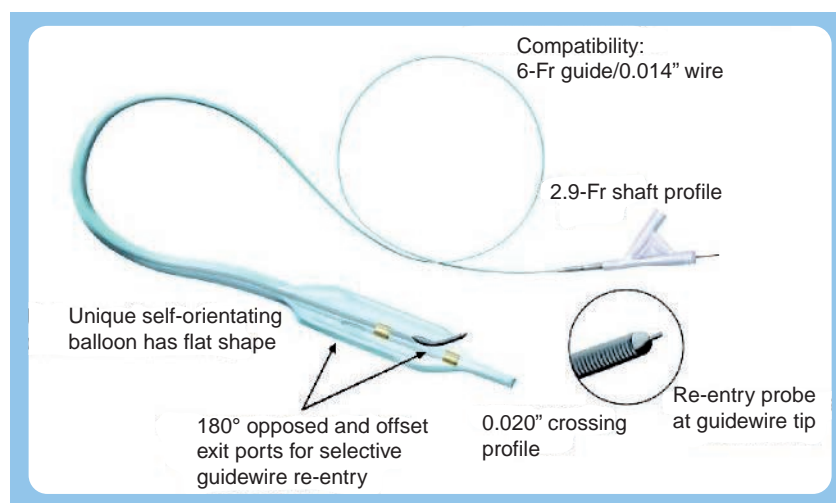


Figure 7. Stingray system.

Table 2. Angiographic criteria to guide the choice of revascularization technique.

Angiographic characteristic	Suggested approach
Presence of funnel stump at proximal CTO cap	Use of tapered hydrophilic guidewire; use microchannel technique
Presence of blunt stump at proximal CTO cap	Use of tapered/blunt stiff spring wire; use of anterograde devices
Presence of bridging collateral	Use of tapered/blunt stiff spring wire; use of anterograde devices
Presence of intraluminal microchannel	Use of soft hydrophilic guidewire
Presence of severe calcification	Use of tapered/blunt stiff spring wire; use of parallel wire
Long segment occlusion	Use of tapered/blunt stiff spring wire; use of anterograde devices
Presence of side branch at proximal cap	Use IVUS-guided technique; use open sesame technique
Presence of side branch into the body of occlusion	Use side-branch technique
Creation of large false lumen	Use IVUS-guided technique; use STAR technique (only in RCA or obtuse marginal artery CTO)
Severe tortuosity	Use of soft hydrophilic guidewire
Severe vessel angulation	Use Venture microcatheter
Total in-stent occlusion	Use CROSSER system
Poor backup support	Use anchor technique

CTO: Chronic total occlusion; IVUS: Intravascular ultrasound; RCA: Right coronary artery; STAR: Subintimal tracking and re-entry.

In type II perforations, the first actions taken are proximal balloon inflation and reversal of anticoagulation with protamine sulfate. Echocardiographic assessment should be performed without delay. Early diastolic right ventricular collapse and late diastolic right atria collapse are early signs of cardiac tamponade and precede hemodynamic instability. If these signs are present, urgent pericardiocentesis should be recommended. Action should be taken immediately after recognition of the perforation and before clinical symptoms develop. After stabilizing the patient's clinical status, placing a covered stent (in case of epicardial coronary rupture) or synthetic microsphere embolization (in case of distal perforation) might seal the perforation in the majority of the cases [47–49].

The onset of type III perforations is usually dramatic. An immediate aggressive treatment strategy is needed, including adequate volume resuscitation, administration of catecholamines and urgent pericardiocentesis. Proximal balloon inflation and heparin reversal is also needed immediately. Therefore, the use of a covered stent or synthetic microsphere might be considered. Placing a coronary perfusion catheter balloon might be indicated in preparation for emergent cardiac surgery, if after inflating the exploring of all possibilities, sealing of the perforation does not occur.

Type IV coronary perforations are not generally associated with MACE, and might be treated with the placement of covered stent and heparin reversal [47]. FIGURE 8 shows the algorithm of coronary perforation treatment on the basis of Ellis classification, adapted by Dippel *et al.* [50].

The requirement of high backup force in CTO PCI makes the guiding catheter choice very important. Several high backup guiding catheters, such as amplatz catheters, could damage the coronary ostium, causing flow-limiting tubular dissection. Indeed, maladroit guiding catheter manipulation or its deep intubation might also cause ostium dissection. This happens most often in the right coronary artery when there is proximal vessel disease. In these circumstances, it is recommended to stabilize the ostium and the proximal part of the vessel with stent implantation prior to CTO PCI. Particular attention should be given to donor vessel engagement when using the retrograde approach. Indeed, dissection in the donor vessel might cause severe periprocedural events.

The use of complex techniques such as the retrograde approach and the use of multiple guidewires and devices might add to the risk of coronary thrombosis. Therefore, after the administration of an initial bolus of 80–100 units/kg it is recommended to check the ACT every 30 min, maintaining the ACT at greater than 300 s. Indeed, careful observation of angiograms might help to recognize the early signs of coronary thrombosis. If thrombus is presented, it is sensible to abort the procedure, take away the double coronary cannulation and treat the complication with the use of an aspiration device and glycoprotein IIb/IIIa inhibitors administration.

The entrapment of a guidewire or a device such as a microcatheter or a standard balloon might occur after CTO wire crossing, especially in highly calcified and tortuous vessels. Different types of wires (polymeric or stiff) or several

devices such as the Tornus catheter might occasionally get stuck in the vessel in severe calcified lesions. With regard to guidewires, such an event can be approached with the digging out technique using the penetration of a stiff wire. This consists of using a stiff wire, which penetrates into the CTO looking for a new dissection plane, breaking the calcium load, which blocks the first guidewire (polymeric or stiff) or device.

An alternative possibility, depending on whether guidewire entrapment occurs in the proximal part of the coronary artery and whether it is a stiff wire, is to perform the balloon-trapping technique. Finally, in some cases, guidewire breakage might occur and withdrawal may be performed by the use of a loop snare retrieval system.

When to stop the procedure & how to set a second attempt

Once it has been decided to proceed with a CTO anterograde revascularization attempt, it is important to stabilize an end stage, in which

the operator is supposed to stop the procedure and try different alternatives. Failing to cross the lesion may lead to the wire going offline into a large false lumen. In this case, although there are some techniques or devices that can be used, stopping the procedure and scheduling a second attempt might be a reasonable strategy. For example, a retrograde approach after a failed anterograde approach should be considered in case of the presence of suitable collateral circulation. This second attempt should be rescheduled 6–8 weeks after the first procedure. When the patient returns, the dissection plane will be healed and a better anterograde flow can be observed, leading to greater success with the second attempt. It is rare to plan a CTO recanalization for the second attempt with the retrograde approach and to observe the artery almost spontaneously recanalized with a clear microchannel visualization. In these cases, the decision to retry with the anterograde approach using a soft hydrophilic tapered guidewire might help to obtain a quick procedural success.

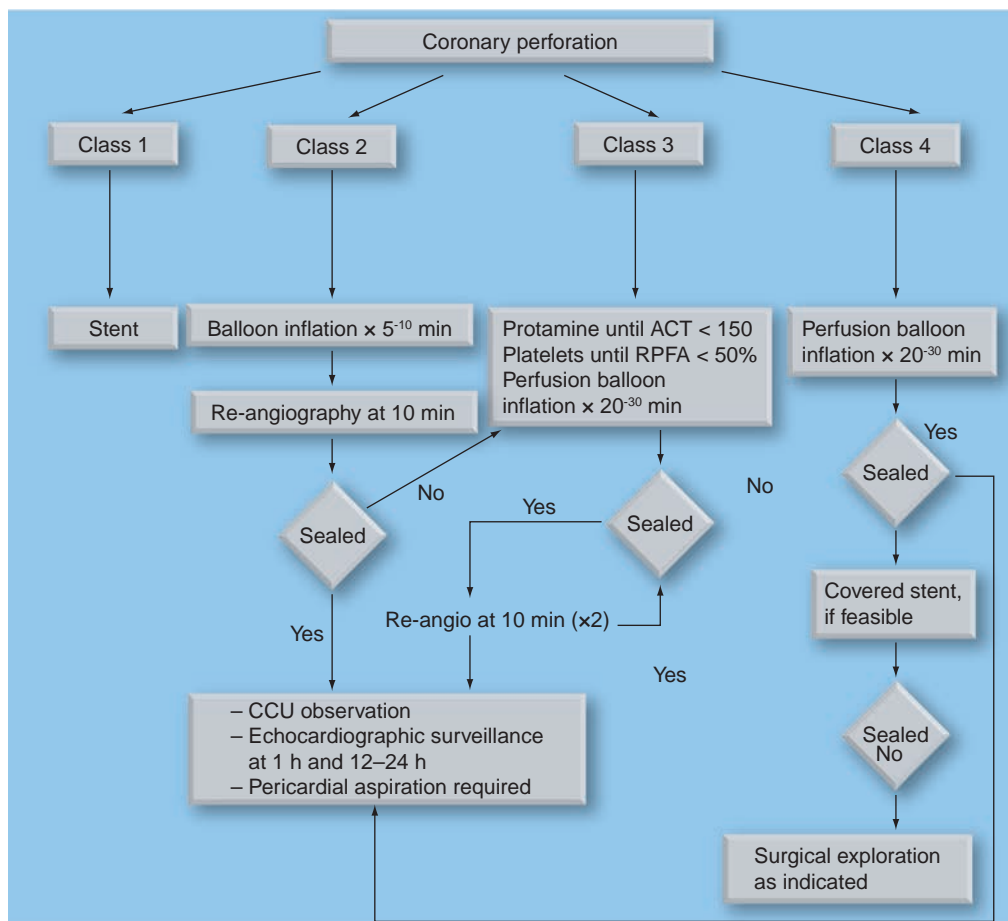


Figure 8. Algorithm of coronary perforation management.
 ACT: Activated clotting time; CCU: Critical care unit; RPFA: Rapid platelet function assay.
 Adapted from [50].

Conclusion & future perspective

At present, CTO lesions represent the last frontier for interventional cardiologists; in fact, their treatment requires skilled and experienced operators.

The complete knowledge of antegrade techniques is the key strategy to increasing procedural success rates. Therefore, the operators might choose the most appropriate PCI technique in relation to the lesion characteristics, being able to switch during the procedure from one technique to another in case of technical failure.

The development of new dedicated devices and the continuous technical improvement in

this field hold promise for a higher increase in recanalization rate of this lesions subset during the following years.

Financial & competing interests disclosure

The authors have no relevant affiliations or financial involvement with any organization or entity with a financial interest in or financial conflict with the subject matter or materials discussed in the manuscript. This includes employment, consultancies, honoraria, stock ownership or options, expert testimony, grants or patents received or pending, or royalties.

No writing assistance was utilized in the production of this manuscript.

Executive summary

Epidemiology

- Approximately 30–40% of patients with coronary artery disease are shown at angiography to have at least one occluded artery, but only 7–15% of chronic total occlusions (CTOs) are treated percutaneously. Therefore, the majority of patients affected by CTO are managed by medical therapy or referred to coronary artery bypass surgery. This fact might be explained with the low rate of angiographic success obtained for these lesions in comparison with nonoccluded lesions.

Rationale for chronic total occlusion revascularization

- Successful recanalization of a CTO can reduce anginal symptoms, improve quality of life, reduce the need for coronary artery bypass surgery and increase long-term survival.

Strategies to improve procedural success

- The operators must choose the most appropriate percutaneous coronary intervention (PCI) technique in relation to the lesion characteristics, their experience and patient characteristics.
- The antegrade approach is the technique of choice in the vast majority of PCI CTOs, but it requires a great understanding of the different guidewires and dedicated materials.
- The parallel wire technique is frequently employed with a high success rate in the majority of the cases.
- In case of large dissection creation, the subintimal tracking and re-entry technique might be used with success as a bail-out technique.
- The anchor balloon technique might be used in case of poor guiding catheter backup in order to improve support.
- Intravascular ultrasound might be used in CTO PCI for the identification of re-entry from subintimal space or identification of the entry site in a blunt CTO.
- Many dedicated devices might be used for CTO PCI by the antegrade approach.
- The development of new dedicated devices and continuous technical improvements gives hope for a higher increase in recanalization rate of this lesion subset during the following years.

Procedural complications & their management

- The most common procedural complications directly related to a CTO PCI might be summarized as: coronary perforation or rupture, coronary ostium dissection, coronary thrombosis and device entrapment in a lesion.
- The use of stiff spring guidewires in these procedures increases the risk of coronary perforation. To appropriately manage these events, the operator should first recognize the type of perforation by following the Ellis classification.

Future perspective

- The development of new dedicated devices and the continuous technical improvement in this field holds promise for a higher increase in recanalization rate of this lesion subset in the coming years.

Bibliography

Papers of special note have been highlighted as:

▪ of interest

▪▪ of considerable interest

- 1 Suero JA, Marso SP, Jones PG *et al.*: Procedural outcomes and long-term survival among patients undergoing percutaneous coronary intervention of a chronic total occlusion in native coronary arteries: a 20-years experience. *J. Am. Coll. Cardiol.* 38, 409–414 (2001).
 - Represents the biggest retrospective study, which has demonstrated the clinical benefit

of chronic total occlusion (CTO) percutaneous coronary intervention.

- 2 Noguchi T, Miyazaki S, Morii I, Daikoku S, Goto Y, Nonogi H: Percutaneous transluminal coronary angioplasty of chronic total occlusions. Determinants of primary success and long-term clinical outcome. *Catheter Cardiovasc. Interv.* 49, 258–264 (2000).
- 3 Hoye A, van Domburg RT, Sonnenschein K, Serruys PW: Percutaneous coronary intervention for chronic total occlusions: the Thoraxcenter experience 1992–2002. *Eur. Heart J.* 26, 2630–2636 (2005).
- 4 Kahn JK: Angiographic suitability for catheter revascularization of total coronary occlusions in patients from a community hospital setting. *Am. Heart J.* 126, 561–564 (1993).
- 5 Christofferson RD, Lehmann KG, Martin GV, Every N, Caldwell JH, Kapadia SR: Effect of chronic total coronary occlusion on treatment strategy. *Am. J. Cardiol.* 95, 1088–1091 (2005).
 - Underlines the high incidence of CTO in patients with coronary artery disease.

- 6 Stone GW, Rutherford BD, Mc Conahay DR *et al.*: Procedure outcome of angioplasty for total coronary occlusion: an analysis of 971 lesions in 905 patients. *J. Am. Coll. Cardiol.* 15, 849–856 (1990).
- 7 Ivanhoe RJ, Weintraub WS, Douglas JS Jr *et al.*: Percutaneous transluminal coronary angioplasty of chronic total occlusion. Primary success, restenosis, and long term clinical follow up. *Circulation* 85, 106–115 (1992).
- 8 Colombo A, Mikwall GW, Michev I *et al.*: Treating chronic total occlusions using suboptimal tracking and reentry: the STAR technique. *Catheter Cardiovasc. Interv.* 64, 407–411 (2005).
- 9 Carlino M, Latib A, Godino C, Cosgrave J, Colombo A: CTO recanalisation by intraocclusion injection of contrast: the micro channel technique. *Catheter Cardiovasc. Interv.* 71, 20–26 (2008).
- 10 Mitsudo K, Yamashita T, Asakura Y *et al.*: Recanalisation strategy for chronic total occlusions with tapered and stiff-tip guidewire. The results of CTO New Technique for Standard Procedure (CONQUEST) trial. *J. Invas. Cardiol.* 20, 571–577 (2008).
- 11 Saito S, Tanaka S, Hiroe Y *et al.*: Angioplasty for chronic total occlusion by using tapered-tip guidewires. *Catheter Cardiovasc. Interv.* 59(3), 305–311 (2003).
- **Reports the use of a dedicated wire for CTO percutaneous coronary intervention.**
- 12 Matsukage T, Yoshimachi F, Masutani M *et al.*: A new 0.010-inch guidewire and compatible balloon catheter system: the IKATEN registry. IKATEN Registry Investigators. *Catheter Cardiovasc. Interv.* 73(5), 605–610 (2009).
- 13 Di Mario C, Werner S, Sianos G *et al.*: European perspective in the recanalisation of Chronic Total Occlusion (CTO): consensus document from the EuroCTO club. *EuroIntervention* 3, 30–43 (2007).
- ■ **Consensus document by an expert European operator.**
- 14 Saito S: Open sesame technique for chronic total occlusion. *Catheter Cardiovasc. Interv.* 75(5), 690–694 (2010).
- 15 Bolia A, Brennan J, Bell PR: Recanalization of femoro-popliteal occlusions: improving success rate by suboptimal recanalisation. *Clin. Radiol.* 40, 325 (1989).
- 16 Bolia A: Percutaneous intentional extraluminal (sub-intimal) recanalisation of crural arteries. *Eur. J. Radiol.* 28, 199–204 (1998).
- 17 Spinosa DJ, Leung DA, Mastumoto AH *et al.*: Percutaneous intentional extraluminal recanalisation in patients with chronic critical limb ischemia. *Radiology* 232, 499–507 (2005).
- 18 Strauss BH, Segev A, Wright GA *et al.*: Microvessels in chronic total occlusions: pathways for successful guidewire crossing? *J. Interv. Cardiol.* 18, 425–436 (2005).
- 19 Carlino M, Godino C, Latib A, Moses JW, Colombo A: Subintimal tracking and re-entry technique with contrast guidance: a safer approach. *Catheter Cardiovasc. Interv.* 72, 790–796 (2008).
- 20 Hausmann D, Erbel R, Alibelli-Chemarin MJ *et al.*: The safety of intracoronary ultrasound. A multicenter survey of 2207 examinations. *Circulation* 91, 623–630 (1995).
- 21 Schryver TE, Popma JJ, Kent KM, Leon MB, Eldredge S, Mintz GS: Use of intracoronary ultrasound to identify the 'true' coronary lumen in chronic coronary dissection treated with intracoronary stenting. *Am. J. Cardiol.* 69, 1107–1108 (1992).
- 22 Fujita S, Tamai H, Kyo E *et al.*: New technique for superior guiding catheter support during advancement of a balloon in coronary angioplasty: the anchor technique. *Catheter Cardiovasc. Interv.* 59, 482–488 (2003).
- 23 Hirokami M, Saito S, Muto H: Anchoring technique to improve guiding catheter support in coronary angioplasty of chronic total occlusions. *Catheter Cardiovasc. Interv.* 67(3), 366–371 (2006).
- 24 Takahashi S, Saito S, Tanaka S *et al.*: New method to increase a backup support of a 6 French guiding coronary catheter. *Catheter Cardiovasc. Interv.* 63(4), 452–456 (2004).
- 25 McClure SJ, Wahr DW, Webb JG: Venture wire control catheter. *Catheter Cardiovasc. Interv.* 66, 346–350 (2005).
- 26 Routledge H, Lefevre T, Ohanessian A, Louvard Y, Dumas P, Morice MC: Use of deflectable tip catheter to facilitate complex interventions beyond insertion of coronary bypass grafts: three cases reports. *Catheter Cardiovasc. Interv.* 70, 862–866 (2007).
- 27 Henneke KH, Regar E, Konig A *et al.*: Impact of target lesion calcification on coronary stent expansion after rotational atherectomy. *Am. Heart J.* 137, 93–99 (1999).
- 28 Grunberg L, Mehran R, Dangas G *et al.*: Effect of plaque debulking and stenting on short and long-term outcomes after revascularisation of chronic total occlusions. *J. Am. Coll. Cardiol.* 35, 151–156 (2000).
- 29 Tsuchikane E, Kato O, Shimogani M *et al.*: First clinical experience of a novel penetration catheter for patients with severe coronary artery stenosis. *Catheter Cardiovasc. Interv.* 65, 368–373 (2005).
- 30 Reifart N, Enayat D, Giokoglu K: A novel penetration catheter (Tornus) as bail-out device after balloon failure to recanalise long, old calcified chronic occlusions. *EuroIntervention* 3, 1–5 (2008).
- 31 Rees MR, Michalis LK: Vibrational angioplasty in chronic total occlusions. *Lancet* 342, 999–1000 (1993).
- 32 Michalis LK, Rees MR, Davis JA *et al.*: Use of vibrational angioplasty for the treatment of chronic total occlusions: preliminary results. *Catheter Cardiovasc. Interv.* 46, 98–104 (1999).
- 33 Grube E, SutschG, Lim VY *et al.*: High-frequency mechanical vibration to recanalize chronic total occlusions after failure to cross with conventional guidewires. *J. Invasive Cardiol.* 18, 85–91 (2006).
- 34 Tiroch K, Cannon L, Reisman M *et al.*: High-frequency vibration for the recanalisation of guidewire refractory chronic total coronary occlusions US FACTOR. *Catheter Cardiovasc. Interv.* 72, 771–780 (2008).
- 35 Melzi G, Cosgrave J, Biondi Zoccai G *et al.*: A novel approach to chronic total occlusions: the crosser system. *Catheter Cardiovasc. Interv.* 68, 29–35 (2006).
- 36 Galassi AR, Tomasello SD, Costanzo L, Campisano MB, Calvo F, Tamburino C: Recanalization of complex coronary chronic total occlusions using high frequency vibrational energy as first-line therapy: a single center experience. *J. Interv. Cardiol.* 23, 130–138 (2010).
- 37 Yamashita T, Kasaoka S, Son R *et al.*: Optical coherent reflectometry: a new technique to guide invasive procedures. *Catheter Cardiovasc. Interv.* 54, 257–263 (2001).
- 38 Cordero H, Wanburton KD, Underwood PL, Heuser RR: Initial experience and safety in the treatment of chronic total occlusions with fibroptic guidance technology: optical coherence reflectometry. *Catheter Cardiovasc. Interv.* 54, 180–187 (2001).
- 39 Baim DS, Braden G, Heuser R *et al.*: Utility of the safe-cross-guided radiofrequency radiofrequency total occlusion crossing system in chronic coronary total occlusions (results from the Guided Radio Frequency Ablation of Total Occlusions Registry Study, GREAT). *Am. J. Cardiol.* 94, 853–858 (2004).
- 40 Scheinowitz M, Amrami I, Oppenheim U *et al.*: Crossing chronic total occlusions with a new 0.014" CiTop guidewire: proof of concept. *Catheter Cardiovasc. Interv.* 74, 278–285 (2009).
- 41 Beyar R, Lotan C: Innovations in Cardiovascular Interventions 2008 – Technology Parade. *EuroIntervention* 4, 676–684 (2009).
- 42 Whitbourn RJ, Cincotta M, Mossop P, Selmon M: Intraluminal blunt microdissection for angioplasty of coronary chronic total occlusions. *Catheter Cardiovasc. Interv.* 58, 194–196 (2003).

- 43 Yang YM, Mehran R, Dangas G *et al.*: Successful use of the Frontrunner catheter in the treatment of in-stent coronary chronic total occlusions. *Catheter Cardiovasc. Interv.* 63, 462–468 (2004).
- 44 Whitlow PL, Selmon M, O’Neill W *et al.*: Treatment of uncrossable chronic total coronary occlusions with the Frontrunner; multicenter experience. *J. Am. Coll. Cardiol.* 39(Suppl. 1), 29 (2002).
- 45 Orlic D, Stankovic G, Sangiorgi G *et al.*: Preliminary experience with the Frontrunner coronary catheter: novel device dedicated to mechanical revascularization of chronic total occlusions. *Catheter Cardiovasc. Interv.* 64, 146–152 (2005).
- 46 Ellis SG, Ajluni S, Arnold AZ *et al.*: Increased coronary perforation in the new device era. Incidence, classification management and outcome. *J. Am. Coll. Cardiol.* 90, 409–414 (1994).
- ■ **Important paper to the knowledge of coronary perforation.**
- 47 Javaid A, Buch AN, Satler LF *et al.*: Management and outcomes of coronary artery perforation during percutaneous coronary intervention. *Am. J. Cardiol.* 98, 911–914 (2006).
- 48 Fejka M, Dixon SR, Safian RD *et al.* : Diagnosis, management, and clinical outcome of cardiac tamponade complicating percutaneous coronary intervention. *Am. J. Cardiol.* 90, 1183–1186 (2002).
- 49 Fasseas P, Orford JL, Panetta CJ *et al.*: Incidence, correlates, management, and clinical outcome of coronary perforation: analysis of 16298 procedures. *Am. Heart J.* 147, 140–145 (2004).
- 50 Dippel EJ, Kereiakes DJ, Tramuta DA *et al.*: Coronary perforation during percutaneous coronary intervention in the era of abciximab platelet Glycoprotein IIb/IIIa blockade: an algorithm for percutaneous management. *Catheter Cardiovasc. Interv.* 52, 279–283 (2001).
- **Provides a systematic algorithm for the treatment of coronary perforation.**